



Use of automatic refractometer infrared images to screen pigment dispersion syndrome: A cross-sectional observational study from a preliminary hypothesis

Paolo Brusini¹ and Veronica Papa¹

¹ Policlinico Citta di Udine Health Center, Viale Venezia, Udine, Italy

ABSTRACT

Background: This study was performed to evaluate the use of anterior segment images, obtained with an automatic refractometer, to identify early defects of the iris pigment epithelium in patients with pigment dispersion syndrome (PDS) or pigmentary glaucoma (PG) without observable alterations at the slit lamp.

Methods: In this cross-sectional observational study, carried out from January 2018 to December 2019, in Policlinico Citta di Udine Health Center, Udine, Italy, we observed anterior segment infrared images of 1700 subjects who were undergoing routine ophthalmological examination using an automatic refractometer. We selected infrared images of subjects who fulfilled the inclusion and exclusion criteria and looked for a focal defect in the iris pigment epithelium.

Results: Twenty patients with focal iris pigment epithelial defect were identified and none of them showed evident signs of PDS. After the necessary explanations, they agreed to have further examinations to verify the possibility of PDS. An in-depth evaluation of ocular structures, including gonioscopy, demonstrated the presence of PDS in all subjects with iris defects.

Conclusions: The use of infrared images obtained by an automatic refractometer could provide early and easy identification of PDS in crowded ophthalmology clinics or mass screening programs; yet, more well-designed studies are necessary to confirm these preliminary findings and prove this proposed screening tool.

KEY WORDS

pigment-dispersion syndrome, glaucoma, pigmentary glaucoma, automatic refractometer, screening

INTRODUCTION

Pigment dispersion syndrome (PDS) is a relatively uncommon entity that can precipitate secondary open-angle glaucoma, so-called pigmentary glaucoma (PG) [1, 2]. Both conditions are characterized by excessive pigment dispersion throughout the anterior segment of the eye with heavy trabecular meshwork pigmentation, iris trans-illumination defects, and pigment deposition on the corneal endothelium called the Krukenberg spindle [3, 4]. Patients with PG may develop optic nerve damage with or without visual field defects, due to the increase in intraocular pressure (IOP). An increase in IOP is caused by pigment dispersion in the anterior chamber, particularly in the trabecular meshwork, which reduces aqueous outflow [5, 6]. This type of glaucoma is most prevalent in males in the third to fourth decade of life. Other risk factors include myopia, race (African),

Correspondence: Paolo Brusini, Department of Ophthalmology, Policlinico Citta di Udine Health Center, Viale Venezia 410, Udine, Italy.

E-mail: brusini@libero.it ORCID iD: <https://orcid.org/0000-0003-0855-5775>

How to cite this article: Brusini P, Papa V. Use of automatic refractometer infrared images to screen pigment dispersion syndrome: A cross-sectional observational study from a preliminary hypothesis. *Med Hypothesis Discov Innov Optom.* 2020 Summer; 1(1): 25-28. DOI: <https://doi.org/10.51329/mehdiptometry104>

Received: 03 August 2020; Accepted: 30 August 2020



Copyright © Author(s). This is an open-access article distributed under the terms of the Creative Commons Attribution-NonCommercial 4.0 International License (<http://creativecommons.org/licenses/by-nc/4.0/>) which permits copy and redistribute the material just in noncommercial usages, provided the original work is properly cited.



flat cornea, and family history [7]. Most patients with PG or PDS are asymptomatic. However, headaches and episodes of blurred vision can occur, particularly after physical exercise, but these symptoms are usually ignored by patients [8, 9]. Moreover, IOP in PG tends to be higher with wide fluctuations compared to primary open-angle glaucoma. For these reasons, it is crucial to identify PDS or PG at earlier stages [10-12].

This study aimed to evaluate the use of anterior segment images, obtained using an automatic refractometer, to identify early defects of the iris pigment epithelium in patients with pigment PDS or PG without observable signs on slit-lamp examination.

METHODS

We conducted this prospective cross-sectional observational study from January 2018 to December 2019 at the Policlinico Citta di Udine Health Center, Udine, Italy in compliance with the principles of the Declaration of Helsinki. We used the observational method of data collection. Verbal consent was obtained from all participants. Anterior segment infrared images of 1700 healthy subjects who attended our ophthalmology clinic for the first routine eye examination during the study period were included. This was a part of our standard and routine ophthalmological examination for clinic-referred subjects. Subsequently, we further evaluated those with focal defects of the iris pigment epithelium identified with infrared images using an automatic refractometer Nidek AR-1a (Nidek CO, LTD, Gamagori Aiki, Japan).

Inclusion criteria included subjects visiting our ophthalmic clinic for their first routine eye examination and those with ocular hypertension or primary open-angle glaucoma who were undergoing follow-up for periodic monitoring. We excluded patients with previous intraocular surgery or iris defects secondary to trauma or other ocular diseases. None of the included patients had evident signs of PDS. We described the findings observed in the infrared images.

RESULTS

Twenty out of 1700 healthy subjects attended our ophthalmology clinic for their first routine eye examination during the study period. The infrared images clearly showed focal defects of the iris pigment epithelium with various ranges of severity (Figure 1).

Furthermore, an in-depth evaluation of ocular structures, including gonioscopy, demonstrated the presence of a PDS in all 20 subjects. Some of them had a barely visible Krukenberg spindle or very minimal iris defects highlighted by slit-lamp transillumination by dimming the light in the room, which was not noted in the early slit-lamp assessment. However, most showed only hyperpigmentation of the trabecular meshwork identified with gonioscopy.

In two of our previous patients with a previous diagnosis of PG who were undergoing follow-up in this clinic, the infrared images were unremarkable; however, a subsequent detailed examination made it possible to diagnose primary open-angle glaucoma. In addition, to further investigate the suitability of this proposed screening method, we observed anterior segment infrared images of all our patients with known PG or PDS who visited our glaucoma center (64 eyes) following verbal consent. In all cases, the infrared images showed evident defects of the iris pigment epithelium, sometimes resembling classic spoke-like iris transillumination defect in PDS.

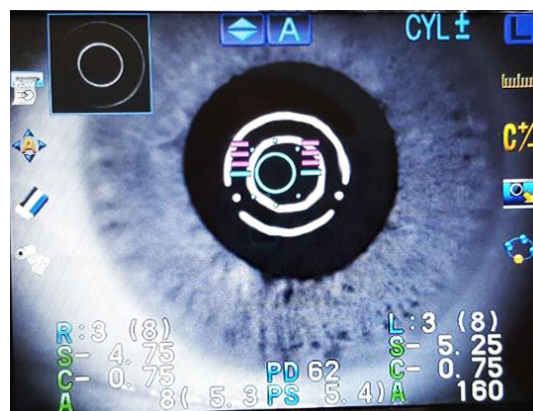


Figure 1. An infrared image using an automatic refractometer in a 48-year-old man who had come to our center for a routine ophthalmological examination revealed mild iris pigment epithelium defects dispersed in the inferior quadrant, evident as tiny, pinpoint, and multiple black points.

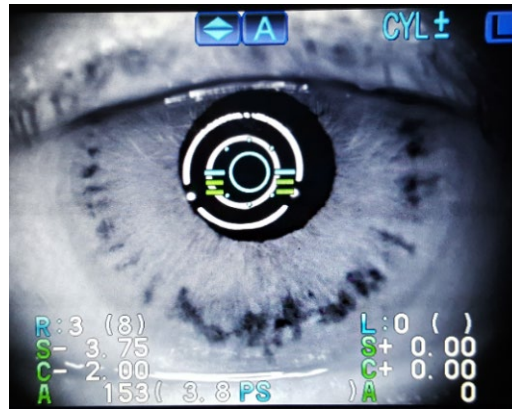


Figure 2. An infrared image using an automatic refractometer in a 37-year-old man who was under follow-up in our center for pigmentary glaucoma revealed obvious iris pigment epithelium defects in the peripheral portion of the iris resembling classic spoke-like iris transillumination defects in pigment dispersion syndrome.

For example, as shown in Figure 2 in a case with PG, obvious iris pigment epithelium defects are observed in the peripheral portion of the iris resembling classic spoke-like iris transillumination defects seen in PDS. Nevertheless, the defects in the infrared images of patients with known PG or PDS had more severe patterns compared to defects observed in the 20 subjects with an unrecognized disease.

DISCUSSION

In the present study, the infrared iris transillumination technique was used to help diagnose PG or PDS earlier in patients referred to our ophthalmology clinic as the preliminary hypothesis. Our proposed method uses infrared images taken by an automatic refractometer. In addition, we observed anterior segment infrared images of all patients with known PG or PDS who were undergoing follow-up in our clinic before. Interestingly, in previously diagnosed patients with PG or PDS, defects of the iris pigment epithelium were more severe than those observed in patients with an unrecognized disease.

The use of the infrared iris transillumination technique to help diagnose PG or PDS has already been proposed and discussed in the literature [13, 14]. There was a significant correlation between iris transillumination percentage and PG severity [14]. Some techniques used in these studies were infrared iris transillumination videography and computerized image analysis [14], infrared-sensitive video camera [13], and specially designed cameras applied independently or connected to the slit-lamp device to capture anterior segment photos [13, 15-19] for imaging and evaluation of iris transillumination. Therefore, the idea of using infrared iris transillumination in the diagnosis of PG or PDS has been proposed. In the present study, we also used the infrared iris transillumination method to identify PG or PDS earlier in patients who attended our clinic for a routine eye examination. Notwithstanding, the novelty of our proposed method is the use of infrared images taken by an automatic refractometer, which is usually available in most eye clinics. Therefore, using this method for diagnosing PG or PDS (if missed by clinicians may have irreversible visual morbidities) is a new idea that we proposed here. However, further standardization and institutionalization of this proposed diagnostic method requires carefully designed studies, necessary statistical analyses, and long-term clinical follow-up to infer a viable and applicable guideline for its use as an ancillary technique in diagnosing PG or PDS in earlier stages.

Nevertheless, our proposed method has some limitations. Subtle iris pigment defects could be missed using this technique, if the operator does not carefully check the images, one could not rely solely on this method for detecting PDS or PG. In some cases, iris defects could be congenital or secondary to previous trauma or intraocular surgery and not to a PDS, and this necessitates careful and meticulous history taking before proceeding for examination. In this study, we excluded patients with previous intraocular surgery or iris defects secondary to trauma or other ocular diseases in order to minimize this effect, even though we could not eliminate it. It is very complex to record images from the refractometer, even if someone could use a smartphone for this purpose. The lack of a detailed analysis and statistical comparison of findings with confirmed PDS or PG cases is one of the main limitations of our study method. The lack of long-term follow-up to evaluate the accuracy of this proposed method in diagnosing suspected PDS or PG subjects is another major limitation. On the other hand, the proposed method is an inexpensive and fast tool. Multicentric comparative studies with a larger sample size and a longer follow-up period could be useful to confirm our hypothesis and the validity and reliability of the proposed screening method.

CONCLUSIONS

We propose a fast and easy way to screen patients, just by observing infrared images obtained by a standard automatic refractometer as an ancillary technique, allowing for earlier diagnosis of PDS or PG, and ensuring timely detection of these patients. However, more well-designed studies are necessary to confirm these preliminary findings. Certainly, this study is just a presentation of this proposed screening tool, and the evaluation of its usefulness, validity, and reliability may require more detailed investigation.

ETHICAL DECLARATIONS

Ethical approval: This study was an observational study based on routine ophthalmology examinations. The authors declare that they obtained verbal consent prior to routine ophthalmology examination of the study subjects who visited Policlinico Citta di Udine Health Center, Udine, Italy. Study conducted in compliance with the principles of the Declaration of Helsinki.

Conflict of interest: None.

FUNDING

None.

ACKNOWLEDGMENT

None.

REFERENCES

- Gomez Goyeneche HF, Hernandez-Mendieta DP, Rodriguez DA, Sepulveda AI, Toledo JD. Pigment Dispersion Syndrome Progression to Pigmentary Glaucoma in a Latin American Population. *J Curr Glaucoma Pract.* 2015 Sep-Dec;9(3):69-72. doi: 10.5005/jp-journals-10008-1187 pmid: 26997839
- Yang JW, Sakiyalak D, Krupin T. Pigmentary glaucoma. *J Glaucoma.* 2001;10(S Suppl 1):S30-2. doi: 10.1097/00061198-200110001-00012 pmid: 11890269
- Lascaratos G, Shah A, Garway-Heath DF. The genetics of pigment dispersion syndrome and pigmentary glaucoma. *Surv Ophthalmol.* 2013;58(2):164-75. doi: 10.1016/j.survophthal.2012.08.002 pmid: 23218808
- Gottanka J, Johnson DH, Grehn F, Lutjen-Drecoll E. Histologic findings in pigment dispersion syndrome and pigmentary glaucoma. *J Glaucoma.* 2006;15(2):142-51. doi: 10.1097/00061198-200604000-00011 pmid: 16633228
- Musch DC, Shimizu T, Niziol LM, Gillespie BW, Cashwell LF, Lichter PR. Clinical characteristics of newly diagnosed primary, pigmentary and pseudoexfoliative open-angle glaucoma in the Collaborative Initial Glaucoma Treatment Study. *Br J Ophthalmol.* 2012;96(9):1180-4. doi: 10.1136/bjophthalmol-2012-301820 pmid: 22773091
- Sowka J. Pigment dispersion syndrome and pigmentary glaucoma. *Optometry.* 2004;75(2):115-22. doi: 10.1016/s1529-1839(04)70023-8 pmid: 14989503
- Niyadurupola N, Broadway DC. Pigment dispersion syndrome and pigmentary glaucoma--a major review. *Clin Exp Ophthalmol.* 2008;36(9):868-82. doi: 10.1111/j.1442-9071.2009.01920.x pmid: 19278484
- Okafor K, Vinod K, Gedde SJ. Update on pigment dispersion syndrome and pigmentary glaucoma. *Curr Opin Ophthalmol.* 2017;28(2):154-60. doi: 10.1097/ICU.0000000000000352 pmid: 27898469
- Scuderi G, Contestabile MT, Scuderi L, Librando A, Fenicia V, Rahimi S. Pigment dispersion syndrome and pigmentary glaucoma: a review and update. *Int Ophthalmol.* 2019;39(7):1651-62. doi: 10.1007/s10792-018-0938-7 pmid: 29721842
- Tandon A, Zhang Z, Fingert JH, Kwon YH, Wang K, Alward WLM. The Heritability of Pigment Dispersion Syndrome and Pigmentary Glaucoma. *Am J Ophthalmol.* 2019;202:55-61. doi: 10.1016/j.ajo.2019.02.017 pmid: 30796891
- Lahola-Chomiak AA, Footz T, Nguyen-Phuoc K, Neil GJ, Fan B, Allen KF, et al. Non-Synonymous variants in premelanosome protein (PMEI) cause ocular pigment dispersion and pigmentary glaucoma. *Hum Mol Genet.* 2019;28(8):1298-1311. doi: 10.1093/hmg/ddy429 pmid: 30561643
- Huchzermeyer C, Reulbach U, Horn F, Lämmer R, Mardin CY, Jünemann AG. Longitudinal stability of the diurnal rhythm of intraocular pressure in subjects with healthy eyes, ocular hypertension and pigment dispersion syndrome. *BMC Ophthalmol.* 2014;14:122. doi: 10.1186/1471-2415-14-122 pmid: 25316067
- Alward WL, Munden PM, Verdick RE, Perell HR, Thompson HS. Use of infrared videography to detect and record iris transillumination defects. *Arch Ophthalmol.* 1990;108(5):748-50. doi: 10.1001/archophth.1990.01070070134052 pmid: 2334336
- Haynes WL, Alward WL, McKinney JK, Munden PM, Verdick R. Quantitation of iris transillumination defects in eyes of patients with pigmentary glaucoma. *J Glaucoma.* 1994;3(2):106-13. pmid: 19920562
- Roberts DK, Lukic A, Yang Y, Wilensky JT, Wernick MN. Multispectral diagnostic imaging of the iris in pigment dispersion syndrome. *J Glaucoma.* 2012;21(6):351-7. doi: 10.1097/IJG.0b013e3182120877 pmid: 21423031
- Roberts DK, Wernick MN. Infrared imaging technique may help demonstrate iris transillumination defects in blacks who show other pigment dispersion syndrome clinical signs. *J Glaucoma.* 2007;16(5):440-7. doi: 10.1097/IJG.0b013e3181405e72 pmid: 17700286
- Chan EC, Roberts DK, Loconte DD, Wernick MN. Digital camera system to perform infrared photography of iris transillumination. *J Glaucoma.* 2002;11(5):426-8. doi: 10.1097/00061198-200210000-00010 pmid: 12362083
- Roberts DK, Yang Y, Lukic AS, Wilensky JT, Wernick MN. Quantification of pupil parameters in diseased and normal eyes with near infrared iris transillumination imaging. *Ophthalmic Surg Lasers Imaging.* 2012;43(3):196-204. doi: 10.3928/15428877-20120301-02 pmid: 22390965
- Czepita M. Near-infrared transillumination imaging combined with aperture photometry for the quantification of melanin in the iris pigment epithelium. *PLoS One.* 2020;15(3):e0230210. doi: 10.1371/journal.pone.0230210 pmid: 32143214