



Sutureless-dehydrated amniotic membrane (Omnigen®) mounted on contact lens (OmniLenz®) in the treatment of small corneal perforations secondary to exposure keratitis in ICU patients

Nancy M. Lotfy¹, Mubarak Alrasheedi², Rola Y. Khachaba³, Hamad Alshatti² and Yousef Taleb Ali²

¹ Department of Ophthalmology, Faculty of Medicine, Cairo University, Cairo, Egypt

² Department of Ophthalmology, Farwaniya Hospital, Kuwait

³ Department of Biological Sciences, University of Toronto – Scarborough, ON, Canada

ABSTRACT

Background: Exposure keratopathy is a common ocular complication in patients admitted to the intensive care unit (ICU) and may progress from superficial epithelial breakdown to corneal perforation, a vision-threatening emergency requiring timely management. Conventional treatments often necessitate urgent surgery, which is challenging in critically ill individuals who are unsuitable for surgical intervention. OmniLenz®, a customized bandage contact lens pre-lined with vacuum-dried Omnigen® amniotic membrane, offers a practical, non-surgical, bedside alternative for managing small corneal perforations. This study evaluates its clinical outcomes in ICU patients with a small corneal perforation secondary to exposure keratitis.

Methods: This prospective interventional case series included ICU patients with <1 mm corneal perforations secondary to exposure keratitis, recruited over a two-year interval. All patients underwent corneal scraping with culture and sensitivity testing, followed by targeted antimicrobial therapy. A dehydrated amniotic membrane (Omnigen®) was applied beneath a customized bandage contact lens (OmniLenz®) at the bedside under sterile conditions. Patients were examined daily using a portable slit-lamp and followed for one month. The primary outcome was perforation closure, defined by a negative Seidel test and anterior chamber reformation. Secondary outcomes included improvement in epithelial integrity, corneal infiltration, and ciliary injection.

Results: Five ICU patients, aged 18 to 70 years, with < 1 mm corneal perforations secondary to exposure keratitis were included. All eyes demonstrated rapid tectonic recovery following Omnigen®/OmniLenz® device application. Anterior chamber reformation and a negative Seidel test were achieved by day 7 in four patients and by day 10 in one patient. Complete perforation closure occurred in all cases. Marked improvement in keratitis was observed, with full epithelial defect healing and resolution of corneal infiltrates in every patient, followed by stable grade-3 stromal scarring. No neovascularization, device-related adverse events, or treatment complications occurred during the one-month follow-up.

Conclusions: Omnigen®/OmniLenz® device provides a safe, effective, and non-invasive bedside treatment for small corneal perforations secondary to exposure keratitis in critically ill ICU patients. Its use enabled consistent tectonic restoration, rapid perforation closure, and resolution of infection-associated corneal pathology without procedure-related complications. This approach offers a practical alternative to urgent surgical intervention in patients unsuitable for operative care and may serve as a valuable addition to corneal perforation management protocols. Further studies with larger cohorts are needed to evaluate its safety and efficacy in larger perforations and to determine long-term outcomes, including corneal scarring and visual acuity.

KEYWORDS

OmniLenz®, corneas, corneal epithelium, corneal perforations, exposure keratopathy, keratitides, amniotic membrane, intensive care unit, media, culture, fungus, bacteria

Correspondence: Nancy M. Lotfy, Department of Ophthalmology, Faculty of Medicine, Cairo University, Cairo, Egypt. Email: nancymaher@kasralainy.edu.eg, ORCID iD: <https://orcid.org/0000-0002-9159-0020>.

How to cite this article: Lotfy NM, Alrasheedi M, Khachaba RY, Alshatti H, Taleb Ali Y. Sutureless-dehydrated amniotic membrane (Omnigen®) mounted on contact lens (OmniLenz®) in the treatment of small corneal perforations secondary to exposure keratitis in ICU patients. Med Hypothesis Discov Innov Ophthalmol. 2025 Winter; 14(4): 194-203. <https://doi.org/10.51329/mehdiophthal1532>

Received: 26 October 2025; Accepted: 29 November 2025



Copyright © Author(s). This is an open-access article distributed under the terms of the Creative Commons Attribution-NonCommercial 4.0 International License (<https://creativecommons.org/licenses/by-nc/4.0/>) which permits copy and redistribute the material just in noncommercial usages, provided the original work is properly cited.



INTRODUCTION

Exposure keratopathy is the most common ocular surface disorder in patients admitted to the intensive care unit (ICU), with severity ranging from superficial epithelial erosions to progressive ulceration and, in advanced cases, corneal perforation [1, 2]. Corneal perforation represents exposure keratopathy's vision-threatening complication; without timely and appropriate management, may result in profound ocular morbidity and visual loss. The size of corneal perforation is a critical determinant of therapeutic strategy, although underlying cause, available treatment modalities, and surgeon experience also play important roles [3, 4].

Multiple surgical techniques have been described for the management of corneal perforations, including tissue adhesive glue application, amniotic membrane grafting, conjunctival flaps, and use of donor corneal tissue [4–7]. However, these interventions require urgent operative care, which poses substantial challenges in critically ill patients with unstable systemic conditions [3, 8, 9].

In this study, we evaluate the clinical outcomes of OmniLenz® (NuVision® Biotherapies Limited, Nottingham, UK)—a customized bandage contact lens pre-lined with the vacuum-dried amniotic membrane Omnigen® (NuVision® Biotherapies Limited, Nottingham, UK) [10, 11]—as a simple, bedside, non-surgical treatment for small (< 1 mm) corneal perforations secondary to exposure keratitis patients admitted to the ICU. This approach offers a potentially valuable alternative for individuals who are unsuitable for immediate surgical intervention.

METHODS

This prospective interventional case series recruited patients with corneal perforations secondary to exposure keratitis from the ICU of Al-Farwaniya Hospital, Kuwait, over a two-year interval. The study adhered to the principles of the Declaration of Helsinki and received approval from the regional Medical Ethics Committee in June 2024 (approval number: 2024-632-4385). The study was registered at ClinicalTrials.gov (ID: NCT06539663).

Patients were eligible if they presented with small corneal perforations measuring < 1 mm in diameter and had conclusive culture and sensitivity (C&S) findings—defined as positive corneal scrapings with identification of the causative microorganism—plus demonstrated initial improvement with antibiotic therapy. Exclusion criteria included larger corneal perforations and inconclusive C&S testing in which no microbial growth was detected. No age or sex restrictions were applied.

ICU patients were referred for corneal consultation due to lagophthalmos and absence of blinking. Visual acuity assessment was not feasible, as all patients were unconscious and intubated at the time of examination. The primary therapeutic aim was tectonic closure of the corneal perforation to preserve globe integrity.

Corneal scrapings [12–15] were collected from both the base and margins of the ulcer within the infiltrated area and immediately inoculated onto blood agar, chocolate agar, and MacConkey agar under standard laboratory conditions. Bacterial keratitis was diagnosed by microscopic identification of bacteria and confirmed by culture growth on these media. Fungal keratitis was diagnosed by detection of fungal hyphae on direct microscopy, with confirmatory culture on Sabouraud dextrose agar [14, 16]; positive fungal cultures were defined by the growth of characteristic colonies on this medium. Antimicrobial susceptibility testing [15, 16] was performed by the microbiologist, and results were used to guide targeted therapy.

A standardized eye-protection protocol was implemented for all ICU patients referred for corneal consultation [17–19]. This included eyelid and periocular hygiene every 12 h, with inspection for signs of inflammation or infection. Eyelids were closed with horizontally applied adhesive tape (3M™ Micropore™ Surgical/Medical Tape, 3M Medical Securement Tapes and Wraps, Kuwait). Lubrication consisted of preservative-free lubricant eye drops every 4 h (Systane, Alcon Inc., Geneva, Switzerland) and lubricant ointment every 12 h (Duratears, Alcon Inc., Geneva, Switzerland). All treatments were administered while patients remained in a comatose state without a blink reflex.

Those who developed exposure keratitis with corneal infiltration received corneal scrapings for C&S testing. All patients were treated with fortified vancomycin 5% ophthalmic solution (50 mg/mL; Zermacin, ancomycin Hydrochloride 0.5 g lyophilized powder for solution, Arwan Pharmaceutical Industries, Lebanon) and fortified ceftazidime 5% ophthalmic solution (50 mg/mL; Fortum®, ceftazidime 2 g, GlaxoSmithKline, Rueil-Malmaison, France) [20–23]. Therapy was subsequently modified according to C&S results. Both fortified antibiotics were administered hourly, day and night, for 48 h, followed by hourly dosing during waking hours for 5 days, then tapered to five times daily until complete epithelial healing and resolution of keratitis.

Cases that progressed to corneal melt with perforation < 1 mm, accompanied by a positive Seidel test using sterile fluorescein solution (Minims® Fluorescein Sodium 2% w/v, Bausch and Lomb, London, UK) and a shallow anterior chamber, were managed under a sterile setup following instillation of topical anesthesia (Benoxinate 0.5% eye drops, Minims® Oxybuprocaine Hydrochloride 0.4% w/v, Bausch and Lomb, London, UK). These patients underwent sutureless application of a dehydrated amniotic membrane (Omnigen®) beneath a specialized bandage contact lens (OmniLenz®) [10]. The Omnigen® [24, 25] typically dissolves within 7–10 days [26], after which the contact lens is removed. Antimicrobial therapy was continued based on each patient's individualized treatment plan.

Daily bedside ophthalmological examinations were performed using a portable slit lamp with 10× and 16× magnification (Keeler™ Classic PSL Portable Hand Held Slit Lamp, Keeler Ltd., Windsor, UK). All patients were followed for one month. Bedside photographs of the affected eyes were obtained during follow-up, as conventional slit-lamp imaging was not possible in bed-ridden patients.

Primary outcome measures included closure of the corneal perforation, a negative Seidel test, and reformation of the anterior chamber. Secondary outcomes included improvement in ciliary injection, reduction in epithelial defect size, and resolution of corneal infiltration. These outcomes were assessed daily, documenting the timing of each clinical event. Epithelial healing time was recorded in days, defined as the interval until complete absence of fluorescein staining. Grading of corneal scar at the final visit was done according to the grading system described in the literature (grade 0–3 based on visibility of iris details) [27].

Data from each patient were entered into Microsoft Excel® spreadsheet software for descriptive reporting. The dataset included baseline variables such as age, sex, ICU diagnosis, laterality, time from ICU admission to onset of exposure keratitis, C&S results, perforation site, perforation onset (days), epithelial defect size (mm) at diagnosis of exposure keratitis, grade of ciliary injection, and size of corneal infiltration at the time of diagnosis. Additionally, final-examination variables were recorded, including grade of corneal scarring at perforation healing, epithelial defect size at the time of perforation healing, size of corneal infiltration at perforation healing, duration of corneal perforation healing (days), duration of epithelial defect healing (days), and the insertion-to-dissolution interval (days) for Omnigen®, as determined by clinical observation.

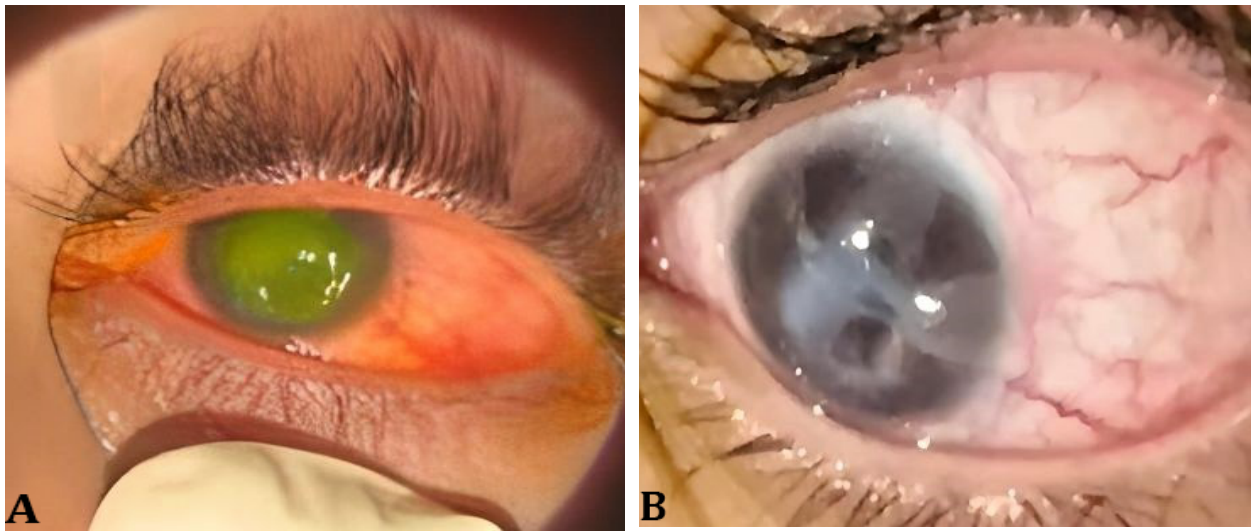
RESULTS

A total of five male ICU patients, aged 18 to 70 years, were included in this study. All patients were unconscious and intubated for serious life-threatening conditions, as outlined in Table 1. Onset of exposure keratitis occurred between 5 and 7 days following ICU admission. Corneal perforations subsequently developed 7 to 10 days after the diagnosis of exposure keratitis, with perforation sites located in the inferior cornea in three patients and the central cornea in two patients (Table 1).

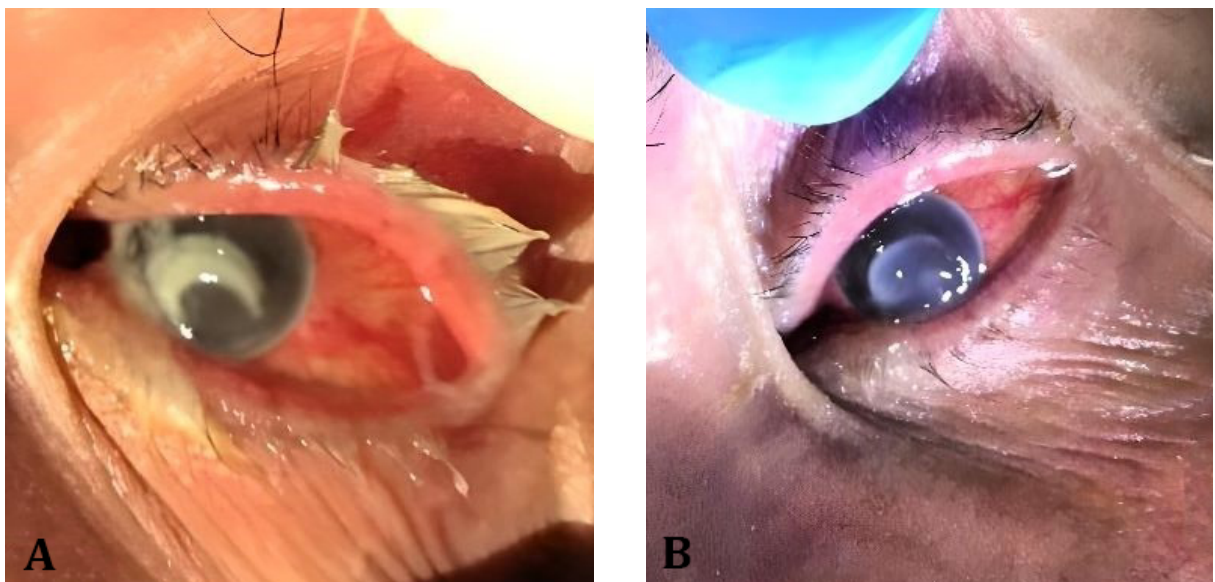
C&S testing identified *Stenotrophomonas maltophilia*, *Klebsiella pneumoniae*, and *Candida auris* in patient 1; *Candida* in patient 2; *Pseudomonas aeruginosa* in patient 3; and *Staphylococcus aureus* in both patients 4 and 5. Based on these findings, patients 1 and 2 required adjunctive antifungal therapy with amphotericin B 0.15% eye drops (AmBisome, Liposomal Amphotericin B 50 mg powder for concentrate/dispersion/infusion, Gilead Sciences, Ireland), as dictated by C&S results.

Each patient received a single OmniLenz® for one week. Omnigen® was placed directly onto the cornea and secured beneath the OmniLenz® device. In Patient 2, lens displacement occurred after three days, necessitating replacement with a second device. All OmniLenz® bandage lenses were removed after one week. Following placement of the Omnigen®/OmniLenz® device, reformation of the anterior chamber and a negative Seidel test were confirmed by day 7 in all cases except patient 2, in whom these outcomes were achieved on day 10. Complete healing of the corneal perforation was documented in all five patients.

At the final follow-up examination, all cases demonstrated improvement in keratitis with complete epithelial defect closure, except for the presence of diffuse superficial punctate keratopathy. Corneal infiltration improved in all patients, and each developed a grade 3 corneal scar. No corneal neovascularization was observed in any case. Detailed baseline and final visit findings, along with the clinical course for each patient, are presented in Table 1. Baseline and final anterior segment photographs for patients 1 and 2 are shown in Figures 1 and 2.



Figures 1A and 1B. Left eye of patient 1, a 70-year-old male admitted to the intensive care unit (ICU) following cardiac arrest and renal failure. (A): marked grade-3 ciliary injection, a 9-mm central epithelial defect, a 7-mm corneal infiltration, and an inferior corneal microperforation. (B): improvement to grade-2 ciliary injection with complete epithelial defect healing and development of a grade-3 corneal scar.



Figures 2A and 2B. Left eye of patient 2, a 30-year-old male admitted to the intensive care unit (ICU) with quadriparesis following acoustic neuroma surgery. (A): grade-3 ciliary injection, an 8-mm central epithelial defect, a 7-mm corneal infiltration, and an inferior corneal microperforation. (B): persistent grade-3 ciliary injection with complete epithelial defect healing and development of a grade 3-corneal scar.

Table 1. Detailed baseline characteristics, clinical course, and final-visit findings for each patient

Case	Baseline Age	Sex	ICU Diagnosis	Eye	EK Onset (d)	C&S Results	Perforation Site	Perforation Onset (d)	ED Size (mm)	Grade of Ci. I.	Co. I. (mm)	Final examination Grade of C.S.	Co. I. or ED (mm)	Duration of Perforation and ED Healing (d)	Insertion-Dissolution Interval for Omnigen® (d)
1	70 y	M	Post cardiac arrest + Renal failure	OS	5	Stenotrophomonas nas Maltophilia, Klebsiella Pneumoniae, and Candida Auris	Inferior	7	9	3	7	3	Resolved	7	7
2	30 y	M	Quadripareisis post-Acoustic Neuroma surgery	OS	7	Candida	inferior	7	8	3	7	3	Resolved	10	7
3	18 y	M	Buggy accident with brain contusions and brainstem death	OD	7	Pseudomonas Aeruginosa	Inferior	8	9	1	6	3	Resolved	7	7
4	40 y	M	RTA	OS	6	Staphylococcus Aureus	Central	7	6	1	4	3	Resolved	7	7
5	32 y	M	RTA	OD	7	Staphylococcus Aureus	Central	10	7	1	5	3	Resolved	7	7

Abbreviations: ICU, intensive care unit; EK, exposure keratitis; d, days; C&S, culture and sensitivity testing; ED, epithelial defect; mm, millimeters; Ci.I., ciliary injection; Co.I., corneal infiltration size; C.S., corneal scar; y, years; M, male; RTA, road traffic accident; OS, left eye; OD, right eye. Note: This table summarizes the onset (in days) of EK and subsequent corneal perforation, as well as the clinical course and findings at baseline and after treatment for each patient. The corneal scar grade was classified using a published grading system (grades 0-3) based on iris detail visibility [27]. The insertion-dissolution interval for Omnigen® was determined by clinical observation. The onset of EK is reported as the number of days from ICU admission. The onset of corneal perforation is reported as the number of days from the diagnosis of exposure keratitis to the diagnosis of perforation.

DISCUSSION

This case series highlights the clinical significance of exposure keratitis in critically ill patients, a population in whom ocular health is often overlooked amid competing systemic priorities. In our cohort, five ICU patients developed exposure keratitis complicated by micro-perforation at the inferior or central cornea despite eyelid closure and protocol-based administration of lubricating drops, underscoring that standard prophylactic measures may be insufficient in high-risk settings. Previous studies report that ocular complications occur in 20%–60% of ICU patients, influenced by factors such as lagophthalmos, mechanical ventilation, prolonged ICU admission, traumatic injury, and improper eye-care practices [4]. Staff training [28] and adherence to prescribed ocular treatment regimens are also critical determinants of patient outcomes. In busy, high-stress ICU settings, eye care is often deprioritized relative to other organ systems, and poor compliance with exposure keratopathy protocols has been documented in an audit from St George's Hospital [29].

In this context, we evaluated OmniLenz® combined with Omnigen® as a treatment for small corneal perforations (<1 mm) arising from exposure keratitis in patients admitted to the ICU. Omnigen® is a vacuum-dehydrated amniotic membrane that can be stored at room temperature and rehydrated with a drop of balanced salt solution prior to use. OmniLenz® facilitates simple, sutureless bedside application, and the treatment can be repeated if clinically required [10, 11, 26]. In all cases, complete closure of the corneal perforation was achieved, confirmed by negative Seidel testing and full anterior chamber reformation. Keratitis improved substantially, with complete epithelial healing and reduction of corneal infiltration within one week. No complications related to Omnigen® /OmniLenz® were observed.

The therapeutic benefits of amniotic membrane in this setting are attributable to its anti-inflammatory and antimicrobial properties [30, 31], as well as its reservoir of growth factors that promote migration and differentiation of corneal epithelial cells [32]. Some evidence also suggests the potential for corneal stromal tissue synthesis from amniotic membrane substrate [33]. The role of amniotic membrane in treating corneal perforations was reported, where success rates of up to 100% have been reported for microperforations and 75% for perforations up to 1.5 mm in diameter [4]. In clinical practice, amniotic membrane is widely used as an adjunct to antimicrobial therapy in infectious keratitis [34]; in our series, all patients had already received targeted antimicrobial treatment with signs of clinical improvement prior to amniotic membrane placement.

Alternative treatments for small perforations include tissue adhesives—cyanoacrylate or fibrin glue—though these show variable success (20%–90%) [4]. Cyanoacrylate glue achieves approximately 40% success in some series [35] but carries risks of corneal and lenticular toxicity [4] and can induce high intraocular pressure secondary to trabecular meshwork inflammation [36]. Fibrin glue, while less toxic, degrades rapidly and lacks antimicrobial effects; moreover, the use of bovine-derived components raises concerns about prion or viral transmission [37]. Larger perforations may require conjunctival flaps—associated with increased corneal vascularization and subsequent graft-rejection risk—or tectonic keratoplasty [4]. Although both lamellar and penetrating keratoplasty are established options, lamellar techniques have gained favor due to their lower rejection rates [4]. Sutureless amniotic membrane transplantation has also yielded reduced haze, improved surface integrity, and decreased vascularization in chronic keratoconjunctivitis and exposure keratopathy [38]. In our series no case displayed corneal neovascularization.

Our results complement and extend existing literature on dehydrated amniotic membrane use across diverse indications. Trave-Huarte et al. [39] focused on symptomatic and ocular surface improvements in dry eye following bilateral dehydrated amniotic membrane application; our series demonstrates that the same platform can provide effective tectonic repair in acute pathology. In contrast to their chronic symptomatic benefits observed in dry eye [39], our patients achieved rapid structural restoration, including anterior chamber reformation, even in the presence of bacterial or fungal infection.

Similarly, while Maqsood et al. [11] reported complete healing in 58% of persistent epithelial defects over an average of 22 days [11], our cohort—despite being critically ill and mechanically compromised with actively infected exposure keratitis—achieved 100% perforation closure within 7–10 days. Their study emphasized non-ectonic epithelial rescue across diverse etiologies [11], whereas ours highlights rapid tectonic reinforcement in vision-threatening disease.

More recently, a randomized trial by Trave-Huarte et al. demonstrated long-term neuroregenerative and symptomatic benefits in moderate-to-severe dry eye [40]. Our findings, however, support the acute tectonic utility of Omnigen®/OmniLenz® in a dramatically different clinical environment. In unconscious ICU patients with exposure keratitis and active bacterial and fungal infection complicated with corneal perforation, plus rapidly progressive epithelial breakdown, the device facilitated rapid structural stabilization and infection-adjunctive healing in all cases.

Cross-species comparison also highlights the strength of our results. Veterinary reports describe heterogeneous surgical uses of Omnigen® for corneal ulceration with a 93.5% healing rate (31 eyes out of 33) but a 21.7% graft-failure rate (10 eyes out of 46) [41]. By contrast, our uniform, critically ill human cohort demonstrated consistent and rapid tectonic success following a single application, underscoring robust structural efficacy even in high-risk, infection-complicated disease. While Xanthopoulou et al. documented the value of Omnigen® as a suture-free graft reducing operative time and discomfort in pterygium surgery [42], our results extend its application to a far more urgent and severe domain. In our cohort, Omnigen®/OmniLenz® restored ocular integrity in the presence of active microbial perforation, demonstrating a level of tectonic reinforcement not required in pterygium care.

To our knowledge, this report is the first to describe OmniLenz® for the bedside management of small corneal perforations in critically ill ICU patients. The approach provided a practical, non-surgical solution for individuals unsuitable for operative intervention, achieving complete restoration of corneal integrity in all cases. Despite limitations—including a small sample size and the absence of a control group—our findings suggest that Omnigen®/OmniLenz® device may fill a critical therapeutic niche by reducing the need for more invasive surgical procedures. Further studies should investigate its efficacy in larger perforations and assess long-term outcomes, including scarring and visual acuity.

CONCLUSIONS

Omnigen®/OmniLenz® device represents a safe, effective, and minimally invasive therapeutic option for small corneal perforations complicating exposure keratitis in ICU patients. Its ease of bedside application, biological advantages, and consistently successful outcomes in our series suggest that it may serve as a valuable addition to current treatment protocols, potentially reducing reliance on invasive surgical interventions. Additional research involving larger patient cohorts is required to further define its safety and efficacy in managing larger perforations and to evaluate long-term outcomes, including visual potential in critically ill patients following recovery from ICU care.

ETHICAL DECLARATIONS

Ethical approval: The Declaration of Helsinki was followed in this study protocol, with reviewal and approval by the regional Medical Ethics Committee achieved in June 2024 with approval number: 2024-632-4385. The study is registered in ClinicalTrials.gov with ID: NCT06539663.

Conflict of interest: None.

FUNDING

None.

ACKNOWLEDGMENTS

None.

REFERENCES

1. Alansari MA, Hijazi MH, Maghrabi KA. Making a Difference in Eye Care of the Critically Ill Patients. *J Intensive Care Med*. 2015 Sep;30(6):311-7. doi: [10.1177/0885066613510674](https://doi.org/10.1177/0885066613510674). Epub 2013 Nov 7. PMID: [24212598](https://pubmed.ncbi.nlm.nih.gov/24212598/).
2. Chen Y, He J, Wu Q, Pu S, Song C. Prevalence and risk factors of exposure keratopathy among critically ill patients: A systematic review and meta-analysis. *Nurs Open*. 2024 Jan;11(1):e2061. doi: [10.1002/nop2.2061](https://doi.org/10.1002/nop2.2061). PMID: [38268267](https://pubmed.ncbi.nlm.nih.gov/38268267/); PMCID: [PMC10721942](https://pubmed.ncbi.nlm.nih.gov/PMC10721942/).
3. Hayek G, Francois J, Perone JM. Corneal Perforation Repair Using a Novel Lyophilized Amniotic Membrane Graft Technique: Plug and Patch. *Am J Case Rep*. 2023 Jun 20;24:e939626. doi: [10.12659/AJCR.939626](https://doi.org/10.12659/AJCR.939626). PMID: [37339105](https://pubmed.ncbi.nlm.nih.gov/37339105/); PMCID: [PMC10290435](https://pubmed.ncbi.nlm.nih.gov/PMC10290435/).
4. Deshmukh R, Stevenson LJ, Vajpayee R. Management of corneal perforations: An update. *Indian J Ophthalmol*. 2020 Jan;68(1):7-14. doi: [10.4103/ijo.IJO_1151_19](https://doi.org/10.4103/ijo.IJO_1151_19). PMID: [31856457](https://pubmed.ncbi.nlm.nih.gov/31856457/); PMCID: [PMC6951192](https://pubmed.ncbi.nlm.nih.gov/PMC6951192/).
5. Yin J, Singh RB, Al Karmi R, Yung A, Yu M, Dana R. Outcomes of Cyanoacrylate Tissue Adhesive Application in Corneal Thinning and Perforation. *Cornea*. 2019 Jun;38(6):668-673. doi: [10.1097/ICO.0000000000001919](https://doi.org/10.1097/ICO.0000000000001919). PMID: [30865049](https://pubmed.ncbi.nlm.nih.gov/30865049/); PMCID: [PMC6517072](https://pubmed.ncbi.nlm.nih.gov/PMC6517072/).
6. Daryabari SH, Ghasemian M, Lotfi E, Solouki A, Lin K, Manoochehrabadi T, Hosseini Imeni SM, Esmaili Gouvarchin Ghaleh H. Placental-Derived Products for Corneal Regeneration: Applications of Amniotic Membrane, Cord Blood Serum, and Stem Cells: A Review. *Transplant Cell Ther*. 2025 Sep 17:S2666-6367(25)01448-4. doi: [10.1016/j.jtct.2025.09.024](https://doi.org/10.1016/j.jtct.2025.09.024). Epub ahead of print. PMID: [40972961](https://pubmed.ncbi.nlm.nih.gov/40972961/).

7. Aghamollaei H, Hashemi H, Fallahtafti M, Daryabari SH, Khabazkhoob M, Jadidi K. Applications of SMILE-extracted lenticules in ophthalmology. *Int J Ophthalmol*. 2024 Jan 18;17(1):173-187. doi: 10.18240/ijo.2024.01.23. PMID: 38239948; PMCID: PMC10754658.
8. Sharma A, Sharma N, Basu S, Sharma R, Aggarwal S, Gupta PC, Ram J, Nirankari VS. Tissue Adhesives for the Management of Corneal Perforations and Challenging Corneal Conditions. *Clin Ophthalmol*. 2023 Jan 15;17:209-223. doi: 10.2147/OPTH.S394454. PMID: 36685088; PMCID: PMC9851054.
9. Hick S, Demers PE, Brunette I, La C, Mabon M, Duchesne B. Amniotic membrane transplantation and fibrin glue in the management of corneal ulcers and perforations: a review of 33 cases. *Cornea*. 2005 May;24(4):369-77. doi: 10.1097/01.icc.0000151547.08113.d1. PMID: 15829790.
10. Spencer T(2021). 'OmniLenz® application of Omnigen®: our simple 4 – 6-minute procedure for suture free ambulatory application of Omnigen amniotic membrane'. Available at: <https://www.nu-vision.co.uk/omnilenz-application-of-omnigen/> (Accessed October 22, 2024).
11. Maqsood S, Elsawah K, Dhillon N, Soliman S, Laginaf M, Lodhia V, Lake D, Hamada S, Elalfy M. Management of Persistent Corneal Epithelial Defects with Human Amniotic Membrane-derived Dry Matrix. *Clin Ophthalmol*. 2021 May 28;15:2231-2238. doi: 10.2147/OPTH.S299141. PMID: 34093006; PMCID: PMC8169046.
12. Parmar GS, Meena AK, Borde P, Prasad S. Microbial keratitis and antibiotic sensitivity patterns: A retrospective analysis at a tertiary center in Central India. *Indian J Ophthalmol*. 2023 Jun;71(6):2455-2459. doi: 10.4103/ijo.IJO_2070_22. PMID: 37322659; PMCID: PMC10417949.
13. Bashir G, Shah A, Thokar MA, Rashid S, Shakeel S. Bacterial and fungal profile of corneal ulcers--a prospective study. *Indian J Pathol Microbiol*. 2005 Apr;48(2):273-7. PMID: 16758694.
14. Mabrouk NA, Abdelkader MF, Abdelhakeem MA, Mourad KM, Abdelghany AA. Epidemiology, clinical profile and treatment outcomes of bacterial and fungal keratitis. *Int Ophthalmol*. 2022 May;42(5):1401-1407. doi: 10.1007/s10792-021-02128-x. Epub 2021 Nov 28. PMID: 34839447.
15. Xie L, Zhong W, Shi W, Sun S. Spectrum of fungal keratitis in north China. *Ophthalmology*. 2006 Nov;113(11):1943-8. doi: 10.1016/j.opthta.2006.05.035. Epub 2006 Aug 28. PMID: 16935335.
16. Ibrahim YW, Boase DL, Cree IA. Epidemiological characteristics, predisposing factors and microbiological profiles of infectious corneal ulcers: the Portsmouth corneal ulcer study. *Br J Ophthalmol*. 2009 Oct;93(10):1319-24. doi: 10.1136/bjo.2008.151167. Epub 2009 Jun 4. PMID: 19502241.
17. Swiston CJ, Hu KS, Simpson A, Burton E, Brintz BJ, Lin A. Prevention of Exposure Keratopathy in the Intensive Care Unit: Evaluation of an EMR-Based Lubrication Order Protocol for Ventilated Patients. *J Acad Ophthalmol* (2017). 2022 Jul 27;14(2):e141-e146. doi: 10.1055/s-0042-1750020. PMID: 37388182; PMCID: PMC9927954.
18. Zhou Y, Liu J, Cui Y, Zhu H, Lu Z. Moisture chamber versus lubrication for corneal protection in critically ill patients: a meta-analysis. *Cornea*. 2014 Nov;33(11):1179-85. doi: 10.1097/ICO.0000000000000224. PMID: 25170579.
19. Lenart SB, Garrity JA. Eye care for patients receiving neuromuscular blocking agents or propofol during mechanical ventilation. *Am J Crit Care*. 2000 May;9(3):188-91. PMID: 10800604.
20. Chédru-Legros V, Fines-Guyon M, Chérel A, Perdriel A, Albessard F, Debruyne D, Mouriaux F. Stabilité à -20 degrés C des collyres antibiotiques renforcés (amikacine, ceftazidime, vancomycine) [Fortified antibiotic (vancomycin, amikacin and ceftazidime) eye drop stability assessment at -20 degrees C]. *J Fr Ophtalmol*. 2007 Oct;30(8):807-13. French. doi: 10.1016/s0181-5512(07)92614-5. PMID: 17978677.
21. Saillard J, Spiesser-Robelet L, Gohier P, Briot T. Bacterial keratitis treated by strengthened antibiotic eye drops: An 18 months review of clinical cases and antibiotic susceptibilities. *Ann Pharm Fr*. 2018 Mar;76(2):107-113. doi: 10.1016/j.pharma.2017.11.005. Epub 2017 Dec 19. PMID: 29273244.
22. Ratprasatporn N, Wittayalertpanya S, Khemsri W, Chatsuwat T, Chongpison Y, Chamsai T, Wattanakijkarn M, Chansangpetch S. Stability and Sterility of Extemporaneously Prepared Nonpreserved Cefazolin, Ceftazidime, Vancomycin, Amphotericin B, and Methylprednisolone Eye Drops. *Cornea*. 2019 Aug;38(8):1017-1022. doi: 10.1097/ICO.0000000000001992. PMID: 31090593.
23. Roura-Turet J, Rodriguez-Reyes M, Guerrero-Molina L, Soy-Muner D, López-Cabezas C. Stability of 5% vancomycin ophthalmic solution prepared using balanced salt solution after freezing for 90 days. *Am J Health Syst Pharm*. 2021 Jul 22;78(15):1444-1447. doi: 10.1093/ajhp/zxab195. PMID: 33950182.

24. Hopkinson A, Britchford ER, Sidney LE. Preparation of Dried Amniotic Membrane for Corneal Repair. *Methods Mol Biol.* 2020;2145:143-157. doi: [10.1007/978-1-0716-0599-8_10](https://doi.org/10.1007/978-1-0716-0599-8_10). PMID: [32542605](https://pubmed.ncbi.nlm.nih.gov/32542605/).
25. Dua HS, Ting DSJ, AlSaadi A, Said DG. Management of limbal stem cell deficiency by amnion-assisted conjunctival epithelial redirection using vacuum-dried amniotic membrane and fibrin glue. *Br J Ophthalmol.* 2023 Mar;107(3):342-348. doi: [10.1136/bjophthalmol-2020-318496](https://doi.org/10.1136/bjophthalmol-2020-318496). Epub 2021 Oct 5. PMID: [34610946](https://pubmed.ncbi.nlm.nih.gov/34610946/).
26. Lotfy NM, Al Rashidi S, Hagrass SM. Clinical outcomes of vacuum-dehydrated amniotic membrane (Omnigen) mounted on contact lens (Omnilenz) in eyes with acute chemical eye injuries. *Graefes Arch Clin Exp Ophthalmol.* 2023 Dec;261(12):3541-3547. doi: [10.1007/s00417-023-06151-9](https://doi.org/10.1007/s00417-023-06151-9). Epub 2023 Jun 26. PMID: [37358651](https://pubmed.ncbi.nlm.nih.gov/37358651/); PMCID: [PMC10667437](https://pubmed.ncbi.nlm.nih.gov/PMC10667437/).
27. Shimizu E, Yamaguchi T, Tsubota K, Shimazaki J. Corneal Higher-Order Aberrations in Eyes With Corneal Scar After Traumatic Perforation. *Eye Contact Lens.* 2019 Mar;45(2):124-131. doi: [10.1097/ICL.0000000000000530](https://doi.org/10.1097/ICL.0000000000000530). PMID: [30005054](https://pubmed.ncbi.nlm.nih.gov/30005054/).
28. Ezra DG, Chan MP, Solebo L, Malik AP, Crane E, Coombes A, Healy M. Randomised trial comparing ocular lubricants and polyacrylamide hydrogel dressings in the prevention of exposure keratopathy in the critically ill. *Intensive Care Med.* 2009 Mar;35(3):455-61. doi: [10.1007/s00134-008-1284-4](https://doi.org/10.1007/s00134-008-1284-4). Epub 2008 Sep 23. Erratum in: *Intensive Care Med.* 2009 Mar;35(3):578. PMID: [18810388](https://pubmed.ncbi.nlm.nih.gov/18810388/).
29. Dawson D. Development of a new eye care guideline for critically ill patients. *Intensive Crit Care Nurs.* 2005 Apr;21(2):119-22. doi: [10.1016/j.iccn.2005.01.004](https://doi.org/10.1016/j.iccn.2005.01.004). PMID: [15778076](https://pubmed.ncbi.nlm.nih.gov/15778076/).
30. Dua HS, Gomes JA, King AJ, Maharajan VS. The amniotic membrane in ophthalmology. *Surv Ophthalmol.* 2004 Jan-Feb;49(1):51-77. doi: [10.1016/j.survophthal.2003.10.004](https://doi.org/10.1016/j.survophthal.2003.10.004). PMID: [14711440](https://pubmed.ncbi.nlm.nih.gov/14711440/).
31. Nokhbedehghan Z, Esmaeili Z, Daryabari SH, Aghamollaei H, Simorgh S, Majidi J, Alizadeh S, Khosravimelal S, Chauhan NP, Nasiri H, Gholipourmalekabadi M. Corneal Cell Matrix-Conditioned Amniotic Membrane with Improved Biochemical Properties and Corneal Wound Healing Potential: An In Vitro and In Vivo Study. *Macromolecular Materials and Engineering.* 2025 Feb 27;2400390. doi: [10.1002/mame.202400390](https://doi.org/10.1002/mame.202400390).
32. Long Q, Huang C, Zhang L, Jiang H, Zhao S, Zhang L, Zheng X, Ou S, Gu H. A novel tissue-engineered corneal epithelium based on ultra-thin amniotic membrane and mesenchymal stem cells. *Sci Rep.* 2024 Jul 29;14(1):17407. doi: [10.1038/s41598-024-68219-8](https://doi.org/10.1038/s41598-024-68219-8). PMID: [39075142](https://pubmed.ncbi.nlm.nih.gov/39075142/); PMCID: [PMC11286932](https://pubmed.ncbi.nlm.nih.gov/PMC11286932/).
33. Solomon A, Meller D, Prabhasawat P, John T, Espana EM, Steuhl KP, Tseng SC. Amniotic membrane grafts for nontraumatic corneal perforations, descemetocoeles, and deep ulcers. *Ophthalmology.* 2002 Apr;109(4):694-703. doi: [10.1016/s0161-6420\(01\)01032-6](https://doi.org/10.1016/s0161-6420(01)01032-6). PMID: [11927426](https://pubmed.ncbi.nlm.nih.gov/11927426/).
34. Ting DSJ, Henein C, Said DG, Dua HS. Amniotic membrane transplantation for infectious keratitis: a systematic review and meta-analysis. *Sci Rep.* 2021 Jun 21;11(1):13007. doi: [10.1038/s41598-021-92366-x](https://doi.org/10.1038/s41598-021-92366-x). PMID: [34155280](https://pubmed.ncbi.nlm.nih.gov/34155280/); PMCID: [PMC8217254](https://pubmed.ncbi.nlm.nih.gov/PMC8217254/).
35. Setlik DE, Seldomridge DL, Adelman RA, Semchyshyn TM, Afshari NA. The effectiveness of isobutyl cyanoacrylate tissue adhesive for the treatment of corneal perforations. *Am J Ophthalmol.* 2005 Nov;140(5):920-1. doi: [10.1016/j.ajo.2005.04.062](https://doi.org/10.1016/j.ajo.2005.04.062). PMID: [16310475](https://pubmed.ncbi.nlm.nih.gov/16310475/).
36. Leahey AB, Gottsch JD, Stark WJ. Clinical experience with N-butyl cyanoacrylate (Nexacryl) tissue adhesive. *Ophthalmology.* 1993 Feb;100(2):173-80. doi: [10.1016/s0161-6420\(93\)31674-x](https://doi.org/10.1016/s0161-6420(93)31674-x). PMID: [8437823](https://pubmed.ncbi.nlm.nih.gov/8437823/).
37. Chen WL, Lin CT, Hsieh CY, Tu IH, Chen WY, Hu FR. Comparison of the bacteriostatic effects, corneal cytotoxicity, and the ability to seal corneal incisions among three different tissue adhesives. *Cornea.* 2007 Dec;26(10):1228-34. doi: [10.1097/ICO.0b013e3181506129](https://doi.org/10.1097/ICO.0b013e3181506129). PMID: [18043181](https://pubmed.ncbi.nlm.nih.gov/18043181/).
38. Suri K, Kosker M, Raber IM, Hammersmith KM, Nagra PK, Ayres BD, Halfpenny CP, Rapuano CJ. Sutureless amniotic membrane ProKera for ocular surface disorders: short-term results. *Eye Contact Lens.* 2013 Sep;39(5):341-7. doi: [10.1097/ICL.0b013e3182a2f8fa](https://doi.org/10.1097/ICL.0b013e3182a2f8fa). PMID: [23945524](https://pubmed.ncbi.nlm.nih.gov/23945524/).
39. Travé-Huarte S, Wolffsohn JS. Bilateral Sutureless Application of Human Dehydrated Amniotic Membrane with a Specialised Bandage Contact Lens for Moderate-to-Severe Dry Eye Disease: A Prospective Study with 1-Month Follow-Up. *Clin Ophthalmol.* 2024 May 13;18:1329-1339. doi: [10.2147/OPTH.S458715](https://doi.org/10.2147/OPTH.S458715). PMID: [38765455](https://pubmed.ncbi.nlm.nih.gov/38765455/); PMCID: [PMC11100494](https://pubmed.ncbi.nlm.nih.gov/PMC11100494/).
40. Travé-Huarte S, Wolffsohn JS. Sutureless Dehydrated Amniotic Membrane (Omnigen) Application Using a Specialised Bandage Contact Lens (OmniLenz) for the Treatment of Dry Eye Disease: A 6-Month Randomised

- Control Trial. *Medicina (Kaunas)*. 2024 Jun 15;60(6):985. doi: 10.3390/medicina60060985. PMID: 38929602; PMCID: PMC11205730.
41. Maini S, Hurley-Bennett K, Dawson C. Case Series Describing the Use of Low-Temperature Vacuum-Dehydrated Amnion (Omnigen) for the Treatment of Corneal Ulcers in Cats and Dogs: 46 Cases (2016-2017). *Top Companion Anim Med*. 2020 Nov;41:100474. doi: 10.1016/j.tcam.2020.100474. Epub 2020 Sep 9. PMID: 32919060.
 42. Xanthopoulou PT, Elanwar M, Alzyadi M, Lavaris A, Kopsachilis N. A Novel Sutureless Pterygium Excision Surgery Using Human-Derived Dehydrated Amniotic Membrane. *Cureus*. 2022 Apr 5;14(4):e23839. doi: 10.7759/cureus.23839. PMID: 35530838; PMCID: PMC9072255.