



Cataract Surgery in Anterior Megalophthalmos: A Review

Virgilio GALVIS, MD^{1 2 3}; Alejandro TELLO, MD^{1 2 3}; Carlos M. RANGEL, MD^{2 4}

¹ Centro Oftalmológico Virgilio Galvis, Floridablanca, Colombia

² Fundación Oftalmológica de Santander FOSCAL, Floridablanca, Colombia

³ Universidad Autónoma de Bucaramanga (UNAB), Bucaramanga, Colombia

⁴ Universidad Industrial de Santander, Bucaramanga, Colombia

ABSTRACT

Anterior megalophthalmos is characterized by megalocornea associated with a very broad anterior chamber and ciliary ring elongation. It is also called X-linked megalocornea. It is accompanied by early development of cataracts, zonular anomalies, and, rarely, vitreoretinal disorders. Subluxation of a cataract can occur in cataract surgery because of zonular weakness. In addition, in most patients, standard intraocular lens (IOL) decentration is a risk because of the enlarged sulcus and capsular bag. These unique circumstances make cataract surgery challenging. To date, several approaches have been developed. Implantation of a retropupillary iris-claw aphakic intraocular lens may be a good option because it is easier than suturing the IOL and can have better and more stable anatomic and visual outcomes, compared to other techniques.

KEY WORDS

Iris-claw intraocular lens; megalocornea; megalophthalmos

©2015, Med Hypothesis Discov Innov Ophthalmol.

This is an open-access article distributed under the terms of the Creative Commons Attribution NonCommercial 3.0 License (CC BY-NC 3.0), which allows users to read, copy, distribute and make derivative works for non-commercial purposes from the material, as long as the author of the original work is cited properly.

Correspondence to:

Dr. Alejandro Tello, Centro Medico Ardila Lülle, Piso 3, Modulo 7. Floridablanca, Colombia, Tel: +577 6392929; E-Mail: alejandrotello@gmail.com

INTRODUCTION

In 1914, Seefelder initially described anterior megalophthalmos, as cited by Wright (1). It is characterized by megalocornea, which is associated with a very deep anterior chamber and ciliary ring elongation (Figure 1) (1). The pathogenesis of anterior megalophthalmos remains unknown. It results from keratodysgenesis and iridogoniodysgenesis, or both (2). X-linked recessive inheritance exists in 50% of patients, autosomal transmission in 40% of patients, and it is sporadic in the remaining 10% of patients. Men

constitute approximately 90% of patients. Gene linkage data have suggested that the X-linked megalocornea locus maps in the region Xq12-q26 (3). Other diseases associated with anterior megalophthalmos are Marfan's syndrome, trisomy 21, Apert syndrome, mucopolipidosis type 2, and Walker Warburg syndrome (4,5).

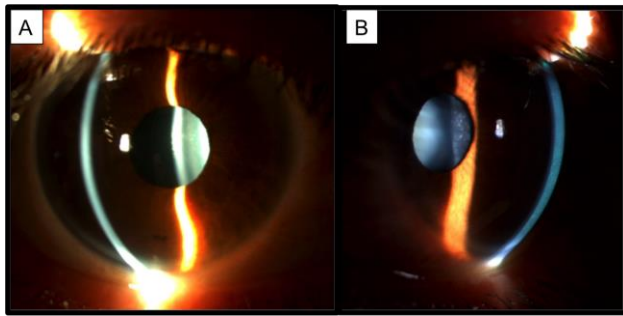


Figure 1. Anterior megalophthalmos presents with megalocornea and a very deep anterior chamber. Early onset cataracts are a common finding (Photos are kindly provided by Dr. Virgilio Galvis).

Early appearance of cataracts and subluxation of the crystalline lens, are the leading causes of decreased vision in these patients. Cataracts usually develop between the ages of 30 and 50 years (3,6). Besides cataracts and zonular anomalies, these patients also present with other anterior segment abnormalities: atrophy of the iris, hypoplasia of the pupil dilator muscle, transillumination defects of the iris, pigmentary dispersion, mosaic corneal dystrophy, anterior embryotoxon, myopia, iridodonesis, miosis, inadequate pupillary dilatation, retroposition of the lens-iris diaphragm, shortening of the vitreous cavity, a very wide angle on gonioscopy with band broadening of the ciliary body, and excessive mesenchymal tissue in the anterior chamber angle (7). Posterior segment abnormalities in the eye also have been described: vitreous fibrillar degeneration with liquefaction, optically empty vitreous with strands, peripheral retinal degenerations (lattice), spontaneous vitreous hemorrhage, peripheral retinal neovascularization, retinal breaks, and retinal detachment (8, 9). In patients with corneal enlargement, differential diagnoses include megalocornea, megalophthalmos, congenital glaucoma, and keratoglobus (1-29) (Table 1). The principal characteristics of megalocornea are bilateral, non-progressive enlargement of the cornea, which maintains transparency; a hereditary disorder, mostly with an X-linked recessive inheritance; and lack of any evidence of glaucoma (10,11).

Anterior megalophthalmos is very similar to megalocornea, but these eyes also show enlargement of the lens-iris diaphragm and ciliary ring, in addition to corneal abnormalities (1-4). The differentiation between isolated megalocornea and anterior megalophthalmos is not a straightforward task, and many authors have reported on megalocornea cases that were actually anterior megalophthalmos cases (17, 20, 22, 25, 26, 31, 35).

Megalocornea and anterior megalophthalmos can be differentiated from congenital glaucoma by the transparency of the cornea. Both conditions have a normal endothelial cell count and morphology (13, 28), whereas congenital glaucoma presents with polymegathism, pleomorphism, and decreased cell density (30). In anterior megalophthalmos, the intraocular pressure and optic nerve are normal. Congenital glaucoma is usually progressive and asymmetric and symptoms such as photophobia and tearing frequently occur, along with the characteristic sign of single or multiple horizontal or radial ruptures in Descemet's membrane (i.e., Haab's striae) (10). In congenital or infantile glaucoma, the axial length is elongated mostly because of the expansion of the posterior segment; in megalocornea and megalophthalmos, the axial length is normal and only the anterior segment of the eye is enlarged (10, 12).

Another condition that must be distinguished from anterior megalophthalmos is keratoglobus. Keratoglobus is a corneal ectasis that, like megalocornea and megalophthalmos, causes bilateral bulging globoid corneas. However, unlike megalocornea and megalophthalmos in which the corneas have a normal curvature (14-29) and normal or mildly decreased thickness (15, 16, 20, 22, 23), the corneas in keratoglobus are remarkably thin and the enlargement of the corneal diameter is small (10). Only two cases of anterior megalophthalmos have been described with significant corneal thinning (22, 24).



Table 1. Differential Diagnosis of Megalocornea (10)

FEATURE	CONGENITAL GLAUCOMA	MEGALOCORNEA/MEGALOPHTHALMOS	KERATOGLOBUS
Onset	Congenital or Infantile	Congenital	Congenital
Inheritance	Recessive	Usually X-linked	Recessive
Bilaterality	Assymetrical	Possible assymetrical	Bilateral
Corneal Thickness	Variable	Moderately thin	Very thin
Corneal Diameter	Progressive enlargement	Large and stable (> 13 mm)	Normal or slightly enlarged
Anterior Chamber	Deep	Very deep	Deep or very deep
Iris Transillumination	Absent	Frequently present	Absent
Posterior Iris Bowing	Minimal	Frequent and pronounced	Absent
Pigment Dispersion	Absent	Frequent	Absent
Corneal Curvature	Around normal	Around normal	Very steep
Refraction	Myopia variable	Variable, usually low refractive errors, but may range from high hyperopia to high myopia.	High myopia
Gonioscopy	Abnormal	Band broadening of the ciliary body and excessive mesenchymal tissue	Iris processes
Systemic Associations	Sturge-Weber, other pediatric syndromes	Marfan, Alport, Down, Mucopolidosis tipo II, pontocerebellar hypoplasia, Walker Warburg syndrome (rarely)	Ehlers-Danlos, Rubinstein-Taybi syndrome

CATARACT SURGERY IN ANTERIOR MEGALOPHTHALMOS

Some challenges of cataract surgery for patients with anterior megalophthalmos are the extremely deep anterior chamber, which may make visualization difficult and surgical maneuvers more challenging; all landmarks and dimensions are abnormal, which can make estimating the capsulorhexis size difficult; and zonular anomalies and a large capsular bag can lead to complications such as posterior capsule rupture and vitreous loss. In addition, intraocular lens (IOL)

decentration related to the oversized capsular bag is common (14, 15, 19, 20, 25, 26, 29, 31-33). In reviewing the literature from 1984 to date, we found 30 patients (representing 51 eyes) who had anterior megalophthalmos and underwent cataract surgery (Table 2). We chose not to include reports of cases before that year because of the important differences in surgical techniques, compared to "modern" cataract surgery. Different approaches have been used to avoid IOL instability such as leaving patients aphakic; using contact lenses or aphakic glasses for visual rehabilitation (29); secondary sutured IOL implantation (29); large custom-made IOLs, which are an excellent alternative but are not



commercially available, can be difficult to obtain, and are expensive (23); phacoemulsification with anterior optic capture of a three-piece IOL (34); and IOL suturing

techniques (15, 16, 25, 26, 29, 32, 35). Iris-sutured IOLs may become loose in eyes with anterior megalophthalmos (25).

Table 2. Reported Cases of Cataract Surgery and IOL Implantation in eyes with Anterior Megalophthalmos (1984–2014)

Author, Year	Case/Eye	Surgical Technique/IOL
Neumann, 1984	Case 1:OU (Neumann, 1984)	First eye: ECCE + IOL in sulcus: decentration. It was removed and a Medallion IOL sutured to iris. In the fellow eye: Medallion IOL sutured to iris.
	Case 2 :One eye (Neumann, 1984)	One eye: ECCE + Medallion IOL sutured to iris
Kwitko, 1991	Case 1:OU (Kwitko, 1991)	OD: ECCE + IOL (14 mm) in sulcus. 6 ms POP: mild inferior decentration. 1 yr POP: Retinal detachment. OS: ECCE + IOL (14 mm) in sulcus. 1 yr POP: mild superior decentration. 18 ms POP: Retinal detachment. Following retinopexy, IOL subluxation.
	Case 2: OD (Kwitko, 1991)	OD: ECCE + IOL (18 mm). Good evolution.
Dua, 1999	Case 1: OU (Dua, 1999)	OU: ECCE + IOL sutured to iris and anterior capsule.
Javadi, 2000	Case 1: OU (Javadi, 2000)	OU: ECCE + standard PMMA IOL in the bag (13.5 mm length, 7.0 mm optic)
	Case 2: OU (Javadi, 2000)	OD: ECCE + standard PMMA IOL (13.5 mm length, 7.0 mm optic) in the bag (can-opener capsulotomy). Decentration. OS: ECCE+ standard PMMA IOL in the bag (13.5 mm length, 7.0 mm optic)
	Case 3: OD (Javadi, 2000)	OD: ECC + LIO. Zonular dialysis, anterior vitrectomy and AC IOL. Significant pseudophacodonesis. Retinal detachment 3 ms POP.
	Case 4: OS (Javadi, 2000)	OS: Phacoemulsification+ standard PMMA IOL (13.5 mm length, 7.0 mm optic) in the bag.
De Sanctis, 2004	Case 1: OU (De Sanctis, 2004)	OD: Phacoemulsification+ foldable IOL (13.0 mm length) + capsular tension ring. Zonular dialysis. Mild superior decentration.
		OS: Phacoemulsification+ foldable IOL (13.0 mm length)
Sharan, 2005	Case 1: OU (Sharan, 2005)	OD: ECCE + aphakia OS: ECCE + aphakia. 10 yrs later secondary implantation: sutured AC IOL
	Case 2: OU (Sharan, 2005)	OD: ECCE + aphakia OS: ECCE + aphakia. 1 yr later secondary implantation standard IOL: decentration. Explantation and iris sutured IOL.
	Case 3: OU (Sharan, 2005)	OS: ECCE + Aphakia. Secondary implantation of custom made PMMA IOL (14 mm length). OD: ECCE + standard PMMA IOL (14 mm length).
Basti, 2005	Case 1: OD (Basti, 2005)	OD: sutured AC IOL. Decentration, instability. Explantation, and implantation of a posterior chamber IOL sutured to iris
Tsai, 2005	Case 1: OD (Tsai, 2005)	OD: Phacoemulsification+ standard PMMA IOL (13.0 mm length, 6.0 mm optic) in the bag



Oetting, 2006	Case 1:OU (Oetting, 2006)	OU: Intracapsular extraction, aphakia. Late secondary implantation (20 yrs POP): iris-claw IOLs in AC. Refixation was required in OD
Lee, 2006	Case 1: OU (Lee, 2006)	OS: Pigmentary glaucoma. Previous trabeculectomy. Phacoemulsification + retropupillary iris-claw IOL OD: Phacoemulsification + retropupillary iris-claw IOL
Vaz, 2007	Case 1: OU (Vaz, 2007)	OU: Phacoemulsification+ custom made IOL (16 mm) in the bag
Berry-Brincat, 2008	Case 1:OU (Berry-Brincat, 2008)	OU: Phacoemulsification+ 3-piece foldable IOL in the bag. Decentration
Assia, 2009	Case 1: OU (Assia, 2009)	OU: Phacoemulsification + 3-piece standard foldable IOL in the bag. OD: scleral wound leak requiring resuturing.
Welder, 2010	Case 1:OU (Welder, 2010)	OU: Iris sutured IOLs. OS: Late instability, explantation and iris-claw IOL in AC.
Zare, 2011	Case 1: OS (Zare, 2011)	OS: Phacoemulsification+ standard three-piece acrylic foldable IOL in the bag
Rekas, 2011	Case 1: OU (Rekas, 2011)	OU: Phacoemulsification+ foldable IOL sutured to a capsular tension ring
Galvis, 2012	Case 1: OU (Galvis, 2012)	OD:Phacoemulsification+retropupillary iris-claw IOL OS:Phacoemulsification+ retropupillary iris-claw IOL *
Hegde, 2012	Case 1: OS (Hegde, 2012)	OS: Phacoemulsification+ standard PMMA IOL (13.5 mm length, 6.5 mm optic) in the bag
Li , 2012	Case 1: OD (Li, 2012)	OD: ECCE + standard IOL in the bag (can-opener capsulotomy). Decentration. Then, haptic suture of the IOL to posterior surface of the iris, anterior capsule and sclera
Wang, 2012	Case 1: OU (Wang, 2012)	OD: ECCE + standard PMMA IOL (13.5 mm length) in the bag. OS: Phacoemulsification+ CTR + standard foldable acrylic four square haptics IOL (10.7 mm length) in the bag. Decentration. Remove IOL, implantation AC iris-claw IOL
	Case 2: OD (Wang, 2012)	OD: ECCE + standard PMMA IOL (13.5 mm length) in the bag. Mild decentration. OS: ECCE + standard PMMA IOL (13.5 mm length) in the bag. Decentration.
	Case 3: OU (Wang, 2012)	OD: EECC + standard PMMA IOL (13.5 mm length) in the bag. Decentration. IOL explantation and implantation AC iris-claw IOL OS: EECC? + standard PMMA IOL (13.5 mm length) in the bag. Decentration.
Jain, 2014	Case 1: OU (Jain, 2014)	OU: Phacoemulsification (scleral tunnel) + anterior capsule capture 3-piece IOL

* The patient recently underwent surgery in his left eye at our institution. This eye is not included in the original case report.

Aphakic iris-claw lenses such as the Artisan lens (Ophtec, Groningen, the Netherlands) or Verisyse lens (Abbott Medical Optics Inc., Santa Ana, CA, United States) have also been used in patients with anterior

megalophthalmos by implanting the lens in the anterior chamber (17, 26, 33) or fixing them in the posterior surface of the iris (27, 28).



In some patients with anterior megalophthalmos, a standard rigid polymethyl methacrylate (PMMA) IOL (total length, 13–13.5 mm) has been successfully used (19, 21, 33, 36). Standard multipiece foldable IOLs (18, 22) and single-piece foldable IOLs (20) have also been used. This suggests that enlargement of the capsular bag is not significant in all patients. Zare et al. (18) suggest using preoperative ultrasound biomicroscopy in anterior megalophthalmos to measure the actual size of the capsular bag to help decide whether a standard IOL is suitable. They were able to implant a standard three-piece foldable IOL in a patient with anterior megalophthalmos because ultrasound biomicroscopy revealed that the capsular bag diameter was normal, despite ciliary ring enlargement. However, most patients will present with a significantly enlarged capsular bag, which will cause a standard IOL to be at a high-risk of decentration. Iris-claw IOLs, which are fixated to the anterior stroma of the iris, are a good option in these patients. Fixation of an iris-claw IOL does not depend on the sulcus or on the bag; therefore, it is very useful in these patients when a large capsular bag may be problematic. However, in eyes with severe atrophy of the iris stroma, which was reported by Sharan et al. (29), fixation may be very difficult. Another technique using this type of aphakic IOL (i.e., Artisan lens or Verisyse lens) is fixating it to the posterior surface of the iris, as described in 1994 by Rijneveld et al. (37). This technique only became popular approximately one decade later, after Mohr described it again in 2002 (38). An advantage is that the optics of the IOL is much farther from the endothelium, and the anterior segment architecture is respected. Oetting and Newsom (17) implanted aphakic iris-claw lenses in the anterior chambers of two eyes in late secondary procedures. Wang implanted an iris-claw IOL in the anterior chamber as a secondary procedure in two eyes with a decentered previously implanted IOL: one eye had a foldable IOL and the other eye had a PMMA IOL (33). Welder and Oetting implanted an iris-claw IOL in the anterior chamber as a secondary procedure in a patient with a decentered iris-sutured posterior chamber IOL (26). Lee et al. (27) fixed the lenses retropupillary in two eyes with good results. We also implanted the iris-claw IOL in the posterior surface of the iris in both eyes of one patient (28). Like Lee et al. (27), we employed the posterior chamber fixation technique; however, unlike Lee, we performed the

procedure using topical anesthetic eye drops instead of general anesthesia. Other differences from Lee is that we made a superior incision rather than a temporal incision and we used a spatula rather than enclavation needles for IOL fixation in the posterior surface of the iris through paracentesis incisions formed at the 3 o'clock and 9 o'clock positions (Fig. 2).

We believe that this type of lens, as suggested by other authors (17, 26, 27, 33, Li), is an excellent alternative for patients with cataracts and anterior megalophthalmos because it eliminates the difficulties associated with instability of a lens in the bag or in the anterior chamber; and difficulties related to suturing it to the iris, anterior capsule or sclera, or performing techniques that are more demanding and have the risk of long-term instability. In addition, the retropupillary fixation of the aphakic iris-claw IOL may have the advantage of decreasing the risk of long-term endothelial cell loss.

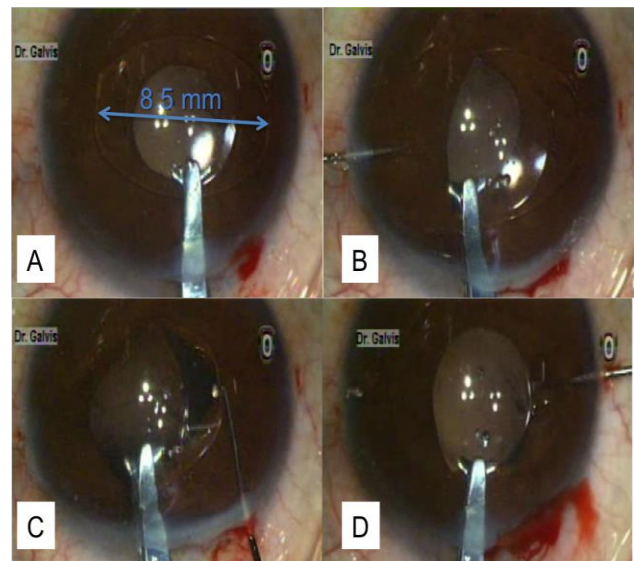


Figure 2. Aphakic Intraocular Lens Fixation with the Iris-claw Lens (Artisan lens; Ophtec, Groningen, the Netherlands)

(A) The intraocular lens (IOL) is already flipped with its anterior surface facing back toward the iris. The IOL length and the large limbus diameter are different. (B) The first haptic is slipped through the pupil, under the iris, and tilted so that the claw haptic raises the iris. A small amount of tissue is pressed back on the claw using a spatula to introduce it through the gap of the haptic. (C) and (D) The same procedure is performed with the second haptic. (Photos are kindly provided by Dr. Virgilio Galvis).



CONCLUSION

Anterior megalophthalmos is characterized by megalocornea associated with a very deep anterior chamber and ciliary ring elongation. Cataract surgery is challenging because of the abnormalities in the anterior segment, especially the enlargement of the capsular bag and abnormalities of the zonules. Several approaches have been developed to date. Measuring the capsular bag diameter with ultrasound biomicroscopy may be useful to determine if the capsular bag is enlarged. In this situation, implantation of a retropupillary aphakic iris-claw IOL can yield excellent anatomic and visual outcomes.

DISCLOSURE

This work did not receive financial support from any source. The authors do not have any interests in the products mentioned in this article.

REFERENCES

1. Wright RE. MEGALOPHTHALMUS AND MICROPHTHALMUS. *Br J Ophthalmol*. 1922 Jan;6(1):35-7. PMID: 18168168
2. Waring III GO, Rodrigues MM. Congenital and neonatal corneal abnormalities. In: Tasman W, Jaeger EA ,eds. *Duane’s Foundations of Clinical Ophthalmology*. Lippincott Williams & Wilkins, Philadelphia, U.S., 1999:2-4.
3. Taylor D. *Paediatric Ophthalmology*, 2nd ed. Oxford, Malden, MA, U.S., 1997: 253–254
4. Trattler WB, Kaiser PK, Friedman NJ. Review of Ophthalmology. 2nd Ed. Elsevier Saunders, Philadelphia, U.S., 2012:102-103
5. Agrawal P, Patel C, Abidi N, Ramchandani S, Vadhel L, Loomba A. Walker Warburg syndrome associated with microphthalmos and megalophthalmos: A rare combination. *Oman J Ophthalmol*. 2013 May;6(2):134-5. PMID: 24082679
6. Duke-Elder S. Anomalies of the size of the cornea: anterior megalophthalmos. In: Duke-Elder S, ed, *System of Ophthalmology*. St. Louis, MO, CV Mosby, 1964; vol. 3, pt 2: Normal and Abnormal Development; Congenital Deformities; 498–505
7. Kuchenbecker J, Behrens-Baumann W. Ciliary body dysplasia in megalophthalmos anterior diagnosed using ultrasound biomicroscopy. *Eye (Lond)*. 2002. Sep;16(5):638-9. PMID: 12194082
8. Ahmadi H, Banaee T, Javadi MA, Jafarinasab MR, Yazdani S, Sajjadi H. Vitreoretinal disorders in anterior megalophthalmos. *Jpn J Ophthalmol*. 2006 Nov-Dec;50(6):515-23. PMID: 17180525
9. Rao A, Videkar C. Hereditary anterior megalophthalmos with posterior vitreoretinopathy: a surgical challenge. *BMJ Case Rep*. 2014 Mar 14;2014.
10. Ho CL, Walton DS. Primary megalocornea: clinical features for differentiation from infantile glaucoma. *J Pediatr Ophthalmol Strabismus*. 2004;41:11-7; quiz 46-7. PMID: 14974829

11. Kraft SP, Judisch GF, Grayson DM. Megalocornea: a clinical and echographic study of an autosomal dominant pedigree. *J Pediatr Ophthalmol Strabismus*. 1984 Sep-Oct;21(5):190-3. PMID: 6389819
12. Meire FM. Megalocornea. Clinical and genetic aspects. *Doc Ophthalmol*. 1994;87:46-52. PMID: 7835180
13. Skuta GL, Sugar J, Ericson ES. Corneal endothelial cell measurements in megalocornea. *Arch Ophthalmol*. 1983; 101:51–53. PMID: 6849653
14. Kwitko S, Belfort Júnior R, Omi CA. Intraocular lens implantation in anterior megalophthalmos. Case report. *Cornea* 1991;10:539–541. PMID: 1782784
15. Neumann AC: Anterior megalophthalmos and intraocular lens implantation. *J Am Intraocul Implant Soc*. 1984;10:220–222. PMID: 6735890
16. Dua HS, Azuara-Blanco A, Pillai CT. Cataract extraction and intraocular lens implantation in anterior megalophthalmos. *J Cataract Refract Surg* 1999;25:716–719. PMID: 10330652
17. Oetting TA, Newsom TH. Bilateral Artisan lens for aphakia and megalocornea: long-term follow-up. *J Cataract Refract Surg* 2006;32:526–528 . PMID: 16631070
18. Zare MA, Eshraghi B, Kiarudi MY, Masoule EA, authors. Application of ultrasound biomicro-scopy in the planning of cataract surgery in anterior megalophthalmos. *Indian J Ophthalmol*. 2011;59:400–2. PMID: 21836354
19. Javadi MA, Jafarinasab MR, Mirdehghan SA. Cataract surgery and intraocular lens implantation in anterior megalophthalmos. *J Cataract Refract Surg*. 2000;26:1687-90. PMID: 11084281
20. de Sanctis U, Grignolo FM. Cataract extraction in X-linked megalocornea: a case report. *Cornea*. 2004;23:533-5. PMID: 15220744
21. Tsai CK, Lai IC, Kuo HK, Teng MC, Fang PC. Anterior megalophthalmos. *Chang Gung Med J*. 2005;28:191-5. PMID: 15945327
22. Assia EI, Segev F, Michaeli A. Cataract surgery in megalocornea Comparison of 2 surgical approaches in a single patient. *J Cataract Refract Surg*. 2009;35:2042-6. PMID: 19969205
23. Vaz FM, Osher RH. Cataract surgery and anterior megalophthalmos: custom intraocular lens and special considerations. *J Cataract Refract Surg*. 2007 Dec;33(12):2147-50. PMID: 18053921
24. Nemeth G, Hassan Z, Berta A, Modis L. Scheimpflug imaging in anterior megalophthalmos. *Indian J Ophthalmol* 2013;61:32-5. PMID: 23275220
25. Basti S, Koch DD: Secondary peripheral iris suture fixation of an acrylic IOL in megalocornea. *J Cataract Refract Surg* 2005;31:7; author reply 8. PMID: 15721672
26. Welder J, Oetting TA: Megalocornea. *EyeRounds.org*. Sept. 16, 2010; available from: <http://www.EyeRounds.org/cases/121-megalocornea.htm>. Accessed September 13, 2014.
27. Lee G, Hann J, Braga-Mele R: Phacoemulsification in anterior megalophthalmos. *J Cataract*. 2006 Jul;32(7):1081-4. PMID: 16857490
28. Galvis V, Tello A, Miotto G, Rangel CM. Artisan aphakic lens for cataract surgery in anterior megalophthalmos. *Case Rep Ophthalmol*. 2012 Sep;3(3):428-33. PMID:23341820
29. Sharan S, Billson FA. Anterior megalophthalmos in a family with 3 female siblings. *J Cataract Refract Surg*. 2005 Jul;31(7):1433-6. PMID: 16105619
30. Mastropasqua L, Carpineto P, Ciancaglini M, Nubile M, Doronzo E. In vivo confocal microscopy in primary congenital glaucoma with megalocornea. *J Glaucoma*. 2002 Apr;11(2):83-9. PMID: 11912354



31. Berry-Brincat A, Chan TK. Megalocornea and bilateral developmental cataracts. *J Cataract Refract Surg.* 2008;34:168-70. PMID: 18165100
32. Li Y, Liu F, Zhang Q, Xiong Y. Cataract surgery and intraocular lens implantation in anterior megalophthalmos. *Int J Ophthalmol.* 2012;5(5):648-9. PMID: 23166881
33. Wang QW, Xu W, Zhu YN, Li JY, Zhang L, Yao K. Misdiagnosis induced intraocular lens dislocation in anterior megalophthalmos. *Chin Med J (Engl).* 2012 Sep;125(17):3180-2. PMID: 22932204
34. Jain AK, Nawani N, Singh R. Phacoemulsification in anterior megalophthalmos: rhexis fixation technique for intraocular lens centration. *Int Ophthalmol.* 2014 Apr;34(2):279-84. PMID: 23700153
35. Rękas M, Pawlik R, Kluś A, Różycki R, Szaflik JP, Ołdak M. Phacoemulsification with corneal astigmatism correction with the use of a toric intraocular lens in a case of megalocornea. *J Cataract Refract Surg.* 2011;37:1546-50. PMID:21782100
36. Hegde V, Jain R, Bappal A. Successful visual rehabilitation in a case of anterior megalophthalmos. *Middle East Afr J Ophthalmol* 2012;19:413-5. PMID: 23248546
37. Rijneveld WJ, Beekhuis WH, Hassman EF, Dellaert MM, Geerards AJ. Iris claw lens: anterior and posterior iris surface fixation in the absence of capsular support during penetrating keratoplasty. *J Refract Corneal Surg.* 1994 Jan-Feb;10(1):14-9. PMID: 7517774
38. Mohr A, Hengerer F, Eckardt C. [Retropupillary fixation of the iris claw lens in aphakia. 1 year outcome of a new implantation technique]. *Ophthalmologe.* 2002 Jul;99(7):580-3. PMID: 12148307