



Simultaneous Therapy with Intravitreal Dexamethasone Implant and Bevacizumab for the Treatment of Macular Edema

Felipe L. de ANDRADE ¹; Flavio S. LOPES ¹; Gabriel C. de ANDRADE ¹; Tiago S. PRATA ²; André MAIA ^{1,2}

1. Retina Clinic, Rua Eloi Cândido Lopes, 291 Centro, Osasco - SP, 06010-130, Brazil

2. Federal University of São Paulo, Rua Sena Madureira, 1500 - Vila Mariana, São Paulo - SP, 04021-001, Brazil

ABSTRACT

To investigate the safety profile and benefits of a short-term simultaneous treatment regimen combining two drugs—an intravitreal implant of dexamethasone with an intravitreal injection of bevacizumab—in patients with macular edema. This was a retrospective, non-randomized, open-label case series study. Patients were treated between April 2014 and July 2015 and were diagnosed with recurrent macular edema secondary to diabetic retinopathy and retinal vein occlusion. They underwent simultaneous treatment with an intravitreal injection of bevacizumab (1.25 mg) and an intravitreal implant of dexamethasone (0.7 mg). Patients were evaluated at baseline and at each subsequent visit with a complete ophthalmological examination and spectral-domain optical coherence tomography (OCT) scans. They were examined 24 hours after the treatment, and then followed up after 30 days and 60 days. Twenty patients (representing 20 eyes) were included in the study. At the time of injection (i.e., baseline), the best-corrected visual acuity (BCVA) was 0.758 ± 0.42 logarithm of the minimum angle of resolution (logMAR). It improved significantly to 0.51 ± 0.33 logMAR at 1 month and to 0.5 ± 0.34 logMAR at 2 months ($P \leq 0.03$). The median baseline central macular thickness (CMT) was $542 \mu\text{m}$ (interquartile range, $466 - 751 \mu\text{m}$). The median CMT decreased significantly to $321 \mu\text{m}$ (interquartile range, $288 - 381 \mu\text{m}$) at 1 month and $310 \mu\text{m}$ (interquartile range, $286 - 354 \mu\text{m}$) at 2 months ($P \leq 0.0002$). The mean intraocular pressure (IOP) increased from 14.9 ± 2.29 mmHg (at baseline) to 16.5 ± 2.99 mmHg ($P = 0.04$) after 2 months. Two (10%) eyes showed cataract progression. There were no other ocular or systemic complications for the duration of this study. Simultaneous therapy combining a dexamethasone implant plus bevacizumab for macular edema may be an attractive treatment regimen with an acceptable safety profile.

KEY WORDS

Bevacizumab, Macular Edema, Retinal Vein Occlusion, Immunosuppression, Dexamethasone

©2016, Med Hypothesis Discov Innov Ophthalmol.

This is an open-access article distributed under the terms of the Creative Commons Attribution Non-Commercial 3.0 License (CC BY-NC 3.0), which allows users to read, copy, distribute and make derivative works for non-commercial purposes from the material, as long as the author of the original work is cited properly.

Correspondence to:

Dr. Felipe L. de Andrade. Retina Clinic, Rua Eloi Cândido Lopes, 291 Centro, Osasco - SP, 06010-130, Brazil, Tel +55 11 3683-0404, Fax: +55 11 3056-000; E-mail: felipe.muinos@retina.com.br



INTRODUCCION

Macular edema (ME) occurs in many ocular pathologies (e.g., diabetic retinopathy and vein occlusion) and causes different degrees of visual impairment. Pathogenesis could be related to inflammatory cytokines (e.g., interleukin-6 and prostaglandin), dysregulation of endothelial tight junction proteins, and increased vascular endothelial growth factor (VEGF) expression (1-5). The expression of inflammatory factors breaks down the blood-retinal barrier, and thereby causes capillary leak, fluid accumulation, and increased macular thickness (3-5). Managing ME may involve laser therapy, intravitreal injections of anti-VEGF agents, or corticosteroid preparations. Several pharmacological treatment regimens have been introduced to treat ME such as intravitreal bevacizumab (Avastin; Genentech, Inc., South San Francisco, CA), ranibizumab (Lucentis; Genentech, Inc.), aflibercept (Eylea; Regeneron, Inc., Tarrytown, NY, USA), and a biodegradable intravitreal implant that slowly releases the corticosteroid dexamethasone (Ozurdex; Allergan, Inc, Irvine, CA) (3, 6). These pharmacological therapies have made it possible to improve vision rather than just stabilize it, and may significantly improve a patient's quality of life (4). Anti-VEGF drugs decrease the concentration of free VEGF, but do not interfere with other proinflammatory molecules that mediate vascular permeability. Corticosteroids block the production of VEGF and other inflammatory mediators (5, 7). The combination of a corticosteroid with anti-VEGF drugs may substantially suppress vascular permeability and consequently decrease macular thickness, improve visual acuity, and increase the interval between injections, compared to the outcomes obtained with either of these medications alone—especially in eyes that present with severe edema (2, 3). The aim of this pilot study was to investigate the safety profile and benefits (i.e., improved visual acuity and decreased macular thickness) of short-term simultaneous treatment with an intravitreal injection of bevacizumab (1.25 mg) and intravitreal dexamethasone implant (0.7 mg) in patients with ME.

MATERIALS AND METHODS

This retrospective case series was a non-randomized, open-label, single-center investigation (Retina Clinic, São Paulo, Brazil). It was approved by the Institutional Review Board of Hospital Oftalmológico de Sorocaba/SP (São Paulo, Brazil) and adhered to the tenets of the Declaration of Helsinki. Study participants were patients older than 18 years who were treated between April 2014 and July 2015, and diagnosed as having recurrent ME secondary to diabetic retinopathy and retinal vein occlusion. They underwent simultaneous treatment with an intravitreal injection of bevacizumab (Avastin [1.25 mg]; Genentech, South San Francisco, CA) and an intravitreal dexamethasone implant (Ozurdex [0.7 mg]; Allergan, Inc, Irvine, CA). Patients with macular edema had a central macular thickness greater than 300 μm , based on spectral-domain optical coherence tomography (OCT). For this study, a variation greater than 6 mmHg in intraocular pressure (IOP) was considered abnormal. Key exclusion criteria were previous treatment with intravitreal anti-VEGF within 6 weeks and previous treatment with laser or intravitreal corticosteroids within 3 months of study entry.

Patients were evaluated at baseline and at each subsequent visit with best-corrected Snellen visual acuity (BCVA) evaluation, slit-lamp examination, gonioscopy, indirect examination, intraocular pressure (IOP) measurement (Goldmann applanation tonometry), and spectral-domain OCT (Zeiss Cirrus, Dublin, CA).

The procedure was performed in an operating room under sterile conditions. Two minutes before the injections, the patient received an initial drop of proparacaine (0.5%) onto the study eye, followed by 5% povidone-iodine solution. The eyelid margins, the eyelids and the periocular skin were then washed with povidone-iodine. The eye was draped in a sterile manner. A sterile lid speculum was inserted by the surgeon. A subconjunctival bleb of anesthesia was created by injecting 0.4 mL of lidocaine (1%) in the superior temporal quadrant. A caliper was used to mark the injection site 3.5 mm from the limbus in pseudophakic eyes and 4.0 mm in phakic eyes. A dexamethasone



implant (0.7 mg) was injected intravitreally, followed by bevacizumab (1.25 mg) in the superior temporal quadrant. Immediately after the injections, the patient's visual acuity was tested to prevent visual loss due to increased IOP spikes. For 5 days after the procedure, patients used topical antibiotics (e.g., moxifloxacin). Twenty-four hours after the procedure, all patients were contacted via phone and questioned about symptoms of eye pain and worsening of visual acuity. They were then reevaluated after 30 days and after 60 days.

Statistical Analysis

Descriptive analysis was used to present the demographic and clinical data. Data with normal distribution are presented as the mean \pm the standard deviation (SD). Data with non-normal distribution are presented as the median (interquartile range). The independent samples t test was used to compare continuous normally distributed variables (i.e., IOP and visual acuity), whereas the Wilcoxon (signed-rank) test was used to compare non-normally distributed variables (i.e., macular thickness). Each parameter was compared at three time points: baseline (i.e., before treatment), and 30 days and 60 days after intravitreal injection of dexamethasone intravitreal implant and bevacizumab. MedCalc software (MedCalc Inc., Mariakerke, Belgium) was used for computerized statistical analysis. Statistical significance was set at $P < 0.05$.

RESULTS

Twenty patients (representing 20 eyes) with a mean age of 73.4 ± 8.9 years were included in the study. [Table 1](#) presents the patients' baseline characteristics. Before study entry, 11 eyes were pseudophakic, five eyes were phakic, and four eyes had a cataract. At the time of injection (i.e., baseline), the BCVA was 0.758 ± 0.42 logMAR and improved significantly to 0.51 ± 0.33 logMAR at 1 month and to 0.5 ± 0.34 logMAR at 2 months ($P \leq 0.03$).

The median baseline central macular thickness (CMT) was $542 \mu\text{m}$ (interquartile range, $466\text{--}751 \mu\text{m}$). The median CMT decreased significantly to $321 \mu\text{m}$ (interquartile range, $288\text{--}381 \mu\text{m}$) at 1 month and to $310 \mu\text{m}$ (interquartile range, $286\text{--}354 \mu\text{m}$) at 2 months ($P \leq 0.0002$). [Figure 1](#) presents the change in macular

thickness after simultaneous treatment for 2 months. There was one case of ME recurrence after 2 months; the patient was treated with an anti-VEGF injection.

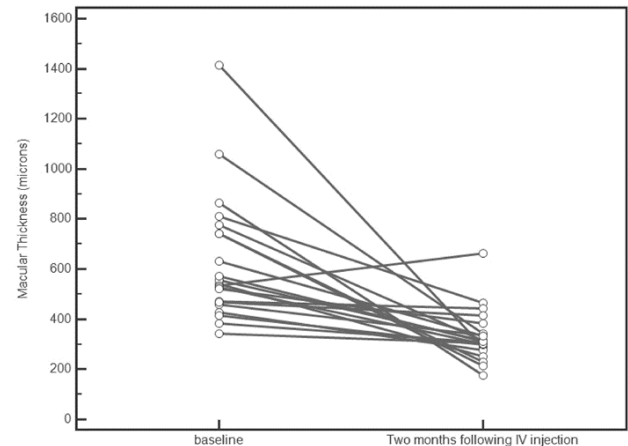


Figure 1. The graph shows the change in macular thickness after simultaneous treatment during 2 months of follow up. IV, intravitreal.

After 2 months, the mean IOP increased from 14.9 ± 2.29 mmHg (at baseline) to 16.5 ± 2.99 mmHg ($P = 0.04$). Two (10%) eyes experienced increased IOP. However, in both patients, the IOP was controlled with two topical anti-glaucoma medications. Deterioration of a pre-existing cataract occurred in 2 (10%) eyes, and 1 patient required cataract surgery. There were no treatment-related cases of iris and angle neovascularization, retinal detachment, vitreous hemorrhage, intraocular lens damage, ocular hypotony, endophthalmitis, or glaucoma surgery.

DISCUSSION

Many investigators have compared the use of an anti-VEGF drug, followed by a low-release implant containing a corticosteroid drug to treat ME with intervals ranging from 2 weeks to 3 months between procedures ([1-3](#)). Few studies have used the concomitant therapy. Our data demonstrated the beneficial effects and the lack of serious adverse effects with this treatment modality. In this study, a simultaneous intravitreal injection of bevacizumab and a dexamethasone implant safely reduced ME and improved visual acuity during a 2-month follow up.



Table 1. Demographic and baseline characteristics, anatomic and functional results, and complications in patients with macular edema treated with a combined therapy

Patient No.	Sex	Age	Diagnosis	Baseline	Month 1	Month 2	Baseline	Month 1	Month 2	Complications
1	F	68	DME	810	517	464	0.7	0.5	0.4	None
2	M	73	DME	460	381	335	1	1	1	Cataract progression
3	M	82	CRVO	1416	296	290	1.3	0.6	0.6	None
4	F	66	DME	427	280	277	0.5	1.3	1.4	Cataract progression
5	M	50	DME	542	244	250	0.6	0.3	0.3	None
6	F	85	BRVO	556	291	313	0.7	0.7	0.7	None
7	M	66	CRVO	741	230	231	1.3	0.2	0.1	None
8	F	73	DME	472	438	433	0.4	0.3	0.3	None
9	F	68	CRVO	344	307	304	1.1	1.1	0.8	None
10	M	70	DME	534	451	664	0.4	0.4	0.7	Increased IOP
11	M	84	DME	382	321	309	0.3	0.3	0.3	None
12	F	81	CRVO	1058	342	344	HM	CF	CF	None
13	F	70	DME	468	410	414	0.3	0.3	0.3	None
14	M	78	CRVO	865	175	176	1.3	0.8	0.8	None
15	M	74	BRVO	776	355	314	0.6	0.3	0.3	None
16	F	80	BRVO	414	312	298	0.4	0.2	0.2	None
17	F	63	BRVO	743	217	214	1.7	0.5	0.4	None
18	M	71	DME	528	308	301	0.6	0.3	0.2	Increased IOP
19	F	87	BRVO	522	384	385	1	0.6	0.6	None
20	F	80	BRVO	572	321	310	0.2	0.1	0.1	None

BCVA: best-corrected visual acuity; BRVO: branch retinal vein occlusion; CF: counting fingers; CMT: central macular thickness; CRVO: central retinal vein occlusion; DME: diabetic macular edema; HM: hand movement; IOP: intraocular pressure; logMAR: logarithm of the minimum angle of resolution.



This study is among the first studies to investigate this treatment regimen. During the first month, the central macular thickness decreased significantly ($P = 0.0001$), and this reduction remained significant at the end of the second month ($P = 0.0002$; [Figure 2](#)). Visual acuity improved significantly after 30 days and 60 days of follow up ($P \leq 0.03$).

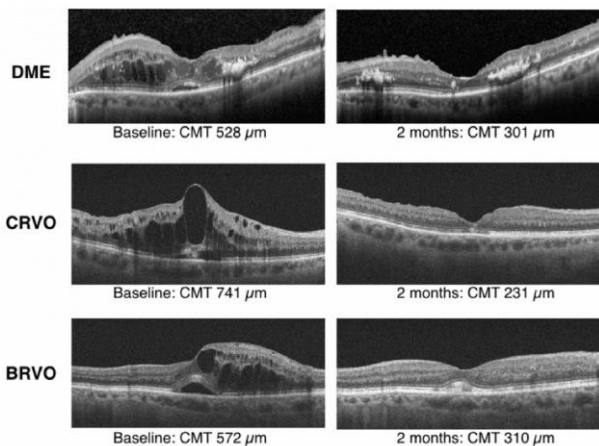


Figure 2. Optical coherence tomography retinal images of representative study eyes with DME, CRVO, and BRVO at baseline and after treatment with dexamethasone implant and bevacizumab. Optical coherence tomography indicates central macular edema. BRVO, branch retinal vein occlusion; CMT, central macular thickness; CRVO, central retinal vein occlusion; DME, diabetic macular edema; OCT, optical coherence tomography.

Our data compares favorably with the data of previous studies. For example, Michael et al. ([2](#)) demonstrated progressive mean visual improvement within 2 weeks in individuals with vein occlusion after they received combined therapy. Raj et al. ([3](#)) showed that 1 month after combined therapy, edema in patients with diabetic ME dramatically improved, and this improvement was sustained for at least 3 months. The increase in IOP after 2 months was significant ($P = 0.04$); however, we believe that the mean elevation of IOP (1.6 mmHg) could be attributed to variations in measurements without clinical impact. The increase in IOP in our patients may not have increased, as described in other studies ([8-13](#)), because

of the limited follow up period of our investigation. Many patients who have barriers to a monthly follow-up regimen or who have disease recurrence may become a significant burden. For these patients, simultaneous treatment may result in a fewer number of procedures and may be more beneficial and comfortable ([14](#)). In the present series, the concomitant therapy was well tolerated.

A limitation of our study is that it was retrospective, nonrandomized, and uncontrolled. The follow up lasted only 2 months; therefore, it was impossible to estimate the long-term efficacy and safety of the dexamethasone implant and the need for reinjection. In addition, because of the lack of a control group, we cannot rule out the possibility that the reduction in the macular thickness may be associated with better systemic control, especially in patients with diabetic ME. It is possible that the low rate of the progression of cataracts could be related to the short follow-up period and reduced number of injections. In summary, simultaneous therapy of dexamethasone implant and bevacizumab for macular edema may be an attractive treatment regimen with an acceptable safety profile. Further trials are indicated to better define the long-term efficacy and adverse effects of this regimen.

DISCLOSURE

Conflicts of Interest: None declared.

No funding or sponsorship was received for this study. All the aforementioned authors met the International Committee of Medical Journal Editors (ICMJE) criteria for authorship for this manuscript, take responsibility for the integrity of the work as a whole, and have provided approval for the revised manuscript to be published.

REFERENCES

1. Mayer WJ, Remy M, Wolf A, Kook D, Kampik A, Ulbig M, et al. Comparison of intravitreal bevacizumab upload followed by a dexamethasone implant versus dexamethasone implant monotherapy for retinal vein occlusion with macular edema. *Ophthalmologica*. 2012;228(2):110-6. [PMID: 22739239](#)
2. Singer MA, Bell DJ, Woods P, Pollard J, Boord T, Herro A, et al. Effect of combination therapy with bevacizumab and dexamethasone intravitreal implant in patients with retinal vein occlusion. *Retina*. 2012;32(7):1289-94. [PMID: 22466480](#)
3. Maturi RK, Bleau L, Saunders J, Mubasher M, Stewart MW. A 12-Month, Single-Masked, Randomized Controlled Study of Eyes with Persistent Diabetic Macular Edema after Multiple Anti-Vegf Injections to Assess the Efficacy of the Dexamethasone-Delayed Delivery System as an Adjunct to Bevacizumab Compared with Continued Bevacizumab Monotherapy. *Retina*. 2015;35(8):1604-14. [PMID: 25829346](#)
4. Mehta H, Gillies M, Fraser-Bell S. Perspective on the role of Ozurdex (dexamethasone intravitreal implant) in the management of diabetic macular oedema. *Ther Adv Chronic Dis*. 2015;6(5):234-45. [PMID: 26336592](#)
5. Boyer DS, Yoon YH, Belfort R, Jr., Bandello F, Maturi RK, Augustin AJ, et al. Three-year, randomized, sham-controlled trial of dexamethasone intravitreal implant in patients with diabetic macular edema. *Ophthalmology*. 2014;121(10):1904-14. [PMID: 24907062](#)
6. Gado AS, Macky TA. Dexamethasone intravitreal implant versus bevacizumab for central retinal vein occlusion-related macular oedema: a prospective randomized comparison. *Clin Exp Ophthalmol*. 2014;42(7):650-5. [PMID: 24612095](#)
7. Nauck M, Karakiulakis G, Perruchoud AP, Papakonstantinou E, Roth M. Corticosteroids inhibit the expression of the vascular endothelial growth factor gene in human vascular smooth muscle cells. *Eur J Pharmacol*. 1998;341(2-3):309-15. [PMID: 9543253](#)
8. Haller JA, Bandello F, Belfort R, Jr., Blumenkranz MS, Gillies M, Heier J, et al. Dexamethasone intravitreal implant in patients with macular edema related to branch or central retinal vein occlusion twelve-month study results. *Ophthalmology*. 2011;118(12):2453-60. [PMID: 21764136](#)
9. Vakalis N, Echiadis G, Pervena A, Deligiannis I, Kavalarakis E, Giannikakis S, et al. Intravitreal combination of dexamethasone sodium phosphate and bevacizumab in the treatment of exudative AMD. *Sci Rep*. 2015;5:8627. [PMID: 25720826](#)
10. Callanan DG, Gupta S, Boyer DS, Ciulla TA, Singer MA, Kuppermann BD, et al. Dexamethasone intravitreal implant in combination with laser photocoagulation for the treatment of diffuse diabetic macular edema. *Ophthalmology*. 2013;120(9):1843-51. [PMID: 23706947](#)
11. Berger AR, Cruess AF, Altomare F, Chaudhary V, Colleaux K, Greve M, et al. Optimal Treatment of Retinal Vein Occlusion: Canadian Expert Consensus. *Ophthalmologica*. 2015;234(1):6-25. [PMID: 26088287](#)
12. Bhavsar AR, Gooze JM, Jr., Stockdale CR, Bressler NM, Brucker AJ, Elman MJ, et al. Risk of endophthalmitis after intravitreal drug injection when topical antibiotics are not required: the diabetic retinopathy clinical research network laser-ranibizumab-triamcinolone clinical trials. *Arch Ophthalmol*. 2009;127(12):1581-3. [PMID: 20008710](#)
13. Kim MS, Kim JM, Park KH, Choi CY. Asymmetry of diurnal intraocular pressure fluctuation between right and left eyes. *Acta Ophthalmol*. 2011;89(4):352-7. [PMID: 19860773](#)
14. Lam WC, Albani DA, Yoganathan P, Chen JC, Kherani A, Maberley DA, et al. Real-world assessment of intravitreal dexamethasone implant (0.7 mg) in patients with macular edema: the CHROME study. *Clin Ophthalmol*. 2015;9:1255-68. [PMID: 26203215](#)