



Mechanisms of Optical Regression Following Corneal Laser Refractive Surgery: Epithelial and Stromal Responses

Majid MOSHIRFAR ^{1,2}; Jordan D. DESAUTELS ^{2,3}; Brian D. WALKER ⁴; Michael S. MURRI ¹; Orry C. BIRDSONG ²;
Phillip C. HOOPES, Sr ²

1. John A. Moran Eye Center, Department of Ophthalmology and Visual Sciences, University of Utah School of Medicine, 50 North Medical Dr., Salt Lake City, UT 84132, United States
2. HDR Research Center, Hoopes Vision, 11820 S. State Street Suite #200, Draper, UT 84020, United States
3. The Warren Alpert Medical School of Brown University, Providence, RI 02903, United States
4. McGovern Medical School, The University of Texas Health Science Center at Houston, 6431 Fannin St, Houston, TX 77030, United States

ABSTRACT

Laser vision correction is a safe and effective method of reducing spectacle dependence. Photorefractive Keratectomy (PRK), Laser In Situ Keratomileusis (LASIK), and Small-Incision Lenticule Extraction (SMILE) can accurately correct myopia, hyperopia, and astigmatism. Although these procedures are nearing optimization in terms of their ability to produce a desired refractive target, the long term cellular responses of the cornea to these procedures can cause patients to regress from their ideal postoperative refraction. In many cases, refractive regression requires follow up enhancement surgeries, presenting additional risks to patients. Although some risk factors underlying refractive regression have been identified, the exact mechanisms have not been elucidated. It is clear that cellular proliferation events are important mediators of optical regression. This review focused specifically on cellular changes to the corneal epithelium and stroma, which may influence postoperative visual regression following LASIK, PRK, and SMILE procedures.

KEY WORDS

Refractive Surgical Procedures; Photorefractive Keratectomy; Keratomileusis, Laser In Situ; Myopia; Hyperopia; Astigmatism; Epithelium, Corneal

©2018, Med Hypothesis Discov Innov Ophthalmol.

This is an open-access article distributed under the terms of the Creative Commons Attribution Non-Commercial 3.0 License (CC BY-NC 3.0), which allows users to read, copy, distribute and make derivative works for non-commercial purposes from the material, as long as the author of the original work is cited properly.

Correspondence to:

Majid Moshirfar, MD, Medical Director HDR Research Center, Professor, Department of Ophthalmology University of Utah Health Sciences Center, Hoopes Vision, 11820 S. State Street Suite #200, Draper, UT 84020. E-mail: cornea2020@me.com

INTRODUCTION

The corneal epithelium possesses the capacity to smooth over stromal irregularities [1]. As optical coherence tomography (OCT), very-high frequency (VHF) digital ultrasound, and confocal microscopy have gained widespread clinical use, it has been noted that epithelial compensation is a major cause of optical regression after

refractive surgery [2-6]. The corneal stroma also undergoes longitudinal morphological changes in response to excimer laser ablation, which can lead to refractive regression [7-10].



Homeostasis and Profile of the Corneal Epithelium

At birth, the corneal epithelial cells are fully developed [11]. Thickness and shape of the corneal epithelium is regulated by constitutive cellular turnover, eyelid mechanical pressure, and cytokine-based mechanisms [12, 13]. Full thickness replacement of the epithelium occurs every 5 to 7 days via proliferation of Limbal Stem Cells (LSCs) and Basal Epithelia Cells (BECs). The balance of proliferation and desquamation yields a nearly uniform central corneal epithelial profile that averages approximately to 50 μm in thickness [13]. Limbal Epithelial Crypts (LEC) exist between the folds of the palisades of Vogt at the limbo-scleral junction (Fig 1) [14]. The LSCs within LECs undergo asymmetric divisions that produce one identical progeny that remains in the crypt, and a Transiently Amplifying Cell (TAC) that migrates centripetally to become a BEC, and eventually a post-mitotic superficial epithelial cell [15]. Upregulation of LSC proliferation is a necessary precursor to refractive regression related to the epithelium. It has been shown that increased concentrations of cytokines after epithelial disruption, such as Insulin-like Growth Factor (IGF), TGF β , Hepatocyte Growth Factor (HGF), and Keratinocyte Growth Factor (KGF), are mitogenic for LSCs [16].

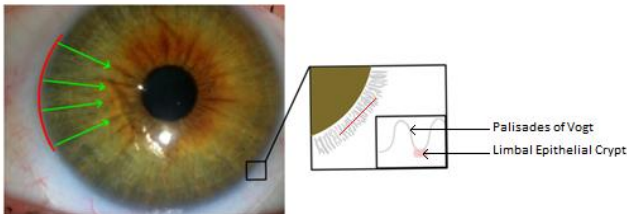


Figure 1: Depiction of the Limbal Epithelial Crypt (LEC) Regions between the Ridges of the Palisades of Vogt are indicated. Limbal Stem Cells Traveling from the LECs originate at the Limbo-Scleral Junction (red border) and move centripetally across the cornea (green arrows). The outset box is a zoomed depiction of the radially oriented palisades with a corresponding cross sectional representation of an LEC between the palisades.

Compensatory Response of the Corneal Epithelium to Myopic Correction

Laser In Situ Keratomileusis, PRK, and SMILE, to correct myopia, involve flattening of the central cornea to decrease the optical power. After these procedures, the epithelium overlying the flattened region undergoes a gradual hyperplasia, which leads to thickening, and often correlates with regression of visual results [2-8, 17-19]. Such hyperplasia may not stabilize for 3 to 6 months

after LASIK [3, 18] and up to 3 years after PRK [8]. Reinstein et al. used VHF ultrasound over a 10-mm corneal zone to show an approximate 6- μm increase in epithelial thickness over the central 7-mm corneal zone 1 year after LASIK for myopia [19]. The largest epithelial response ($\sim 5\mu\text{m}$ of thickening) was observed in the first month, and correlated with a -0.39 D shift in refraction. Nearly identical central epithelial thickening of 5 μm was shown in a 1-month time span after LASIK, on similarly myopic patients, yet it did not show a corresponding change in refraction [4]. In both studies, the epithelial profile took a lenticular form that was thicker centrally and tapered towards the periphery (Fig 2).

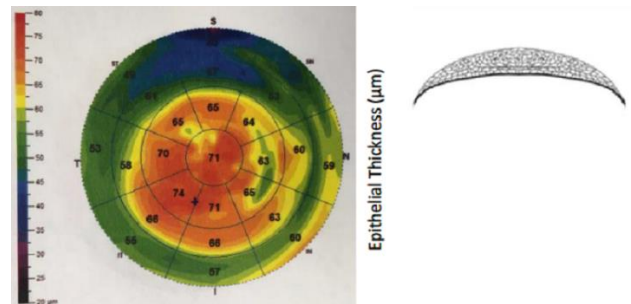


Figure 2: Myopic Epithelial Regression Pattern After Laser In Situ Keratomileusis [Image taken with Avanti™ Comprehensive Widefield OCT by Optovue Inc. (Fremont, CA)].

The figure is a corresponding representation of a cross section of the regressed epithelium over the central 10 mm of the cornea.

An epithelial response to myopic ablation, which is greater in the mid periphery than the center of the cornea ($\sim 5\text{mm}$ zone), may result in a negative meniscus-like epithelial (Fig 3) [3-5].

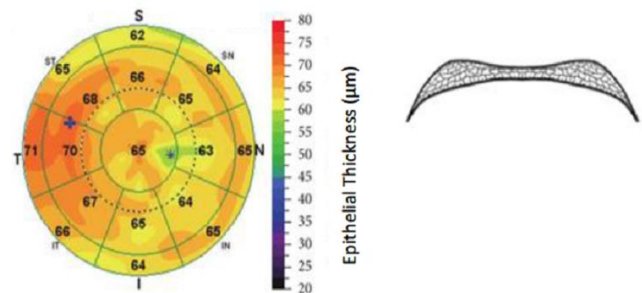


Figure 3: Myopic Epithelial Regression Pattern After Laser In Situ Keratomileusis [Image taken with Avanti™ Comprehensive Widefield OCT by Optovue Inc. (Fremont, CA)].

The figure is a corresponding representation of a cross section of the regressed epithelium over the central 10 mm of the cornea.



A longitudinal study showed that the epithelium thickened by 6 μm , centrally, and by nearly 10 μm in the mid-peripheral region for high myopic LASIK corrections (-8 to -9 D) at one year [3]. For patients with intermediate myopic errors (-3 to -4 D), there was a mean thickening of 1.15 μm centrally, and 3.04 μm mid-peripherally [3]. More thickening mid-peripherally than centrally ($\sim 7\mu\text{m}$ vs $\sim 4\mu\text{m}$) has also been observed 6 months after transepithelial PRK for high myopia (≤ -6 D).⁵ Elevated thickening in the mid-periphery may indicate that the healing epithelium is not simply diffusing into a region of lower concentration, as some mathematical studies have suggested [20], and instead responding to differences in tension [21] or the underlying stromal curvature gradient [22]. Regardless of the pattern of epithelial thickening, the average epithelial thickness over the entire cornea increases with larger corrections [6]. However, the epithelial response is not entirely linear and may be limited by biological constraints for very large corrections. One study showed the central corneal epithelium to be thickened by approximately 7, 9, and 12 μm between 3 and 6 months, postoperatively, for low (-1.00 to -4.00 D), intermediate (-4.25 to -6.00 D), and high (-6.25 to -13.50 D) myopic corrections, respectively [6]. The thickness change per diopter of correction was significantly lower following larger myopic corrections. Similar results have been observed in OCT analyses of epithelial thickness after SMILE [23]. Mean central epithelial thickening near 3, 5, and 7 μm was shown in corneas that underwent SMILE for low (< -4.00 D), intermediate (-4.00 to -6.00 D), and high (> -6.00 to -10.00 D) myopia [23]. This non-linear response showed that epithelial remodeling is responsible for a higher proportion of regression in patients with smaller preoperative refractive errors [6]. The type of refractive surgery also influences the response of the epithelium. In one study, the magnitude of epithelial thickening converged around 36 months for LASIK and PRK, yet the rate of thickening was significantly higher following PRK (Fig 4) [8].

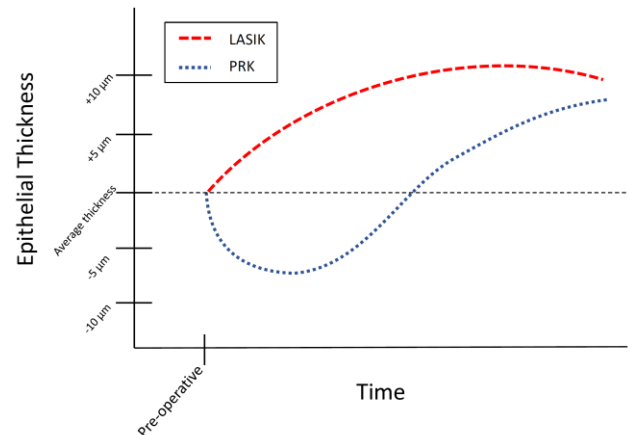


Figure 4: Schematic Graph Depicting Changes in Epithelial Thickness Over Time Following Myopic Laser In Situ Keratomileusis and Photorefractive Keratectomy Procedures.

Differential rates of epithelial thickening between LASIK and PRK are obvious initially, due to the fact that the epithelium regrows following debridement after PRK, yet the post-PRK epithelium undergoes hyperplasia at a higher rate even after re-establishment of preoperative epithelial thickness between 3 and 6 months, postoperatively [8, 19]. This finding is a function of the more aggressive wound healing response seen after PRK due to disruption of the epithelium and basement membrane [24]. It is important to note, some studies have used OCT rather than VHF to evaluate epithelial thickness [3, 5]. Comparative analysis of these modalities showed that they are not directly comparable [25]. A further limitation of these studies is that they did not track visual outcomes during the period of epithelial change, leaving the clinical implication of these epithelial changes unaddressed.

Compensatory Response of the Corneal Epithelium to Hyperopic Correction

Hyperopic ablations to correct farsightedness involve increasing the corneal power by steepening the central corneal curvature. Hyperopic ablations commonly result in worse optical regressions than myopic corrections [26]. Regression from central steepening hyperopic correction is achieved by a peripheral ring of hyperplasia that smooths the corneal surface [18] (Fig 5).

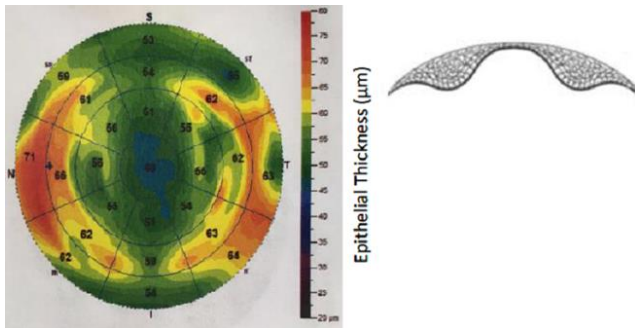


Figure 5: Hyperopic Epithelial Regression Pattern After Laser In Situ Keratomileusis [Image taken with Avanti™ Comprehensive Widefield OCT by Optovue Inc. (Fremont, CA)]

The figure is a corresponding representation of a cross section of the regressed epithelium over the central 10 mm of the cornea.

Very-High Frequency ultrasound studies after hyperopic LASIK have shown larger net corneal epithelial thickness changes than for myopic LASIK [18]. The corneal epithelium became an average of 8 µm thinner, centrally, and 24 µm thicker, peripherally, compared with

preoperative levels in patients with a mean of +3.84 D of hyperopic spherical equivalent after LASIK [18]. One possible explanation for greater response after hyperopic LASIK is that epithelial growth is accelerated by the steeper stromal curvature gradients imparted by hyperopic corrections [22].

Homeostasis and Profile of the Stroma

The corneal stroma is a quiescent connective tissue with a morphology regulated by its biomechanical strength and fluid balance [27]. The stroma occupies 90% of the total corneal volume, and is approximately 500 µm thick at its center [28, 29]. Keratocytes responsible for exuding structural components of the stroma occupy approximately 3% of the total stromal volume [27, 30]. Keratocytes originate from Corneal Stromal Stem Cells (CSSCs) that have known homogeneity with bone marrow mesenchymal stem cells.³¹ Corneal Stromal Stem Cells are most commonly found in the limbal stroma subjacent to the LECs, yet are also found within the central stroma (Fig 6) [27, 31].

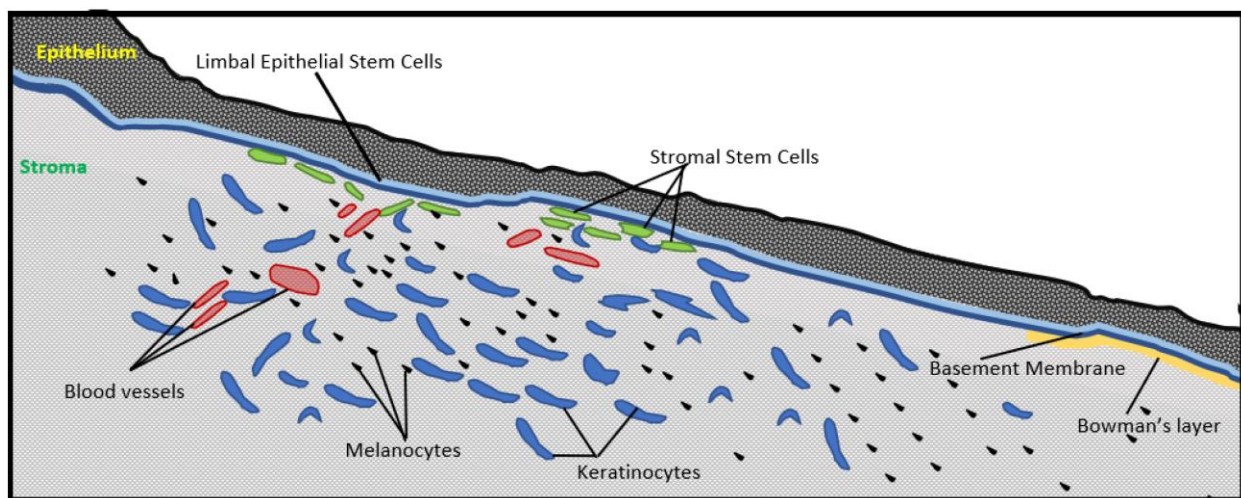


Figure 6: Location of Corneal Stromal Stem Cells (green).

Note the localization of stromal stem cells directly below the limbal epithelial stem cells.

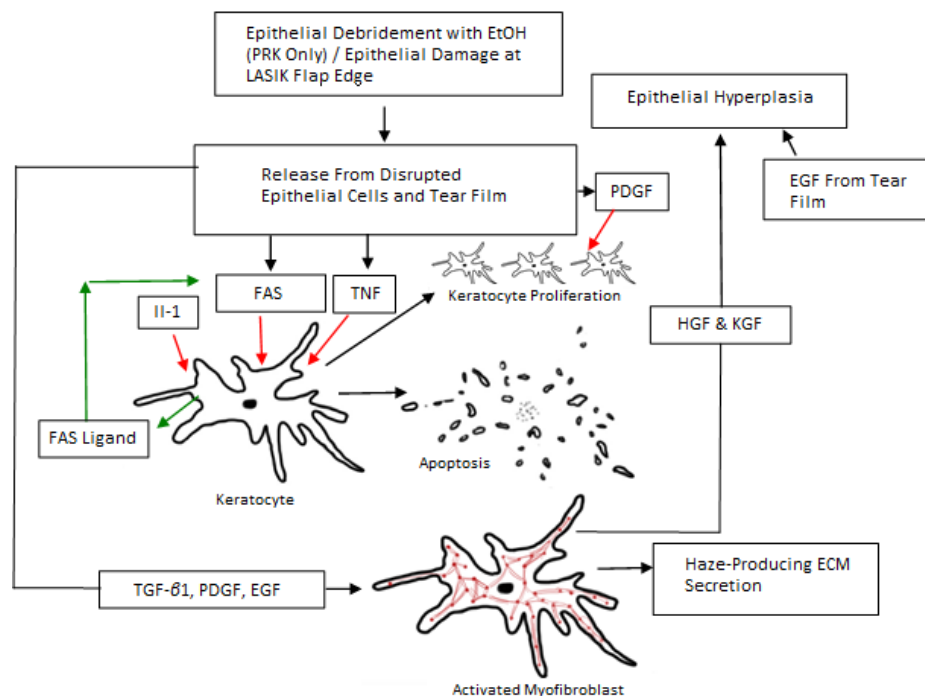


Figure 7: Overview of the Wound Healing Pathways Relevant to Refractive Regression.

Red fibers within the activated myofibroblast represent contractile elements that express smooth muscle actin. [EtOH-Ethanol; PRK-Photorefractive Keratectomy; LASIK-Laser-Assisted In Situ Keratomileusis; PDGF-Platelet Derived Growth Factor; EGF-Epidermal Growth Factor; HGF-Hepatocyte Growth Factor; KGF-Keratinocyte Growth Factor; TNF-Tumor Necrosis Factor; FAS-First Apoptotic Signal; IL-1-INTERLEUKIN 1; TGF-Transforming Growth Factor; ECM-Extracellular Matrix.

Furthermore, CSSCs migrate centrally during stromal wound repair and have the capacity to differentiate to myofibroblasts [31, 32]. They have been shown to improve stromal transparency, increase LASIK flap integrity, and discourage keratocyte to myofibroblast transformation when introduced to sheep corneas that sustained creation of a LASIK flap [33].

Compensatory Response of the Corneal Stroma to Refractive Surgery

Stromal thickness changes follow a biphasic pattern, postoperatively. Early transient fluid swelling elevates the corneal thickness [2]. Fluid swelling then normalizes by approximately the first postoperative week. Without postoperative steroid management, inflammatory processes may prolong the stromal swelling response, resulting in an early transient myopic shift. In the second phase of thickness change, activated stromal keratocytes proliferate and exude Glycosaminoglycans (GAG's), fibrin, and other extracellular matrix components [2, 10]. Ivarsen et al. showed that myopic PRK induces a larger stromal thickening response than LASIK over the first preoperative year ($25.3 \pm 17.2\mu\text{m}$ vs $12.9 \pm 9.4\mu\text{m}$) [8]. The disparity in stromal thickening between LASIK and PRK may be because stromal swelling after LASIK is

confined to the residual stromal bed beneath the flap [8]. Studies have shown LASIK flap thickness to increase significantly between 3 and 9 months of myopic ablation with corresponding visual regression [7]. Epithelial response is likely the predominant contributor to regression after hyperopic corrections. However, studies have shown that PRK patients, who experience hyperopic regressions, have stromal thinning of up to $25\mu\text{m}$, twelve months after surgery [10]. Recent data from hyperopic SMILE has shown less stromal wound healing and inflammatory responses compared to hyperopic LASIK [34].

Role of Corneal Wound Healing Cascades in Visual Regression

Cytokine-mediated wound healing cascades replenish corneal stromal and epithelial cells lost during refractive surgery. Prolonged elevation of cytokine signaling can cause cellular proliferation events to overshoot reestablishment of surface integrity and optical clarity, leading to regression (Fig 7). Corneal wound healing pathways begin with cytokine release from the perturbed ocular surface. Interleukin (IL)-1, IL-6, tumor necrosis factor (TNF)- α [Liu, 2016 #34], Epidermal Growth Factor (EGF), Platelet Derived Growth Factor (PDGF), Platelet



Activating Factor (PAF), Bone Morphogenic Proteins (BMP) 2 and 4, FAS ligand, TGF β , and Insulin-like Growth Factors (IGF) 1 and 2 are harbored within corneal epithelial cells, the basement membrane, and the tear film [16, 35]. Epithelial wounding causes release of these cytokines and elevated expression of their corresponding receptors on surrounding epithelial cells and stromal keratocytes [16]. Surface cytokines passively diffuse to the stroma at a rate dependent on the status of the basement membrane. Stromal exposure to cytokines occurs instantaneously after PRK, due to full thickness debridement of the epithelium and basement membrane. Conversely, procedures, such as LASIK and SMILE, have greater latency of cytokine delivery. Once inside the stroma, the keratocytes nearest to the ablation undergo FAS ligand-mediated apoptosis that is further enhanced by IL-1 binding, TNF, and other surface cytokines [16]. The border of keratocyte apoptosis, abutting areas of corneal tissue removal, may have adapted to prevent viral infiltration of the stroma [16]. Prolonged keratocyte apoptosis may lead to corneal thinning and subsequent shape changes that alter the refractive status of the eye.

Cells that transform to contractile myofibroblasts, primarily in response to TGF β , are beyond the border of apoptotic keratocytes [16]. Inhibiting TGF β controls haze but does not prevent regression [36]. The PDGF and other growth factors also potentiate myofibroblast proliferation and differentiation [37]. The number of transformed keratocytes after refractive surgery correlates with the amount of correction, and is larger after PRK due to basement membrane destruction [24]. These activated keratocytes then produce Hepatocyte Growth Factor (HGF) and Keratinocyte Growth Factor (KGF) that serve as master regulators of epithelial proliferation and migration. Prolonged elevation of HGF and KGF may cause long-term epithelial growth and refractive regression [16, 38]. The EGF levels in the tear film remain elevated up to 1 year after LASIK surgery, and correlate with refractive regression [39]. Activated stromal myofibroblasts also secrete extracellular glycosaminoglycans and disarrayed fibrillar collagens that thicken and opacify the stroma [2]. These secretions alter the refractive index of the stroma, leading to optical changes [40, 41]. Stromal myofibroblasts undergo apoptosis and clearance after epithelial cytokine flow stops due to reconstruction of the basement membrane [16, 24]. Interleukin-1 further enhances myofibroblast apoptosis when its level exceeds that of TGF β [42]. After ablations for higher degrees of myopia, reestablishment of the basement membrane may be delayed, causing

lasting stromal haze and myofibroblast proliferation [43]. The resulting stromal haze diminishes visual acuity and is associated with regression [44]. Prophylactic use of the alkylating agent, Mitomycin C (MMC), has been used during PRK to halt transformations of keratocyte to myofibroblast [24]. Corneal wound healing is further modulated by the severance and regrowth of corneal nerves [45]. Unmyelinated sensory nerve endings are derived from the ophthalmic branch of the trigeminal nerve form a dense whorl-like plexus below the basal layer of epithelial cells [46]. The release of neuropeptides substance p and Calcitonin Gene Related Peptide (CGRP) from corneal nerve endings has been demonstrated to aid in corneal wound healing processes [47]. Epithelial healing follows re-innervation [47]. Therefore, altered re-innervation patterns following refractive surgeries may alter the morphology of the healed cornea and contribute to long-term regression [2, 7].

DISCUSSION

Regression after refractive treatments, such as PRK, LASIK, and SMILE, is not fully understood. Clearly, the process is multifactorial, involving the corneal epithelium, inflammatory cascades, limbal stem cells, and the corneal stroma. Evidence has shown that the corneal epithelium over the flattened region in myopic correction undergoes steady growth in the months and years after surgery. Hyperopic treatments have an even greater amount of regression, potentially due to the steeper gradients used in the periphery for effective treatment. This epithelial response is greater in treatments with larger correction, which may be related to increased cytokine populations, including EGF, IGF, TGF β , HGF, and KGF, leading to LSC stimulation. The evidence that PRK results in increased epithelial response supports the hypothesis that disruption of the epithelium and basement membrane leads to increased keratinocyte stimulation and a more aggressive wound response [24]. Similarly, with SMILE and LASIK, epithelial response plays a role in regression. In addition, stromal biomechanics may play an integral role in regression. Because of the biomechanical forces based in the collagen stromal network, instantaneous subtraction of this tissue may lead to unwanted changes, even with the decreased epithelial disruption compared to PRK. Because of the inability of stromal keratinocytes to reconstruct the extracellular collagen matrix, the cornea experiences great changes in its shape and tensile strength. With removal of stromal tissue, the posterior cornea, which is less rigid [48, 49], may actually become steeper in some treatments designed to flatten the cornea, leading to a



visual regression. This may be related to downward thickening of the peripheral cornea, reduced residual bed thickness, or a combination of the two [50, 51]. In future studies, research on the exact role of the epithelial response and stromal biomechanics in regression is warranted.

The overall positive benefits of laser refractive procedures heavily outweigh the negative associations with visual regression. For example, younger patients with mild to moderate myopic errors may never experience regression significant enough to warrant enhancement. Nevertheless, regression after refractive surgery remains a limiting factor to the long-term effectiveness of these procedures, especially in patients with large refractive errors or hyperopia. For most patients in developed countries, the prospect of a re-enhancement procedure or possibly returning to glasses generally does not prevent undergoing LASIK, PRK, or SMILE. In less developed regions, however, refractive errors cause significant productivity loss. These refractive errors could possibly be best addressed by humanitarian delivery of laser refractive surgeries due to the difficulty of maintaining a functioning pair of glasses over the long term. The adoption and success of such humanitarian options may be limited if the laser correction cannot be regarded as longitudinally stable. Currently, there are no modalities or pharmacological agents that can effectively

prevent refractive regression in all patients. Ultimately, refractive regression is a multifactorial process that can vary between individuals, and future efforts towards its prevention should be directed at developing a more complete view of the risk factors and mechanisms of the said regression.

ACKNOWLEDGEMENTS

This study was funded by an unrestricted Grant from the Research to Prevent Blindness (RPB), 360 Lexington Avenue, 22nd Floor New York, NY 10017, www.rpbusa.org. All named authors meet the international Committee of Medical Journal Editors (ICMJE) criteria for authorship for this manuscript, take responsibility for the integrity of the work, and have given their final approval of the version to be published.

DISCLOSURE

All named authors meet the International Committee of Medical Journal Editors (ICMJE) criteria for authorship for this manuscript, take responsibility for the integrity of the work as a whole, and have given final approval for the version to be published.

REFERENCES

1. Patel S, Marshall J, Fitzke FW, 3rd. Refractive index of the human corneal epithelium and stroma. *J Refract Surg.* 1995;11(2):100-5. [pmid: 7634138](#)
2. Erie JC. Corneal wound healing after photorefractive keratectomy: a 3-year confocal microscopy study. *Trans Am Ophthalmol Soc.* 2003;101:293-333. [pmid: 14971584](#)
3. Kanellopoulos AJ, Asimellis G. Longitudinal postoperative lasik epithelial thickness profile changes in correlation with degree of myopia correction. *J Refract Surg.* 2014;30(3):166-71. [doi: 10.3928/1081597X-20140219-01](#) [pmid: 24576651](#)
4. Wang J, Thomas J, Cox I, Rollins A. Noncontact measurements of central corneal epithelial and flap thickness after laser in situ keratomileusis. *Invest Ophthalmol Vis Sci.* 2004;45(6):1812-6. [pmid: 15161844](#)
5. Hou J, Wang Y, Lei Y, Zheng X, Zhang Y. Corneal Epithelial Remodeling and Its Effect on Corneal Asphericity after Transepithelial Photorefractive Keratectomy for Myopia. *J Ophthalmol.* 2016;2016:8582362. [doi: 10.1155/2016/8582362](#) [pmid: 27672447](#)
6. Reinstein DZ, Srivannaboon S, Gobbe M, Archer TJ, Silverman RH, Sutton H, et al. Epithelial thickness profile changes induced by myopic LASIK as measured by Artemis very high-frequency digital ultrasound. *J Refract Surg.* 2009;25(5):444-50. [pmid: 19507797](#)
7. Rocha KM, Krueger RR. Spectral-domain optical coherence tomography epithelial and flap thickness mapping in femtosecond laser-assisted in situ keratomileusis. *Am J Ophthalmol.* 2014;158(2):293-301 e1. [doi: 10.1016/j.ajo.2014.04.012](#) [pmid: 24792107](#)
8. Ivarsen A, Fledelius W, Hjortdal JO. Three-year changes in epithelial and stromal thickness after PRK or LASIK for high myopia. *Invest Ophthalmol Vis Sci.* 2009;50(5):2061-6. [doi: 10.1167/iovs.08-2853](#) [pmid: 19151379](#)
9. Chen X, Stojanovic A, Liu Y, Chen Y, Zhou Y, Utheim TP. Postoperative Changes in Corneal Epithelial and Stromal Thickness Profiles After Photorefractive Keratectomy in Treatment of Myopia. *J Refract Surg.* 2015;31(7):446-53. [doi: 10.3928/1081597X-20150623-02](#) [pmid: 26186563](#)
10. Moller-Pedersen T, Cavanagh HD, Petroll WM, Jester JV. Stromal wound healing explains refractive instability and haze development after photorefractive keratectomy: a



- 1-year confocal microscopic study. *Ophthalmology*. 2000;107(7):1235-45. [pmid: 10889092](#)
11. Lwigale PY. Corneal Development: Different Cells from a Common Progenitor. *Prog Mol Biol Transl Sci*. 2015;134:43-59. [doi: 10.1016/bs.pmbts.2015.04.003](#) [pmid: 26310148](#)
12. Thoft RA, Friend J. The X, Y, Z hypothesis of corneal epithelial maintenance. *Invest Ophthalmol Vis Sci*. 1983;24(10):1442-3. [pmid: 6618809](#)
13. Reinstein DZ, Archer TJ, Gobbe M, Silverman RH, Coleman DJ. Epithelial thickness in the normal cornea: three-dimensional display with Artemis very high-frequency digital ultrasound. *J Refract Surg*. 2008;24(6):571-81. [pmid: 18581782](#)
14. Dua HS, Shanmuganathan VA, Powell-Richards AO, Tighe PJ, Joseph A. Limbal epithelial crypts: a novel anatomical structure and a putative limbal stem cell niche. *Br J Ophthalmol*. 2005;89(5):529-32. [doi: 10.1136/bjo.2004.049742](#) [pmid: 15834076](#)
15. Castro-Munozledo F. Review: corneal epithelial stem cells, their niche and wound healing. *Mol Vis*. 2013;19:1600-13. [pmid: 23901244](#)
16. Wilson SE, Mohan RR, Hong JW, Lee JS, Choi R, Mohan RR. The wound healing response after laser in situ keratomileusis and photorefractive keratectomy: elusive control of biological variability and effect on custom laser vision correction. *Arch Ophthalmol*. 2001;119(6):889-96. [pmid: 11405841](#)
17. Ogasawara K, Onodera T. Residual stromal bed thickness correlates with regression of myopia after LASIK. *Clin Ophthalmol*. 2016;10:1977-81. [doi: 10.2147/OPTH.S116498](#) [pmid: 27784987](#)
18. Reinstein DZ, Archer TJ, Gobbe M, Silverman RH, Coleman DJ. Epithelial thickness after hyperopic LASIK: three-dimensional display with Artemis very high-frequency digital ultrasound. *J Refract Surg*. 2010;26(8):555-64. [doi: 10.3928/1081597X-20091105-02](#) [pmid: 19928697](#)
19. Reinstein DZ, Archer TJ, Gobbe M. Change in epithelial thickness profile 24 hours and longitudinally for 1 year after myopic LASIK: three-dimensional display with Artemis very high-frequency digital ultrasound. *J Refract Surg*. 2012;28(3):195-201. [doi: 10.3928/1081597X-20120127-02](#) [pmid: 22301100](#)
20. Huang D, Tang M, Shekhar R. Mathematical model of corneal surface smoothing after laser refractive surgery. *Am J Ophthalmol*. 2003;135(3):267-78. [pmid: 12614741](#)
21. Dierick HG, Missotten L. Is the corneal contour influenced by a tension in the superficial epithelial cells? A new hypothesis. *Refract Corneal Surg*. 1992;8(1):54-9; discussion 60. [pmid: 1554640](#)
22. Reinstein DZ, Archer TJ, Gobbe M. Rate of change of curvature of the corneal stromal surface drives epithelial compensatory changes and remodeling. *J Refract Surg*. 2014;30(12):799-802. [doi: 10.3928/1081597X-20141113-02](#) [pmid: 25437477](#)
23. Ganesh S, Brar S, Relekar KJ. Epithelial Thickness Profile Changes Following Small Incision Refractive Lenticule Extraction (SMILE) for Myopia and Myopic Astigmatism. *J Refract Surg*. 2016;32(7):473-82. [doi: 10.3928/1081597X-20160512-01](#) [pmid: 27400079](#)
24. Santhiago MR, Netto MV, Wilson SE. Mitomycin C: biological effects and use in refractive surgery. *Cornea*. 2012;31(3):311-21. [doi: 10.1097/ICO.0b013e31821e429d](#) [pmid: 22157595](#)
25. Reinstein DZ, Gobbe M, Archer TJ, Silverman RH, Coleman DJ. Epithelial, stromal, and total corneal thickness in keratoconus: three-dimensional display with artemis very-high frequency digital ultrasound. *J Refract Surg*. 2010;26(4):259-71. [doi: 10.3928/1081597X-20100218-01](#) [pmid: 20415322](#)
26. Plaza-Puche AB, Yebana P, Arba-Mosquera S, Alio JL. Three-Year Follow-up of Hyperopic LASIK Using a 500-Hz Excimer Laser System. *J Refract Surg*. 2015;31(10):674-82. [doi: 10.3928/1081597X-20150928-06](#) [pmid: 26469075](#)
27. Pinnamaneni N, Funderburgh JL. Concise review: Stem cells in the corneal stroma. *Stem Cells*. 2012;30(6):1059-63. [doi: 10.1002/stem.1100](#) [pmid: 22489057](#)
28. Patel S, McLaren J, Hodge D, Bourne W. Normal human keratocyte density and corneal thickness measurement by using confocal microscopy in vivo. *Invest Ophthalmol Vis Sci*. 2001;42(2):333-9. [pmid: 11157863](#)
29. Reinstein DZ, Archer TJ, Gobbe M, Silverman RH, Coleman DJ. Stromal thickness in the normal cornea: three-dimensional display with artemis very high-frequency digital ultrasound. *J Refract Surg*. 2009;25(9):776-86. [doi: 10.3928/1081597X-20090813-04](#) [pmid: 19772263](#)
30. Zieske JD, Guimaraes SR, Hutcheon AE. Kinetics of keratocyte proliferation in response to epithelial debridement. *Exp Eye Res*. 2001;72(1):33-9. [doi: 10.1006/exer.2000.0926](#) [pmid: 11133180](#)
31. Vereb Z, Poliska S, Albert R, Olstad OK, Boratko A, Csontos C, et al. Role of Human Corneal Stroma-Derived Mesenchymal-Like Stem Cells in Corneal Immunity and Wound Healing. *Sci Rep*. 2016;6:26227. [doi: 10.1038/srep26227](#) [pmid: 27195722](#)
32. Barbosa FL, Chaurasia SS, Cutler A, Asosingh K, Kaur H, de Medeiros FW, et al. Corneal myofibroblast generation from bone marrow-derived cells. *Exp Eye Res*. 2010;91(1):92-6. [doi: 10.1016/j.exer.2010.04.007](#) [pmid: 20417632](#)



33. Morgan SR, Dooley EP, Kamma-Lorger C, Funderburgh JL, Funderburgh ML, Meek KM. Early wound healing of laser in situ keratomileusis-like flaps after treatment with human corneal stromal stem cells. *J Cataract Refract Surg.* 2016;42(2):302-9. doi: [10.1016/j.jcrs.2015.09.023](https://doi.org/10.1016/j.jcrs.2015.09.023) pmid: 27026456
34. Liu YC, Ang HP, Teo EP, Lwin NC, Yam GH, Mehta JS. Wound healing profiles of hyperopic-small incision lenticule extraction (SMILE). *Sci Rep.* 2016;6:29802. doi: [10.1038/srep29802](https://doi.org/10.1038/srep29802) pmid: 27418330
35. Maycock NJ, Marshall J. Genomics of corneal wound healing: a review of the literature. *Acta Ophthalmol.* 2014;92(3):e170-84. doi: [10.1111/aos.12227](https://doi.org/10.1111/aos.12227) pmid: 23819758
36. Moller-Pedersen T, Cavanagh HD, Petroll WM, Jester JV. Neutralizing antibody to TGFbeta modulates stromal fibrosis but not regression of photoablative effect following PRK. *Curr Eye Res.* 1998;17(7):736-47. pmid: 9678420
37. Kim WJ, Mohan RR, Mohan RR, Wilson SE. Effect of PDGF, IL-1alpha, and BMP2/4 on corneal fibroblast chemotaxis: expression of the platelet-derived growth factor system in the cornea. *Invest Ophthalmol Vis Sci.* 1999;40(7):1364-72. pmid: 10359318
38. Wilson SE, Chen L, Mohan RR, Liang Q, Liu J. Expression of HGF, KGF, EGF and receptor messenger RNAs following corneal epithelial wounding. *Exp Eye Res.* 1999;68(4):377-97. doi: [10.1006/exer.1998.0603](https://doi.org/10.1006/exer.1998.0603) pmid: 10192796
39. Gonzalez-Perez J, Villa-Collar C, Gonzalez-Mejome JM, Porta NG, Parafita MA. Long-term changes in corneal structure and tear inflammatory mediators after orthokeratology and LASIK. *Invest Ophthalmol Vis Sci.* 2012;53(9):5301-11. doi: [10.1167/iovs.11-9155](https://doi.org/10.1167/iovs.11-9155) pmid: 22789928
40. Gardner SJ, White N, Albon J, Knupp C, Kamma-Lorger CS, Meek KM. Measuring the Refractive Index of Bovine Corneal Stromal Cells Using Quantitative Phase Imaging. *Biophys J.* 2015;109(8):1592-9. doi: [10.1016/j.bpj.2015.08.046](https://doi.org/10.1016/j.bpj.2015.08.046) pmid: 26488650
41. Patel S, Alio JL, Perez-Santonja JJ. Refractive index change in bovine and human corneal stroma before and after lasik: a study of untreated and re-treated corneas implicating stromal hydration. *Invest Ophthalmol Vis Sci.* 2004;45(10):3523-30. doi: [10.1167/iovs.04-0179](https://doi.org/10.1167/iovs.04-0179) pmid: 15452058
42. Weng J, Mohan RR, Li Q, Wilson SE. IL-1 upregulates keratinocyte growth factor and hepatocyte growth factor mRNA and protein production by cultured stromal fibroblast cells: interleukin-1 beta expression in the cornea. *Cornea.* 1997;16(4):465-71. pmid: 9220246
43. Torricelli AA, Singh V, Santhiago MR, Wilson SE. The corneal epithelial basement membrane: structure, function, and disease. *Invest Ophthalmol Vis Sci.* 2013;54(9):6390-400. doi: [10.1167/iovs.13-12547](https://doi.org/10.1167/iovs.13-12547) pmid: 24078382
44. Marino GK, Santhiago MR, Torricelli AA, Santhanam A, Wilson SE. Corneal Molecular and Cellular Biology for the Refractive Surgeon: The Critical Role of the Epithelial Basement Membrane. *J Refract Surg.* 2016;32(2):118-25. doi: [10.3928/1081597X-20160105-02](https://doi.org/10.3928/1081597X-20160105-02) pmid: 26856429
45. Tomas-Juan J, Murueta-Goyena Larranaga A, Hanneken L. Corneal Regeneration After Photorefractive Keratectomy: A Review. *J Optom.* 2015;8(3):149-69. doi: [10.1016/j.optom.2014.09.001](https://doi.org/10.1016/j.optom.2014.09.001) pmid: 25444646
46. Patel DV, McGhee CN. Mapping of the normal human corneal sub-Basal nerve plexus by in vivo laser scanning confocal microscopy. *Invest Ophthalmol Vis Sci.* 2005;46(12):4485-8. doi: [10.1167/iovs.05-0794](https://doi.org/10.1167/iovs.05-0794) pmid: 16303938
47. Yang L, Di G, Qi X, Qu M, Wang Y, Duan H, et al. Substance P promotes diabetic corneal epithelial wound healing through molecular mechanisms mediated via the neurokinin-1 receptor. *Diabetes.* 2014;63(12):4262-74. doi: [10.2337/db14-0163](https://doi.org/10.2337/db14-0163) pmid: 25008176
48. Randleman JB, Dawson DG, Grossniklaus HE, McCarey BE, Edelhauser HF. Depth-dependent cohesive tensile strength in human donor corneas: implications for refractive surgery. *J Refract Surg.* 2008;24(1):S85-9. pmid: 18269156
49. Dias JM, Ziebarth NM. Anterior and posterior corneal stroma elasticity assessed using nanoindentation. *Exp Eye Res.* 2013;115:41-6. doi: [10.1016/j.exer.2013.06.004](https://doi.org/10.1016/j.exer.2013.06.004) pmid: 23800511
50. Smadja D, Santhiago MR, Mello GR, Roberts CJ, Dupps WJ, Jr., Krueger RR. Response of the posterior corneal surface to myopic laser in situ keratomileusis with different ablation depths. *J Cataract Refract Surg.* 2012;38(7):1222-31. doi: [10.1016/j.jcrs.2012.02.044](https://doi.org/10.1016/j.jcrs.2012.02.044) pmid: 22727291
51. Chan TC, Liu D, Yu M, Jhanji V. Longitudinal evaluation of posterior corneal elevation after laser refractive surgery using swept-source optical coherence tomography. *Ophthalmology.* 2015;122(4):687-92. doi: [10.1016/j.jophtha.2014.10.011](https://doi.org/10.1016/j.jophtha.2014.10.011) pmid: 25487425