



Combined Lateral Rectus Myectomy and Maximal Medial Rectus Resection in Complete Third Cranial Nerve Palsy

Hajar FARVARDIN¹, Majid FARVARDIN¹, Samaneh KOOHESTANI²

¹ Poostchi Ophthalmology Research Center, Shiraz University of Medical Sciences, Shiraz, Iran

² Kerman University of Medical Sciences, Kerman, Iran

ABSTRACT

This study was performed to describe lateral rectus myectomy and maximal medial rectus resection for correction of eye deviation in complete third cranial nerve palsy. A retrospective review of thirteen patients (fourteen eyes) with complete third cranial nerve palsy, who underwent lateral rectus myectomy and maximal medial rectus resection, was performed. These procedures were combined with superior oblique tendon transposition in nine patients with a large angle of exotropia (more than 60 prism diopters [Δ]), or significant hypotropia (more than 5 Δ). Preoperative deviations were exotropia of 50 to 120 Δ in thirteen cases and hypotropia of 5 to 25 Δ in eight cases. Six months after the surgery, eleven patients were within 10 Δ of orthotropia in primary position. Revision surgery was performed for two patients, eight and 18 months after the first operation. Eventually, five patients (38%) achieved orthotropia in the primary position, and seven patients (54%) had < 11 Δ exotropia and < 6 Δ vertical deviation. In conclusion, this procedure can be considered as an acceptable approach for treatment of strabismus in complete third cranial nerve palsy. This procedure is simple and can be easily performed even in very young children.

KEY WORDS

Exotropia; Lateral Rectus Myectomy ; Medial Rectus Resection; Third Cranial Nerve Palsy

©2018, Med Hypothesis Discov Innov Ophthalmol.

This is an open-access article distributed under the terms of the Creative Commons Attribution Non-Commercial 3.0 License (CC BY-NC 3.0), which allows users to read, copy, distribute and make derivative works for non-commercial purposes from the material, as long as the author of the original work is cited properly.

Correspondence to:

Majid Farvardin, MD, Poostchi Ophthalmology Research Center, Shiraz University of Medical Sciences, Zand Avenue, Shiraz, Iran. E-mail: farvardi@sums.ac.ir

How to cite this article: Farvardin H, Farvardin M, Koohestani S. Combined Lateral Rectus Myectomy and Maximal Medial Rectus Resection in Complete Third Cranial Nerve Palsy. *Med Hypothesis Discov Innov Ophthalmol.* 2018 Summer; 7(2): 83-88.

INTRODUCTION

Third cranial nerve palsy may be congenital or acquired. The congenital type is caused by intrauterine insults, birth trauma, or neonatal hypoxia, and acquired cases are mostly due to head injury, neoplasm, aneurysms, and vascular diseases [1]. In complete third cranial nerve palsy, the movements of four of six extraocular muscles are compromised, and only the lateral rectus and

superior oblique muscles remain intact. As a result, there is no active elevation or adduction forces on the globe and the affected eye manifests large exotropia and hypotropia, which is accentuated on adduction. The oculomotor nerve innervates the levator palpebrae muscle and the unopposed tonus of the orbicularis muscle causes upper eyelid ptosis. The parasympathetic



fibers of the pupil are also involved, causing a dilated pupil that is unresponsive to light and a paralysis of accommodation [1-3]. Management of third cranial nerve palsy is one of the most challenging problems in strabismus. Different surgical techniques have been used with varying success rates [4]. Considering the fact that the goal of surgery is adequate alignment in the primary position, this research investigated the efficacy of combined lateral rectus myectomy and maximal medial rectus resection for correction of eye deviation in complete third cranial nerve palsy.

MATERIALS and METHODS

This study was a retrospective review of thirteen patients (fourteen eyes), who had received surgical management for complete third cranial nerve palsy by one of the authors between 2005 and 2015 at a University tertiary referral center, called Khalili Hospital, Shiraz, Iran. Informed consent was obtained from all participants or their parents before surgery. The study was approved by the local Ethics Committee and was compliant with the principles of the Declaration of Helsinki [5]. All patients or their parents were informed that their ocular alignment could be improved only in the primary position. Complete third nerve palsy was defined as presence of blepharoptosis and severe deficiency of adduction, elevation, and depression. Function of the medial rectus muscle was evaluated by the force generation test in cooperative patients. No patient demonstrated clinically apparent medial rectus muscle function. Function of the superior oblique muscle was assessed by evaluating incyclotorsion. All patients had intact lateral rectus and superior oblique muscles. Patients with any other neurological problems, orbital fracture, aberrant regeneration, or previous strabismus surgery were excluded. Ocular deviations were stable over 2 or 3 consecutive visits. Surgery was done at least six months after birth in congenital cases and one year after onset of palsy in traumatic cases. All patients underwent complete ophthalmic examination. Gender, age at surgery, final visual acuity, final cycloplegic refractive error, state of the pupil, fundoscopy, primary, one- and six-month postoperative status, final angle of deviation, and primary and revision surgical procedures were recorded for all patients. Since the deviation was due to complete third cranial nerve palsy, alternate prism cover test could not be used for measuring the angle of deviation. Therefore, Krinsky light reflex test was used instead. Ocular ductions were evaluated pre- and post-operatively. The forced-duction test was performed at the end of the operation. A six-point scale from zero to five, with zero indicating full movement (four, inability to

move the affected eye past the midline; and five, inability to move the affected eye to the midline) was used for evaluation of ductions and forced-duction tests [4, 6, 7]. Presence of diplopia was evaluated in the last visit, using the red filter test. Orbital Computerized Tomography (CT scan) was performed on one of the patients, four years after the operation. A single surgeon performed all of the surgeries under general anesthesia. The surgical procedure was done as described by Sato et al. with minimal modification [8]. The lateral rectus muscle was identified by the limbal approach. It was engaged with a muscle hook and its connections were dissected up to 10 to 12 mm from its insertion. The muscle was grasped with a clamp, 10 to 12 mm from insertion, and its anterior part was excised with scissors, the distal part was cauterized, and left without being sutured to the sclera. The medial rectus was identified by the limbal approach and 9 to 10 mm was resected. In eyes with a very large angle of exotropia (more than 60 prism diopters [Δ]), or significant hypotropia (more than 5 Δ), transposition of superior oblique tendon to a point 2 mm anterior to nasal end of superior rectus insertion (as described by Young et al) was carried out, as a means of exerting adduction forces on the globe or relieving hypotropia [9]. A paired samples T test was used and $P < 0.05$ was considered statistically significant.

RESULTS

The age of patients at the time of surgery ranged from six months to 19 years (mean 6.9 years) and there were eight males and five females. The patients were followed for two to twelve (mean 4.9) years after the first surgery. Nine patients had congenital third cranial nerve palsy and three patients developed third cranial nerve palsy after head injury, one of them was affected bilaterally. All of the patients had low vision in the affected eye due to amblyopia or traumatic optic neuropathy. Diplopia was only documented in two patients (cases number 11 and 12) with traumatic third nerve palsy. The function of the pupil sphincter was assessed and nine eyes had a fixed dilated pupil. Pale optic disc was observed in three eyes with traumatic third cranial nerve palsy. At first surgery, anterior transposition of superior oblique tendon was done in nine eyes. All of the affected eyes had moderate to severe upper eyelid ptosis that was corrected in six of the eyes following strabismus surgery.

Preoperative deviations were exotropia of 50 to 120 Δ in thirteen cases and hypotropia of 5 to 25 Δ in eight cases. In all of the patients, ocular alignment improved after the surgery. Ocular alignment was stable during six months after the operation in all patients, except one with bilateral traumatic palsy. Six months after the surgery,



four patients were orthotropic in primary position. There were seven patients with residual exotropia equal or less than 10 Δ, one patient with 30 Δ of exotropia, and one patient with 15 Δ of esotropia. There were two patients with 5 Δ hypertropia, one patient with 10 Δ hypertropia, and one patient with 5 Δ hypotropia. Two patients had revision surgery during the course of the follow-up. Patient number six, who had 15 Δ esotropia and 10 Δ hypertropia, underwent 6-mm medial rectus recession and superior oblique tenectomy 18 months after the first

surgery, and became orthotropic in the primary position. The patient with bilateral traumatic palsy, who had 30 Δ exotropia, underwent bilateral superior oblique tendon transposition, eight months after the first surgery, and ocular deviation decreased to 15 Δ exotropia. Four years after the operation, orbital CT scan images were obtained in patient number 4 to observe the re-attachments of the sacrificed lateral rectus muscle (Fig 1).

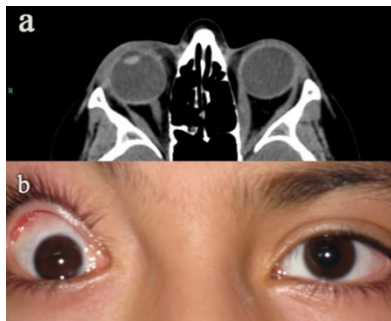


Figure 1: Postoperative Orbital CT Scan and Ocular Alignment of the Patient Number Four (a: The Intentionally Lost Lateral Rectus Muscle attached to the Posterior Aspect of the Globe through Fine Fibrous Tissue. b: Image of the Patient shows Orthotropia in Primary Position)

Table 1: Characteristics of the Patients

N	Age at op	Sex	Eye	BCVA at last exam	Etiology	Pre-op dev, PD	SO surgery	FDT in add, end of op	1 m post-op dev, PD	Post-op abd deficit	6 m post-op dev, PD	Revision surgery	Final dev, PD	F/U
1	6 y	M	OS	20/400	Congenital	70 XT 8 HOT	Yes	Negative	8 XT 5 HT	-4	8 XT 5 HT	No	8 XT 5 HT	2 y
2	2 y	M	OD	20/40	Congenital	80 XT 20 HOT	Yes	Negative	10 XT 5 HOT	-4	10 XT 5 HOT	No	10 XT 5 HOT	11 y
3	13 y	F	OS	20/400	Congenital	100 XT 25 HOT	Yes	Negative	10 XT	-4	10 XT	No	10 XT	2 y
4	6 m	M	OD	20/50	Congenital	70 XT 20 HOT	Yes	Negative	Ortho	-4	Ortho	No	Ortho	12 y
5	3 y	F	OD	20/100	Congenital	60 XT 10 HOT	Yes	Negative	Ortho	-4	Ortho	No	Ortho	4 y
6	1 y	F	OS	20/70	Congenital	70 XT 10 HOT	Yes	Negative	15 ET 10 HT	-5	15 ET, 10 HT	Yes	Ortho	6 y
7	12 y	M	OD	20/100	Congenital	70 XT	Yes	Negative	10 XT	-4	10 XT	No	10 XT	2 y
8	1 y	M	OS	20/200	Congenital	80 XT 5 HOT	Yes	Negative	10 XT	-4	10 XT	No	10 XT	2 y
9	11 y	M	OD	20/40	Congenital	50 XT	No	Negative	Ortho	-4	Ortho	No	Ortho	3 y
10	6 m	F	OS	20/200	Congenital	60 XT	No	Negative	8 XT	-4	8 XT	No	8 XT	3 y
11	19 y	M	OD	20/40	Traumatic	50 XT	No	Negative	Ortho	-4	Ortho	No	Ortho	2 y
12	11 y	F	OD	20/40	Traumatic	100 XT 10 HOT	Yes	Negative	10 XT 5 HT	-4	10 XT 5 HT	No	10 XT 5 HT	10 y
13	10 y	M	OD/OS	20/100 20/100	Traumatic	120 XT	No	-1 /-1	15 XT	-3 /-3	30 XT	Yes	15 XT	5 y

N: Patient Number, M: Male, F: Female, OD: Right Eye, OS: Left Eye, BCVA: Best corrected Visual Acuity, Pre-op: Preoperative, Post-op: Postoperative, PD: Prism Diopters, SO: Superior Oblique Muscle, FDT: Forced-Duction Test, F/U: Duration of Follow-up, XT: Exotropia, ET: Esotropia, HT: Hypertropia, HOT: Hypotropia add: Adduction, abd: Abduction, dev: Deviation, op: Operation, m: Month, y: Years, Ortho: Orthotropia



The intentionally lost muscle was found to be attached to the posterior aspect of the globe through fibrous tissue, thereby, producing no abducting forces. Mean exotropia decreased from $75.4 \pm 20.7 \Delta$ to $6.2 \pm 5.4 \Delta$ ($P = 0.001$) and mean vertical deviation decreased from $8.3 \pm 8.7 \Delta$ to $1.2 \pm 2.2 \Delta$ ($P = 0.002$) at the last follow-up. Eventually, five patients (38%) achieved orthotropia in primary position, and seven patients (54%) had $< 11 \Delta$ exotropia and $< 6 \Delta$ vertical deviation. Characteristics of the patients are provided in [Table 1](#).

DISCUSSION

Surgical management of ocular deviations caused by complete third nerve palsy is challenging, because four of the six extraocular muscles are paralyzed and only the lateral rectus and superior oblique muscles remain functional. Various surgical approaches with different outcomes and complications have been introduced [4]. All of these surgical procedures have two main goals, including maximal weakening of lateral rectus muscle to combat its abducting force, and adding an adducting force to the globe. Large lateral rectus recession, fixation of lateral rectus to orbital periosteum, lateral rectus myectomy, and medial transposition of a split lateral rectus have been used for cancelling the abducting force of the lateral rectus muscle. Large medial rectus resection, superior oblique tendon transposition, fixation of the globe to nasal periosteum, and medial transposition of a split lateral rectus have been used for producing an adducting force. These techniques are discussed below and compared to the author's newly introduced technique. Several studies have shown that severe post-operative abduction deficits and minimal restriction of adduction have major roles in achieving a good and stable result in complete third nerve palsy. Khaier et al. used maximal lateral rectus recession and medial rectus resection combined with adducting traction sutures for treatment of patients with complete third nerve palsy. They stated that severe post-operative limitation of abduction is associated with good results in their cases. Mean final horizontal deviation was 9.7 PD XT in 15 patients with severe post-operative abduction deficit, and 18 PD XT in 16 patients with moderate post-operative abduction deficit [3]. Velez et al. used lateral rectus fixation to periosteum for treatment of three patients with complete third nerve palsy, two of whom had previous surgeries. Final horizontal deviation was orthotropia in two patients with severe (-4) post-operative abduction deficit, and residual 12 PD XT in one patient with mild (-1.5) post-operative abduction deficit [10]. Maximal lateral rectus recession and medial rectus

resection have been used for treatment of complete third nerve palsy by multiple surgeons. Although this approach had relatively good early results, yet the eye will have large amounts of exoshift with time [3, 11]. Köse et al. reported on six patients with complete third nerve palsy, who underwent hemi-hangback recession of the lateral rectus muscle and resection of the medial rectus muscle. Although the procedure was simple and effective, under-corrected exotropia worsened in two patients after two years of follow-up [2]. Noticeable exoshift was observed during six to twelve months in two other studies using maximal lateral rectus recession combined with fixation of globe to nasal periosteum [12, 13]. It seems that residual abducting force of recessed lateral rectus is the cause of this exoshift. Von Noorden stated that even very large (10 to 12 mm) amounts of lateral rectus recession will only limit abduction, moderately [11]. Gokyigit et al. used medial transposition of a split lateral rectus muscle for treatment of ten patients with complete oculomotor nerve palsy. Mean exotropia decreased from 73.7Δ to 7.5Δ , at last follow-up and four of their patients needed reoperation. Two of their patients had pre-operative restriction of adduction during the forced duction test. Although these patients had good results one week after the operation, they developed 20 and 22 PD exoshift in the two-month follow-up, and finally needed reoperation [4]. It seems that contraction of lateral rectus muscle may have some role in this exoshift. In another study for treatment of complete third nerve palsy, Khaier et al. also concluded that eliminating lateral rectus and temporal orbital soft tissue contracture is necessary for achieving good and stable results [3].

Lateral rectus myectomy provides super-maximal weakening of the muscle. This research performed lateral rectus myectomy combined with maximal (9 to 10 mm) medial rectus resection. Twelve of the patients had stable results at the two-year follow-up. All of these twelve patients showed no restriction of adduction at the end of the operation, and had maximal (-4 or -5) abduction deficit after the operation. One patient, who experienced recurrence of exotropia with time, was the only one, who showed mild (-1) restriction of adduction at the end of the operation, and had moderate (-3) abduction deficit after the operation. In complete third cranial nerve palsy, the superior oblique is the only muscle that can provide active adducting forces [9]. In order to achieve better alignment, superior oblique transposition for patients with exotropia greater than 60Δ was performed. Only one case reported combined



lateral rectus myectomy and medial rectus resection for correction of eye deviation in third cranial nerve palsy. In 2000, Sato et al. performed medial rectus resection (10 mm) and lateral rectus myectomy for a case of traumatic complete third nerve palsy with an angle of deviation of 100 Δ. Four months after the initial surgery, the lateral rectus muscle of the fellow eye was also recessed due to residual exotropia. After these operations, the patient was able to fuse in the primary position without any noticeable limitation in abduction and the results remained unchanged for seven months [8]. In contrast to Sato's case report, in this study, a single operation was performed on eleven of thirteen patients. Furthermore, the patients were followed for a longer duration in order to detect any gradual increase in residual exotropia. Outcomes remained stable in eleven of the patients within two to twelve years of follow-up. Young et al. treated eight cases of complete oculomotor palsy by anterior transposition of the superior oblique tendon combined with maximal lateral rectus weakening. Interestingly, in three patients, in which previous lateral rectus recessions had been done, lateral rectus extirpation and myectomy was chosen as the method of lateral rectus weakening. Mean horizontal deviation decreased from 50 Δ to 6 Δ and six cases were aligned within 10 Δ of exotropia or esotropia [9]. Some other studies showed good results with this procedure [14, 15], yet others reported unsatisfactory results due to persistence of exotropia, post-operative hypertropia, limitation of infra-duction, and paradoxical eye movements [16, 17]. Anterior transposition of superior oblique tendon was performed for nine patients. In one of these patients, significant hypertropia required superior oblique tenectomy. More recently, surgeons have attempted to stabilize the globe in the primary position by fixating it to nasal orbital wall or caruncle, using polyester sutures, autologous fascia lata, medial rectus or superior oblique tendons, and periosteal flaps [12, 13, 18-20]. Mean post-operative exotropia was reported as 6.3 to 21 Δ in these studies. These results showed no significant improvement compared to the usual recession/resection or superior oblique anterior transposition surgeries. Besides, these surgeries are technically difficult and fewer surgeons are familiar with these methods. Longer operation time and unfavorable outcomes were two other complications of these techniques [18]. The current study had some shortcomings because of the small number of patients due to low prevalence of the disease, and its non-blind retrospective nature. However, by means of this method, acceptable horizontal and vertical alignment in the

primary position was achieved and the results are comparable with that of more complicated surgeries. The patients were followed-up for a few years and the recurrence of deviations over time was minimal. Only two of the patients needed revision surgery in the course of follow-up. Furthermore, this procedure is simple, and can be easily performed even in very young children.

CONCLUSION

The results suggest that combined lateral rectus myectomy and maximal medial rectus resection can be considered as an acceptable approach for treatment of strabismus in complete third cranial nerve palsy.

DISCLOSURE

Ethical issues have been completely observed by the authors. All named authors meet the International Committee of Medical Journal Editors (ICMJE) criteria for authorship for this manuscript, take responsibility for the integrity of the work as a whole, and have given final approval for the version to be published. No conflict of interest has been presented.

REFERENCES

1. Mazow M. Third cranial nerve palsy: diagnosis and management strategies. In: Rosenbaum A, Santiago A, editors. *Clinical Strabismus Management, Principles and Surgical Techniques*. 1st ed. Philadelphia: WB Saunders Company; 1999. p. 251-8.
2. Kose S, Uretmen O, Pamukcu K. An approach to the surgical management of total oculomotor nerve palsy. *Strabismus*. 2001;9(1):1-8. [pmid: 11262694](#)
3. Khaier A, Dawson E, Lee J. Traction sutures in the management of long-standing third nerve palsy. *Strabismus*. 2008;16(2):77-83. [doi: 10.1080/09273970802077474](#) [pmid: 18484509](#)
4. Gokyigit B, Akar S, Satana B, Demirok A, Yilmaz OF. Medial transposition of a split lateral rectus muscle for complete oculomotor nerve palsy. *J AAPOS*. 2013;17(4):402-10. [doi: 10.1016/j.jaapos.2013.05.007](#) [pmid: 23993720](#)
5. WMA. World Medical Association Declaration of Helsinki-Ethical Principles for Medical Research Involving Human Subjects Fortaleza, Brazil: WMA; 2018 [cited 2013 October]. Available from: <http://www.wma.net/en/30publications/10policies/b317c.pdf>.
6. Rosenbaum A, Santiago A. Test of muscle function. In: Rosenbaum A, editor. *Clinical Strabismus Management: Principles and Surgical Techniques*. 1st ed. Philadelphia: WB Saunders Company; 1999. p. 37-51.
7. Metz HS. Quantitative evaluation of the strabismus patient. *Int Ophthalmol Clin*. 1985;25(4):13-36. [pmid: 4077417](#)



8. Sato M, Maeda M, Ohmura T, Miyazaki Y. Myectomy of lateral rectus muscle for third nerve palsy. *Jpn J Ophthalmol*. 2000;44(5):555-8. doi: [10.1016/s0021-5155\(00\)00212-4](https://doi.org/10.1016/s0021-5155(00)00212-4) pmid: [11033136](https://pubmed.ncbi.nlm.nih.gov/11033136/)
9. Young TL, Conahan BM, Summers CG, Egbert JE. Anterior transposition of the superior oblique tendon in the treatment of oculomotor nerve palsy and its influence on postoperative hypertropia. *J Pediatr Ophthalmol Strabismus*. 2000;37(3):149-55. pmid: [10845415](https://pubmed.ncbi.nlm.nih.gov/10845415/)
10. Velez FG, Thacker N, Britt MT, Alcorn D, Foster RS, Rosenbaum AL. Rectus muscle orbital wall fixation: a reversible profound weakening procedure. *J AAPOS*. 2004;8(5):473-80. doi: [10.1016/S1091853104001314](https://doi.org/10.1016/S1091853104001314) pmid: [15492742](https://pubmed.ncbi.nlm.nih.gov/15492742/)
11. von Noorden G, Campos E. *Paralytic Strabismus. Binocular Vision and Ocular Motility*. 6th ed. St Louis: Mosby; 2002.
12. Sharma P, Gogoi M, Kedar S, Bhola R. Periosteal fixation in third-nerve palsy. *J AAPOS*. 2006;10(4):324-7. doi: [10.1016/j.jaapos.2006.02.005](https://doi.org/10.1016/j.jaapos.2006.02.005) pmid: [16935231](https://pubmed.ncbi.nlm.nih.gov/16935231/)
13. Srivastava KK, Sundaresh K, Vijayalakshmi P. A new surgical technique for ocular fixation in congenital third nerve palsy. *J AAPOS*. 2004;8(4):371-7. doi: [10.1016/S1091853104000400](https://doi.org/10.1016/S1091853104000400) pmid: [15314600](https://pubmed.ncbi.nlm.nih.gov/15314600/)
14. Gottlob I, Reinecke RD, Catalano RA. Surgical Management of Oculomotor Nerve Palsy: Reply. *Am J Ophthalmol*. 1991;111(5):658-9. doi: [10.1016/s0002-9394\(14\)73727-4](https://doi.org/10.1016/s0002-9394(14)73727-4)
15. Yonghong J, Kanxing Z, Wei L, Xiao W, Jinghui W, Fanghua Z. Surgical management of large-angle incomitant strabismus in patients with oculomotor nerve palsy. *J AAPOS*. 2008;12(1):49-53. doi: [10.1016/j.jaapos.2007.07.008](https://doi.org/10.1016/j.jaapos.2007.07.008) pmid: [18029212](https://pubmed.ncbi.nlm.nih.gov/18029212/)
16. Saunders RA, Rogers GL. Superior oblique transposition for third nerve palsy. *Ophthalmology*. 1982;89(4):310-6. doi: [10.1016/s0161-6420\(82\)3478-6](https://doi.org/10.1016/s0161-6420(82)3478-6) pmid: [7099551](https://pubmed.ncbi.nlm.nih.gov/7099551/)
17. Maruo T, Iwashige H, Kubota N, Sakaue T, Ishida T, Honda M, et al. Results of surgery for paralytic exotropia due to oculomotor palsy. *Ophthalmologica*. 1996;210(3):163-7. doi: [10.1159/000310699](https://doi.org/10.1159/000310699) pmid: [8738461](https://pubmed.ncbi.nlm.nih.gov/8738461/)
18. Salazar-Leon JA, Ramirez-Ortiz MA, Salas-Vargas M. The surgical correction of paralytic strabismus using fascia lata. *J Pediatr Ophthalmol Strabismus*. 1998;35(1):27-32. pmid: [9503312](https://pubmed.ncbi.nlm.nih.gov/9503312/)
19. Villasenor Solares J, Riemann BI, Romanelli Zuazo AC, Riemann CD. Ocular fixation to nasal periosteum with a superior oblique tendon in patients with third nerve palsy. *J Pediatr Ophthalmol Strabismus*. 2000;37(5):260-5. pmid: [11020106](https://pubmed.ncbi.nlm.nih.gov/11020106/)
20. Ameri A, Jafari AK, Anvari F, Rezvan J, Fard MA. Simplified use of suture fixation associated with lateral rectus myectomy in management of complete third nerve palsy. *J Pediatr Ophthalmol Strabismus*. 2010;47 Online:e1-3. doi: [10.3928/01913913-20100818-07](https://doi.org/10.3928/01913913-20100818-07) pmid: [21158373](https://pubmed.ncbi.nlm.nih.gov/21158373/)