



A brief review of Valsalva retinopathy

Petros Asteris¹, Dimitrios Kalogeropoulos¹, George Moussa², Ioannis Iraklis Vitos¹, Aikaterini Christodoulou¹ and Chris Kalogeropoulos¹

¹ Department of Ophthalmology, Faculty of Medicine, School of Health Sciences, University of Ioannina, Greece

² Birmingham and Midland Eye Centre, Sandwell and West Birmingham Hospitals NHS Trust, Birmingham, UK

ABSTRACT

Background: Valsalva retinopathy is a specific type of retinopathy that appears following an acute rise in intrathoracic or intra-abdominal pressure. This review focuses on current literature and future directions for the diagnosis and management of Valsalva retinopathy.

Methods: In this brief review, the literature was searched to provide an extensive general and updated description of Valsalva retinopathy, focusing on its management and prognosis. Selected articles are summarized to present the etiology, general pathology, pathophysiology, symptoms, signs, diagnosis, differential diagnosis, treatment, and prognosis of Valsalva retinopathy.

Results: The main symptom of Valsalva retinopathy is loss of visual acuity following exertion. This is caused by the rupture of small superficial vessels in the macula and perimacular areas, leading to extravasation of blood. No link between age, sex, or race has been found, although fundus vessel abnormalities pose some predisposition to the disease. During fundoscopy, Valsalva retinopathy appears most frequently as well-defined preretinal hemorrhages confined to the sub-internal limiting membrane (ILM) or subhyaloid space. If ILM rupture occurs, hyaloid hemorrhage can appear. Diagnosis is based on the patient's medical history and a standard examination. Usually, only observation of the patient is required, with the hemorrhage resolving within weeks to months. In cases of large premacular hemorrhage or large sub-ILM/subhyaloid hemorrhage, vitrectomy or Nd:YAG krypton laser membranotomy can be performed.

Conclusions: Of all the aspects of Valsalva retinopathy that might trouble the physician, the most challenging features are differential diagnosis and the choice of optimal treatment. Therapeutic strategies for Valsalva retinopathy can be either conservative or based on Nd:YAG laser membranotomy and/or vitrectomy. All methods seem to have good outcomes. However, physicians should not be afraid of advancing beyond conservative therapy, especially in the event of persistent premacular hemorrhage, which could lead to permanent retinal damage if valuable time is lost, even after vitrectomy.

KEYWORDS

Valsalva maneuver, retinopathy, retina, optical coherence tomography, Nd-YAG laser, Neodymium-Doped Yttrium Aluminum Garnet laser

INTRODUCTION

Valsalva retinopathy is a result of preretinal hemorrhages secondary to an acute elevation of intrathoracic or intra-abdominal pressure. It can occur in any person, regardless of health status. In most cases, vision normalizes after the resolution of bleeding [1, 2].

Correspondence: Petros Asteris, University Hospital of Ioannina, Department of Ophthalmology, Stavros Niarchos Avenue, Ioannina, GR 455 00, Greece. Email: petrosasteris94@gmail.com. ORCID iD: <https://orcid.org/0000-0002-4692-2719>

How to cite this article: Asteris P, Kalogeropoulos D, Moussa G, Vitos II, Christodoulou A, Kalogeropoulos C. A brief review of Valsalva retinopathy. *Med Hypothesis Discov Innov Optom.* 2022 Summer; 3(2): 42-47. <https://doi.org/10.51329/mehdiptometry149>

Received: 19 September 2022; Accepted: 28 October 2022



Copyright © Author(s). This is an open-access article distributed under the terms of the Creative Commons Attribution-NonCommercial 4.0 International License (<https://creativecommons.org/licenses/by-nc/4.0/>) which permits copy and redistribute the material just in noncommercial usages, provided the original work is properly cited.



The disease was initially described in 1972 by Thomas Duane as a particular form of preretinal and hemorrhagic retinopathy that occurs after a sudden increase in intrathoracic pressure [1, 3]. The term was first associated with retinal hemorrhage secondary to heavy lifting, coughing, vomiting, or straining during defecation. The Valsalva maneuver stems from the Italian anatomist Antonio Maria Valsalva, who characterized the Valsalva ligaments and anatomy linked to the forcible exhalation effort against a closed glottis [4].

This review focuses on the current literature and future directions for the diagnosis and management of Valsalva retinopathy.

Etiology and general pathology

As the name suggests, the condition appears after the Valsalva maneuver has been performed in some capacity during day-to-day activities. The most common activities include weight-lifting, vomiting, coughing, sneezing, aerobic exercises, straining with defecation, blowing musical instruments, strenuous physical activities, sexual intercourse, pregnancy, and after general anesthesia [2, 5-9]. Valsalva retinopathy has also been reported after cardiopulmonary resuscitation [10] and compression injuries [11]. It occurs due to the rupture of small superficial capillaries in the macula and perimacular area [7]. This, in turn, leads to extravasation of blood into the retina, usually below the internal limiting membrane (ILM), although vitreous hemorrhage and subhyaloid hemorrhage can occur [1].

Although there are no clear links to age, sex, or race, some predispositions have been found due to acquired and congenital vascular abnormalities of the fundus, such as proliferative diabetic retinopathy, congenital retinal macrovessel, hypertensive retinal angiopathy, congenital changes in retinal vessels including retinal arterial tortuosity, and retinal telangiectasis [1, 12].

Pathophysiology

The Valsalva maneuver occurs with forced expiration against a closed glottis [4]. This causes a sudden rise in venous blood pressure due to an increase in intrathoracic or intra-abdominal pressure. If the venous valves of the head and neck do not function properly, the aforementioned increase in venous pressure is transmitted to the eyes. This sudden rise in intraocular venous pressure leads to rupture of the perifoveal superficial retinal capillaries, causing hemorrhagic detachment of the ILM, which acts as a barrier preventing its spread to the subhyaloid space [13].

Ocular symptoms

The main symptom is reduction in visual acuity, which varies in severity depending on the extent of hemorrhage. The onset is sudden and painless, most often unilateral (rarely bilateral), following a Valsalva maneuver. The patient typically reports a central scotoma with the extent of blurring and reduction of vision depending on the location and intensity of the bleeding. Owing to the presence of blood, some reddish hues in vision can also appear [1, 2, 6, 14].

Ocular signs

During funduscopy [15], Valsalva retinopathy typically appears as a well-defined, round/oval/dumbbell-shaped area filled with blood to varying extent. Usually, these areas are larger than one disc diameter. The hemorrhage is preretinal, usually sub-ILM or in the subhyaloid space. ILM striae can often be observed over the hemorrhage. In the acute stage, the areas can appear cyst-like, with bright red preretinal blood and the involved area being elevated with a convex configuration toward the vitreous. There may be a fluid level with red blood corpuscles gravitating inferiorly and a horizontal upper level. At times, blood can become trapped in the sub-ILM and subhyaloid space, presenting with a "double ring sign". The outer ring represents the sub-hyaloid, and the inner ring represents sub-ILM hemorrhage [16].

Occasionally, the preretinal hemorrhage may be less than one disc area in size, with a strawberry-like appearance due to yellowish-white spots. With time, the bright red hue of the blood in the affected areas might have a yellow or even white discoloration, especially in persistent cases, owing to the presence of dehemoglobinized blood [17]. Other signs include petechial hemorrhage of the eyelids, subconjunctival hemorrhage, superficial intraretinal hemorrhage, retinal transudation, subretinal hemorrhage at the fovea after dissection of blood beneath the retina, and breakthrough vitreous hemorrhage [1, 3].

The only sign observed in old or resolved Valsalva retinopathy is cavity formation at the level of the bleed (as a sub-ILM cavity or serous detachment of the ILM), which might lead to a diagnostic challenge, as it may resemble neurosensory detachment [18]. The presence of brown pigment (blood products) at the borders of a serous ILM detachment can signal a previous sub-ILM hemorrhage.

Diagnosis

All the standard procedures of a routine examination must be applied, namely a detailed patient history and visual acuity measurement, mostly as a means to monitor the patient, along with intraocular pressure measurement and pupillary reactions. Slit-lamp assessment of the anterior segment is expected to be normal, but subconjunctival hemorrhages can be detected. During funduscopy, the clinician should inspect for the aforementioned signs. Fundus photography (Figure 1) is useful for monitoring the disease progression. Optical coherence tomography imaging (Figure 2) should be used to distinguish the location of the bleeding. Fundus fluorescein angiography is useful for detecting neovascularization and other fundus abnormalities [19-21]. B-scan ultrasonography should be performed in cases of breakthrough intravitreal hemorrhage [22].

Differential diagnosis

Differential diagnoses include traumatic retinopathy, posterior vitreous detachment, diabetic retinopathy, hypertensive retinopathy, sickle cell retinopathy, Purtscher's retinopathy, Terson's syndrome [23], ruptured macroaneurysm, intraocular parasites, and retinal detachment [24]. Therefore, it is important to interpret clinical examination findings in the context of a thorough patient history. In cases of acute posterior vitreous detachment, peripheral retinal tears should be ruled out.

Retinal hemorrhages were not identified in infants with vomiting due to hypertrophic pyloric stenosis [25]. A few conditions other than Valsalva retinopathy can create multi-layered hemorrhages (preretinal/intraretinal/subretinal), namely trauma and leukemic/anemic retinopathy. In some cases, preretinal Valsalva-like hemorrhages can occur in otherwise healthy individuals that report no history of the Valsalva maneuver of exertion [1, 26, 27]. In such cases, one should consider alternative diagnoses such as retinal angiopathy (e.g., hypertensive or diabetic), impaired platelet aggregation, or a history of anticoagulant therapy. Some patients with recurrent preretinal hemorrhage may have a family history of such, and it may be an autosomal dominant disease [1, 28].

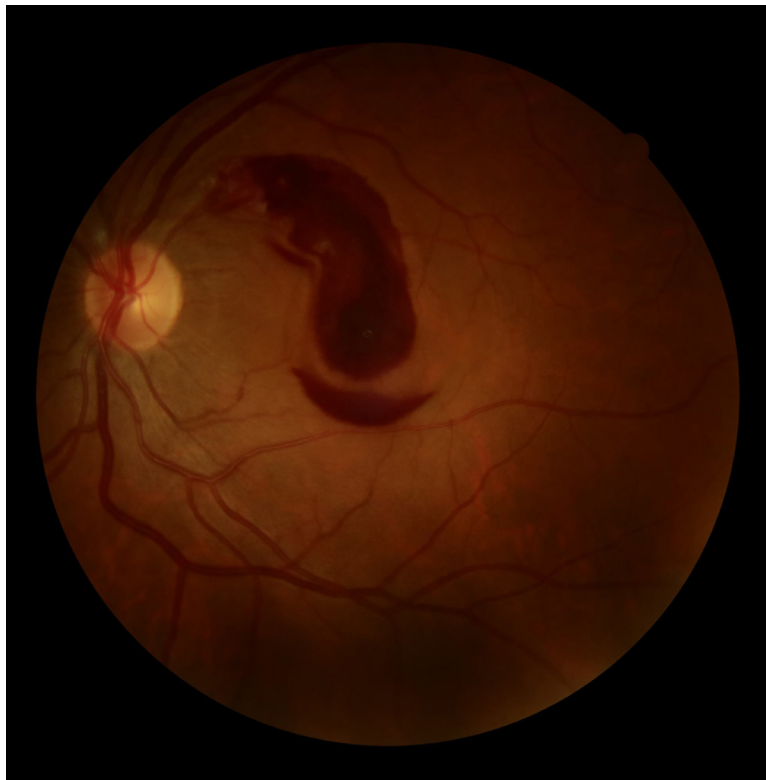


Figure 1. Fundus photography (Canon CR-2 Plus AF non-mydratric retinal camera, Tokyo, Japan) shows the typical appearance of Valsalva retinopathy, featuring a well-defined, round, oval, dumbbell-shaped area filled to some extent with blood. Usually, these areas are larger than one disc diameter in size. This is the left eye of a 28-year-old man with Valsalva retinopathy; the hemorrhage is preretinal and sub-internal limiting membrane. In the acute stage, the areas can appear cyst-like, with bright red preretinal blood. There may be a fluid level with red blood corpuscles gravitating inferiorly and a horizontal upper level.

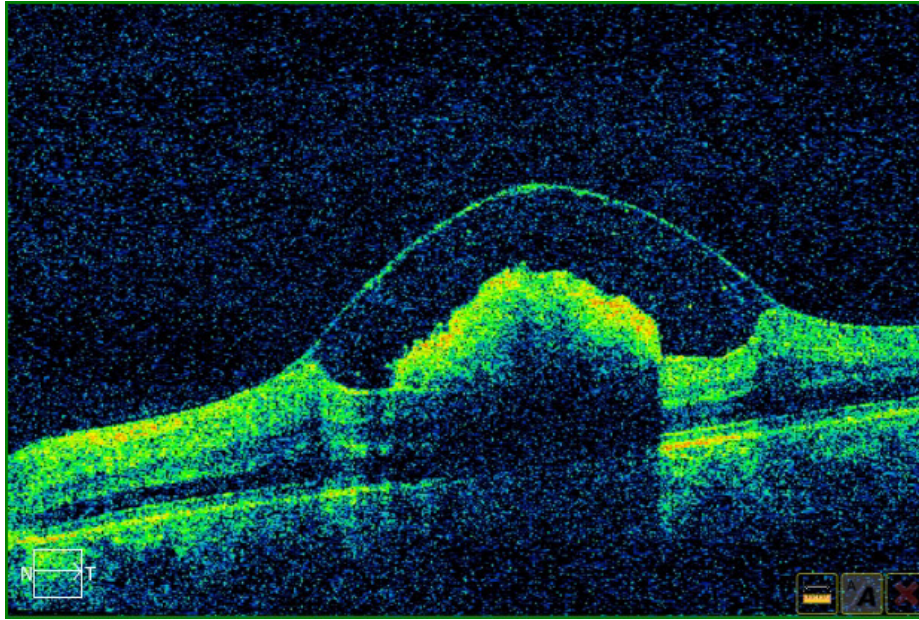


Figure 2. Optical coherence tomography (Cirrus HD-OCT, Carl Zeiss Meditec, Dublin, CA, USA) is an exceptionally useful imaging tool to distinguish the location and extent of bleeding, to detect other possible pathologies, and to meticulously monitor the patient until the resolution of hemorrhage. This is an OCT scan of the same patient as in Figure 1, revealing a well-defined dome-shaped area containing blood, with internal limiting membrane striae observed over the hemorrhage.

Treatment

In the vast majority of cases, no specific therapy is needed, and patient monitoring is appropriate. The conservative approach comprises observation until spontaneous resolution [29], which occurs within weeks to months. If the patient is on anticoagulant therapy, it must be optimized and strenuous physical activity must be limited. Other predisposing factors should be considered; for example, stool softeners can be used to treat straining associated with constipation. Patients should also maintain an upright position so the blood can settle inferiorly.

If conservative therapy is not optimal (e.g., massive hemorrhage in the macula, especially subretinal hemorrhage), other therapeutic choices should be considered. These include Nd:YAG laser membranotomy and pars plana vitrectomy [3, 30]. Nd:YAG (pulse/Q-switched/frequency-doubled) krypton laser membranotomy can be used for a large subhyaloid/sub-ILM hemorrhage that is located at the macula and is at least 3 disc diameters in size [5, 20, 31, 32]. The duration of bleeding should ideally be no more than 3 weeks [5, 19].

The laser is used to make an opening in the posterior hyaloid or ILM so that blood escapes into the vitreous cavity and settles inferiorly [32, 33]. However, complications are possible [34]. One should avoid large blood vessels, maintain a safe distance from the fovea, and perform membranotomy at the inferior margin of the hemorrhage [19]. Complications mainly include the formation of a macular epiretinal membrane [35], a macular hole [36], and vitreous hemorrhage [19]. It is noteworthy that in some cases of ILM membranotomy, the ILM may remain unsealed and not properly attach to the inner retina [37].

Vitrectomy can also be performed in cases of significant and long-standing premacular hemorrhage or dense vitreous hemorrhage, especially when the aforementioned criteria for the use of Nd:YAG laser membranotomy are absent, when the retina cannot be clearly observed because of hyaloid hemorrhage, or when spontaneous reabsorption is inadequate. Although vitrectomy for sub-ILM hemorrhage has mostly excellent results and low complication rates [38], there have been some instances of macular hole formation postoperatively [39]. Other complications include elevated intraocular pressure, cataract formation, and retinal detachment [38].

Prognosis

In most cases, the prognosis is good, with complete resolution of hemorrhage and recovery to baseline vision within weeks to months after onset. In some cases, as long as six months may be required for the hemorrhage to resolve [40]. Although complications seldom arise, there have been instances of severe or permanent vision loss in cases of long-standing hemorrhage. This is caused by ferritin deposition within the retinal pigment epithelial cells. Delayed surgical intervention may lead to proliferative vitreoretinopathy-like changes on the inner retinal surface of the ILM, and untreated cases may demonstrate persistent inner retinal changes, potentially limiting

visual prognosis despite subsequent surgical intervention [41].

CONCLUSIONS

The most challenging features of Valsalva retinopathy are the differential diagnosis and the choice of optimal therapeutic strategy. Valsalva retinopathy can be confounding, considering that it has similar manifestations to a number of other fundus pathologies. A detailed medical history is of utmost importance to overcome this obstacle. All other information gathered during a complete ophthalmological examination assists in corroborating the diagnosis. Therapeutic strategies for Valsalva retinopathy can be either conservative or based on Nd:YAG laser membranotomy and/or vitrectomy. All methods seem to have good outcomes. However, physicians should not hesitate to advance beyond conservative therapy, especially in the event of persistent premacular hemorrhage, considering that it can cause irreversible retinal damage if valuable time is lost, even after vitrectomy.

ETHICAL DECLARATIONS

Ethical approval: Not required.

Conflict of interests: None

FUNDING

None.

ACKNOWLEDGMENTS

None.

REFERENCES

1. Simakurthy S, Tripathy K. Valsalva Retinopathy. 2022 Jun 27. In: StatPearls [Internet]. Treasure Island (FL): StatPearls Publishing; 2022–[pmid: 31424803](#)
2. Li N, Zhu Z, Yi G, Li S, Han X. Valsalva Retinopathy in Twin-Pregnancy: A Case Report and Literature Review. *Am J Case Rep.* 2018;19:5-9. [doi: 10.12659/ajcr.905738](#) [pmid: 29292366](#)
3. Jena S, Tripathy K. Vitreous Hemorrhage. 2022 Feb 21. In: StatPearls [Internet]. Treasure Island (FL): StatPearls Publishing; 2022 Jan–. [pmid: 32644557](#)
4. Srivastav S, Jamil RT, Zeltser R. Valsalva Maneuver. 2022 May 2. In: StatPearls [Internet]. Treasure Island (FL): StatPearls Publishing; 2022 Jan–. [pmid: 30725933](#)
5. Durukan AH, Kerimoglu H, Erdurman C, Demirel A, Karagul S. Long-term results of Nd:YAG laser treatment for premacular subhyaloid haemorrhage owing to Valsalva retinopathy. *Eye (Lond).* 2008;22(2):214-8. [doi: 10.1038/sj.eye.6702574](#) [pmid: 16946748](#)
6. Michaels L, Tint NL, Alexander P. Postcoital visual loss due to valsalva retinopathy. *BMJ Case Rep.* 2014;2014:bcr2014207130. [doi: 10.1136/bcr-2014-207130](#) [pmid: 25342034](#)
7. Patane PS, Krummenacher TK, Rao RC. Valsalva hemorrhagic retinopathy presenting as a rare cause of impaired vision after a general anesthetic—a case report and review of the literature. *J Clin Anesth.* 2015;27(4):341-6. [doi: 10.1016/j.jclinane.2015.03.013](#) [pmid: 25865821](#)
8. Al-Mujaini AS, Montana CC. Valsalva retinopathy in pregnancy: a case report. *J Med Case Rep.* 2008;2:101. [doi: 10.1186/1752-1947-2-101](#) [pmid: 18394189](#)
9. Nascimento PA, Carbajo CN, Mendonça LSM, Okimoto JT, Barros BCM, Abucham-Neto JZ. Preretinal hemorrhage preventing subretinal involvement in multilayer macular hemorrhages: coincidence or plausible relationship? *Int J Retina Vitreous.* 2021;7(1):21. [doi: 10.1186/s40942-021-00291-y](#) [pmid: 33726844](#)
10. Kim JH, Hyun SY, Chae JB, Kim SM. Valsalva retinopathy and branch retinal artery occlusion after cardiopulmonary cerebral resuscitation. *Am J Emerg Med.* 2014;32(12):1558.e3-4. [doi: 10.1016/j.ajem.2014.05.028](#) [pmid: 25043628](#)
11. Chandra P, Azad R, Pal N, Sharma Y, Chhabra MS. Valsalva and Purtscher's retinopathy with optic neuropathy in compressive thoracic injury. *Eye (Lond).* 2005;19(8):914-5. [doi: 10.1038/sj.eye.6701665](#) [pmid: 15359240](#)
12. de Crecchio G, Pacente L, Alfieri MC, Greco GM. Valsalva retinopathy associated with a congenital retinal macrovessel. *Arch Ophthalmol.* 2000;118(1):146-7. [doi: 10.1001/archophth.118.1.146](#) [pmid: 10636437](#)
13. Chawla R, Tripathy K, Temkar S, Kumar V. Internal limiting membrane: The innermost retinal barrier. *Med Hypotheses.* 2017;98:60-62. [doi: 10.1016/j.mehy.2016.11.017](#) [pmid: 28012608](#)
14. Nagar A, Dhingra N. Valsalva retinopathy. *Postgrad Med J.* 2017;93(1097):174. [doi: 10.1136/postgradmedj-2016-134176](#) [pmid: 27634635](#)
15. Tripathy K, Chawla R. Valsalva retinopathy. *Natl Med J India.* 2015;28(6):310 [pmid: 27294466](#)
16. Sakamoto SI, Makino S, Tampo H. Double ring sign at the macula in a patient with Valsalva retinopathy. *QJM.* 2014;107(12):1045-6. [doi: 10.1093/qjmed/hcu102](#) [pmid: 24811549](#)
17. Rajshri H, Krishnappa NC, Sharma U, Ganne P. Long-standing Valsalva retinopathy. *BMJ Case Rep.* 2021;14(3):e240812. [doi: 10.1136/bcr-2020-240812](#) [pmid: 33674301](#)

18. Tripathy K, Chawla R, Vekaria L, Sharma YR. Sub-internal Limiting Membrane Cavity Following Valsalva Retinopathy Resembling Central Serous Chorioretinopathy. *J Ophthalmic Vis Res.* 2018;13(1):83-84. doi: [10.4103/jovr.jovr_192_16](https://doi.org/10.4103/jovr.jovr_192_16) pmid: 29403598
19. Zhang Y, Li J, Cao X, Zhou H, Jia L, Gao L, et al. Efficiency and Complication of 577-nm Laser Membranotomy for the Treatment of Retinal Sub-Internal Limiting Membrane Hemorrhage. *Front. Ophthalmol.* 2022;2:935188. doi: [10.3389/fopht.2022.935188](https://doi.org/10.3389/fopht.2022.935188)
20. Babu N, Kohli P, Rajan RP, Ramasamy K. Inverse drainage Nd:YAG membranotomy for pre-macular hemorrhage. *Eur J Ophthalmol.* 2022;11206721221102258. doi: [10.1177/11206721221102258](https://doi.org/10.1177/11206721221102258) pmid: 35581714
21. Panayiotis C, Ioannis K. Fluorescent angiography imaging of intravitreal active bleeding, due to deep venous thrombosis concomitant to Fournier gangrene. *Eur J Ophthalmol.* 2022;32(1):NPS-NP8. doi: [10.1177/1120672120945106](https://doi.org/10.1177/1120672120945106) pmid: 32700553
22. Couperus K, Angel S, Kim N, Flugge K, Perreault M. A Unique Case of Valsalva Retinopathy: Preretinal Hemorrhage Identified on Bedside Ultrasound. *J Emerg Med.* 2021;60(2):220-222. doi: [10.1016/j.jemermed.2020.09.033](https://doi.org/10.1016/j.jemermed.2020.09.033) pmid: 33588993
23. Tripathy K. Dissociated optic nerve fiber layer in a case of Terson syndrome. *Eur J Ophthalmol.* 2020;30(5):NP11-NP14. doi: [10.1177/1120672119853465](https://doi.org/10.1177/1120672119853465) pmid: 31155955
24. Johnson S, Ryan T, Omari A, Schneider S, Bahl A. Valsalva Retinopathy Masking as a Retinal Detachment on Point-of-care Ocular Ultrasound: A Case Report. *Clin Pract Cases Emerg Med.* 2022;6(2):125-128. doi: [10.5811/cpcem.2022.1.55173](https://doi.org/10.5811/cpcem.2022.1.55173) pmid: 35701352
25. Herr S, Pierce MC, Berger RP, Ford H, Pitetti RD. Does valsalva retinopathy occur in infants? An initial investigation in infants with vomiting caused by pyloric stenosis. *Pediatrics.* 2004;113(6):1658-61. doi: [10.1542/peds.113.6.1658](https://doi.org/10.1542/peds.113.6.1658) pmid: 15173487
26. Singh D, Tripathy K. Retinal Macroaneurysm. 2022 Mar 25. In: *StatPearls [Internet]*. Treasure Island (FL): StatPearls Publishing; 2022 Jan-. pmid: 35015432
27. Khan MT, Saeed MU, Shehzad MS, Qazi ZA. Nd:YAG laser treatment for Valsalva premacular hemorrhages: 6 month follow up : alternative management options for preretinal premacular hemorrhages in Valsalva retinopathy. *Int Ophthalmol.* 2008;28(5):325-7. doi: [10.1007/s10792-007-9138-6](https://doi.org/10.1007/s10792-007-9138-6) pmid: 17891339
28. Sutter FK, Helbig H. Familial retinal arteriolar tortuosity: a review. *Surv Ophthalmol.* 2003;48(3):245-55. doi: [10.1016/s0039-6257\(03\)00029-8](https://doi.org/10.1016/s0039-6257(03)00029-8) pmid: 12745002
29. Abihaidar N, Gain P, Thuret G, Garcin T. Spontaneous resolution of Valsalva retinopathy in a diabetic patient. *J Fr Ophthalmol.* 2022;45(5):578-579. doi: [10.1016/j.jfo.2021.04.019](https://doi.org/10.1016/j.jfo.2021.04.019) pmid: 35459570
30. Tian Z, Li H, Zhu Y, Jin X, Li Y, Li X, et al. Spontaneous Closure of a Macular Hole After Nd:YAG Laser Treatment for Valsalva Retinopathy in Pregnancy. *JAMA Ophthalmol.* 2021;139(7):807-809. doi: [10.1001/jamaophthalmol.2021.1619](https://doi.org/10.1001/jamaophthalmol.2021.1619) pmid: 34081074
31. Tripathi A, Agarwal R, Chaurasia S. Role of Neodymium Double Frequency Laser Posterior Hyaloidotomy in Delayed Presentation of Sub-hyaloid Haemorrhage. *Cureus.* 2022;14(1):e21534. doi: [10.7759/cureus.21534](https://doi.org/10.7759/cureus.21534) pmid: 35223309
32. Chen YJ, Kou HK. Krypton laser membranotomy in the treatment of dense premacular hemorrhage. *Can J Ophthalmol.* 2004;39(7):761-6. doi: [10.1016/s0008-4182\(04\)80070-x](https://doi.org/10.1016/s0008-4182(04)80070-x) pmid: 15696766
33. Solyman OM, Ghalwash AA. Valsalva retinopathy in a teenager treated with Nd:YAG laser posterior hyaloidotomy. *Pan Afr Med J.* 2021;38:161. doi: [10.11604/pamj.2021.38.161.28100](https://doi.org/10.11604/pamj.2021.38.161.28100) pmid: 33995768
34. Brar AS, Ramachandran S, Padhy SK. Triple trouble: sequelae of Nd: YAG photodisruptive laser membranotomy for Valsalva retinopathy. *Can J Ophthalmol.* 2022;57(1):e14-e16. doi: [10.1016/j.jcjo.2021.05.005](https://doi.org/10.1016/j.jcjo.2021.05.005) pmid: 34119462
35. Kwok AK, Lai TY, Chan NR. Epiretinal membrane formation with internal limiting membrane wrinkling after Nd:YAG laser membranotomy in valsalva retinopathy. *Am J Ophthalmol.* 2003;136(4):763-6. doi: [10.1016/s0002-9394\(03\)00442-2](https://doi.org/10.1016/s0002-9394(03)00442-2) pmid: 14516831
36. Goker YS, Tekin K, Ucgul Atilgan C, Kosekahya P, Yilmazbas P. Full Thickness Retinal Hole Formation after Nd:YAG Laser Hyaloidotomy in a Case with Valsalva Retinopathy. *Case Rep Ophthalmol Med.* 2018;2018:2874908. doi: [10.1155/2018/2874908](https://doi.org/10.1155/2018/2874908) pmid: 29967707
37. Zou M, Gao S, Zhang J, Zhang M. Persistent unsealed internal limiting membrane after Nd:YAG laser treatment for valsalva retinopathy. *BMC Ophthalmol.* 2013;13:15. doi: [10.1186/1471-2415-13-15](https://doi.org/10.1186/1471-2415-13-15) pmid: 23587284
38. De Maeyer K, Van Ginderdeuren R, Postelmans L, Stalmans P, Van Calster J. Sub-inner limiting membrane haemorrhage: causes and treatment with vitrectomy. *Br J Ophthalmol.* 2007;91(7):869-72. doi: [10.1136/bjo.2006.109132](https://doi.org/10.1136/bjo.2006.109132) pmid: 17229799
39. Kim KY, Yu SY, Kim M, Kwak HW. Macular hole formation after pars plana vitrectomy for the treatment of Valsalva retinopathy: a case report. *Korean J Ophthalmol.* 2014;28(1):91-5. doi: [10.3341/kjo.2014.28.1.91](https://doi.org/10.3341/kjo.2014.28.1.91) pmid: 24505205
40. Khadka D, Bhandari S, Bajimaya S, Thapa R, Paudyal G, Pradhan E. Nd:YAG laser hyaloidotomy in the management of Premacular Subhyaloid Hemorrhage. *BMC Ophthalmol.* 2016;16:41. doi: [10.1186/s12886-016-0218-0](https://doi.org/10.1186/s12886-016-0218-0) pmid: 27090882
41. Hussain RN, Stappler T, Hiscott P, Wong D. Histopathological Changes and Clinical Outcomes following Intervention for Sub-Internal Limiting Membrane Haemorrhage. *Ophthalmologica.* 2020;243(3):217-223. doi: [10.1159/000502442](https://doi.org/10.1159/000502442) pmid: 31743895