



Unilateral asymptomatic optic disc edema: do not forget sinusitis

Sajeev Cherian Jacob ¹, Lavanya Kalikivayi ¹ and Venkataramana Kalikivayi ¹

¹ Ahalia Foundation Eye Hospital, Palakkad, Kerala, India

ABSTRACT

Background: Optic disc edema is a pathological condition with various causes. Cases of optic disc swelling should be dealt with a multidisciplinary approach to rule out those causes. Unilateral optic disc edema is seen in papillitis, non-arteritic anterior ischemic optic neuropathy, retinal vein occlusion, and infection or inflammation of the contiguous sinus or orbit. Here, we report a rare case of unilateral asymptomatic optic disc edema due to posterior ethmoid sinusitis.

Case Presentation: A 53-year-old man presented for a routine 3-monthly follow-up after an uneventful cataract surgery of the right eye. All examinations were unremarkable, except for the right eye optic disc edema on fundus examination, consistent with an enlarged blind spot in the visual field test. Contrast-enhanced magnetic resonance imaging revealed mucosal thickening with muco-inflammatory exudates of the posterior ethmoidal sinus overriding the optic disc on the right side, leading to optic disc edema of the right eye. The patient was diagnosed with unilateral asymptomatic optic disc edema in the right eye due to posterior ethmoid sinusitis and referred to an otorhinolaryngologist for the management. The otorhinolaryngologist performed functional endoscopic sinus surgery and prescribed antibiotics and antihistamines for 6 weeks. At the final examination, his visual acuity was 6/6, and the fundus examination revealed no optic disc edema.

Conclusions: We reported a rare case of unilateral optic nerve edema and an enlarged blind spot in the visual field with a treatable cause. Contemporary imaging provided the accurate diagnosis. Therefore, in cases of disc edema, sinusitis of the adjacent paranasal sinuses should be ruled out as a possible cause of compressive optic neuropathy or inflammation overriding the optic nerve.

KEYWORDS

ethmoid sinusitis, optic nerve head, optic disk edema, magnetic resonance image, magnetization transfer contrast imaging, otolaryngologist, paranasal sinuses, antibiotics

INTRODUCTION

Unilateral optic disc swelling is a pathological condition with various causes [1]. It is observed in conditions such as papillitis, acute non-arteritic anterior ischemic optic neuropathy, retinal vein occlusion, trauma, iatrogenic conditions, systemic disease, or any infection or inflammation of the contiguous sinus or orbit [2-6]. Whipple disease [7], mechanical compression of the optic nerve by the adjacent paranasal sinus [8], bacterial sphenoidal sinusitis [9], sinus mucocele [10], drugs [11], unilateral papilledema [12], metastatic carcinoma [13], viral meningitis [14],

Correspondence: Venkataramana Kalikivayi, Ahalia School of Optometry, Ahalia Foundation Eye Hospital, Palakkad 678557, Kerala, India. Email: kalikivayi@yahoo.com. ORCID iD: <https://orcid.org/0000-0003-4673-0802>

How to cite this article: Jacob SC, Kalikivayi L, Kalikivayi V. Unilateral asymptomatic optic disc edema: do not forget sinusitis. *Med Hypothesis Discov Innov Optom.* 2022 Summer; 3(2): 70-74. <https://doi.org/10.51329/mehdiptometry154>

Received: 10 October 2022; Accepted: 28 October 2022



Copyright © Author(s). This is an open-access article distributed under the terms of the Creative Commons Attribution-NonCommercial 4.0 International License (<https://creativecommons.org/licenses/by-nc/4.0/>) which permits copy and redistribute the material just in noncommercial usages, provided the original work is properly cited.



cerebral arteriovenous malformation [15], and cerebral sinus venous thrombosis [16] are among the reported causes of this condition.

Unilateral optic disc edema can be associated with symptoms and signs, such as headache, progressive or sudden vision loss, diplopia, optic disc swelling, enlargement of the blind spot, a relative afferent pupillary defect, decreased color vision, and enlargement of the blind spot [4, 8, 13, 17, 18], or it could be asymptomatic [7, 19]. A delay in diagnosis is not uncommon [20] because vision loss is insidious and clinical findings can be missed. Any case of optic disc swelling should be approached in a multidisciplinary fashion to rule out these causes [7, 10].

With the advent of modern neuroimaging, the possibility of missing a compressive cause has been almost entirely eliminated [21]. Herein, we report a rare case of asymptomatic unilateral optic disc edema secondary to posterior ethmoidal sinusitis with an excellent prognosis.

CASE PRESENTATION

A 53-year-old man underwent an uneventful cataract surgery in his right eye. His preoperative best-corrected distance visual acuity in the right eye was 6/38 (+ 0.8 logarithm of the minimum angle of resolution) with nuclear sclerosis. Ophthalmoscopy revealed a normal fundus with no optic nerve head drusen or edema. The patient's general health was normal. No family history of any specific illness and no history of injury or medication use, other than those prescribed post-cataract surgery was reported. He was neither a smoker nor an alcoholic.

On the three-month post-cataract surgery follow-up assessment, his best-corrected distance visual acuity was 6/6 (0.0 logarithm of the minimum angle of resolution) in both eyes, with normal color vision testing using the Ishihara Test Booklet 38 plate chart. External eye examination and ocular motility were normal. The pupillary reaction was within normal limits in both eyes, and no relative afferent pupillary defect was present. Red desaturation and light saturation were unremarkable in both eyes. Slit lamp examination (Topcon Corporation, Tokyo, Japan) of the anterior segment was unremarkable except for the posterior chamber intraocular lens in situ in the right eye and nuclear sclerosis in the left eye. Intraocular pressure measured using a Goldmann applanation tonometer (Haag Streit, Koeniz, Switzerland) at 10:30 AM was 16 mmHg in both eyes. Fundus examination using binocular indirect ophthalmoscopy (Keeler Instruments, Inc., PA, USA) and + 20 diopter ancillary lens (VOLK Optical, Mentor, USA) revealed diffuse optic disc edema in the right eye, elevated disc, tortuous veins surrounding the optic disc, edema of the peripapillary nerve fiber layer, indistinct disc margins, and no peripapillary or disc hemorrhages (Figure 1). The fundus of the left eye was normal. The neurological and systemic examinations were thorough and unremarkable.

Standard automated perimetry was performed. A grayscale display of the standard Humphrey program 30-2 visual field (Carl Zeiss Meditec, Inc., Germany) revealed an enlarged blind spot in the right eye, as shown in Figure 2, which corresponded to the optic disc edema. The visual field of the left eye was within normal limits.

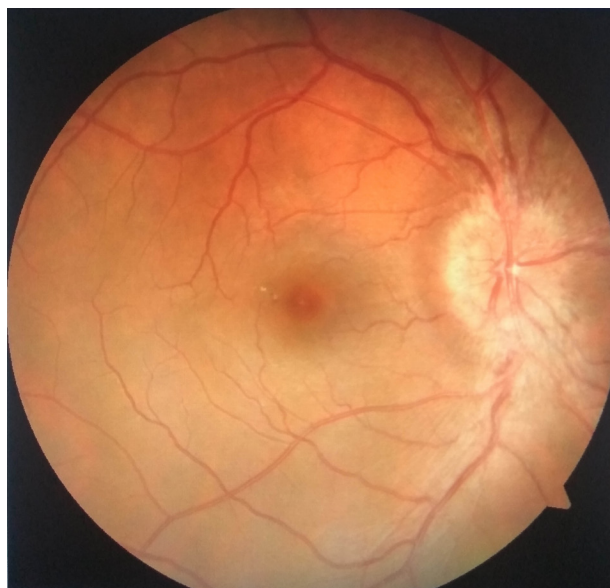

Figure 1. Fundus photo (TOPCON TRC-50 DX, Japan) of the right eye showing diffuse optic disc edema without peripapillary or disc hemorrhages. Note the indistinct optic disc borders and edema of the peripapillary nerve fiber layer.

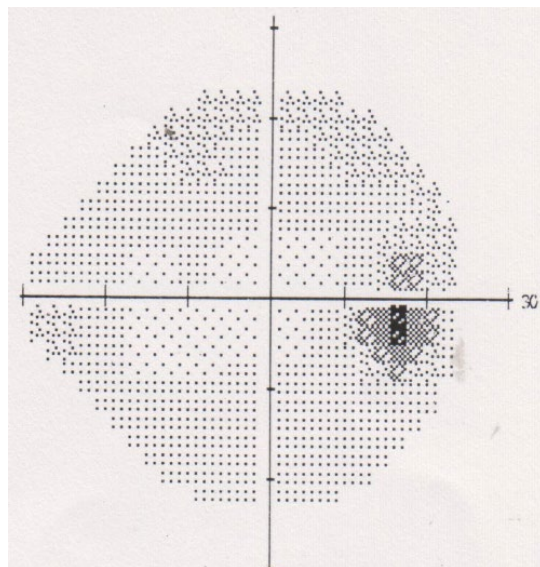


Figure 2. Grayscale display using the standard Humphrey program 30-2 (Carl Zeiss Meditec, Inc., Germany) of the right eye visual field showing an enlarged blind spot.

Although significant optic disc edema was observed in the right eye with enlargement of the blind spot in the visual field, the patient was asymptomatic. The absence of altitudinal field defects ruled out anterior ischemic optic neuropathy [3]. This prompted further investigations and contrasted magnetic resonance imaging (MRI) of the brain, orbit, and paranasal sinuses. The MRI result implied mucosal thickening with mucoinflammatory secretions in the posterior ethmoid sinus, suggestive of sinusitis. The mucoinflammatory collections overrode the optic nerve on the right side, resulting in optic disc edema. The absence of a localized finger-like lesion ruled out an ethmoidal sinus polyp [9, 10]. Because there was no bilateral optic disc edema and no supportive clinical symptoms or signs, increased intracranial pressure was ruled out [22].

Based on these findings, the patient was diagnosed with unilateral asymptomatic optic disc edema in the right eye due to posterior ethmoidal sinusitis. The patient was referred to an otorhinolaryngologist for further management and was advised to report for further follow-up. The patient was treated with a functional endoscopic sinus surgery [23, 24] with oral antibiotic and antihistamine [9] therapy for six weeks. At his last visit, six weeks after treatment, his right eye best-corrected visual acuity was 6/6 at distance and N6 at near. Fundus examination revealed no optic disc edema.

This case report was approved by the institutional ethics committee. The patient provided written consent for participation and the publication of this case report.

DISCUSSION

We have herein presented a rare case of unilateral asymptomatic optic disc edema due to posterior ethmoid sinusitis that was managed successfully using a multidisciplinary team approach.

Our patient was asymptomatic, and optic disc swelling was discovered incidentally during a routine post-cataract surgery follow-up examination. Cases of asymptomatic unilateral optic disc swelling due to true [7, 25] or pseudo-optic disc edema [26] have been previously reported. Kanikunnel et al. [7] described a case of asymptomatic unilateral optic disc edema in a 49-year-old African American man with a best-corrected distance visual acuity of 20/20 in the affected eye. The initial workup, including neuroimaging and laboratory investigations, was unremarkable, yet the history was significant for human immunodeficiency virus infection. After the development of new gastrointestinal symptoms at follow-up, the patient consulted an internist and gastroenterologist and was finally diagnosed with Whipple disease, which was managed successfully with oral antibiotics [7]. Their case and the current case highlight the necessity of a multidisciplinary approach to establish the cause of asymptomatic unilateral optic disc swelling. Our patient was successfully managed by an otorhinolaryngologist using a combined surgical and medical approach.

Hawy et al. [25] reported 29 patients with unilateral optic disc edema, either asymptomatic or associated with minimal visual symptoms, with varied durations of disc edema based on etiology. The underlying causes

were idiopathic intracranial hypertension, optic nerve sheath meningioma, incipient non-arteritic anterior ischemic neuropathy, vitreopapillary traction, orbital masses, peripapillary choroidal neovascular membrane, and presumed papillophlebitis, with most having favorable visual outcomes. Likewise, our patient had an excellent prognosis. However, in asymptomatic unilateral optic disc edema, other differential diagnoses, such as disc drusen [26], that can masquerade as disc edema should be considered.

Unilateral optic disc edema has been reported following a head injury [5], after administration of systemic medications [6, 11], and with systemic diseases such as diabetes mellitus or hypertension [2]. Therefore, we approached the patient with a detailed medical and drug history. However, there was no history of injury or medication other than those prescribed post-cataract surgery. The patient was a non-smoker, non-alcoholic, and had normal general health.

Paraclinical and neuroimaging studies [17, 18] are exceptionally useful in approaching optic disc edema. In our patient, Humphrey's visual field test and contrasted MRI of the brain, orbit, and paranasal sinuses revealed an enlargement of the blind spot and posterior ethmoid sinusitis, respectively. Hence, as in our patient, when systemic and neurological examinations are unremarkable [17], these ancillary tests could facilitate a timely and logical approach to this potentially sight- or even life-threatening ocular entity.

Chronic sinusitis is characterized by inflammation, mucosal thickening, and polyp formation in the paranasal sinuses [27]. The posterior ethmoidal sinus and the optic nerve are anatomically proximal. This is especially true in patients with highly pneumatized posterior ethmoidal sinus cells (Onodi cell) [9, 24]. Acute inflammation of an Onodi cell affects vision through direct compression by a mucocele or through the direct spread of inflammation. A case of sphenoidal air cell sinusitis with recurrent optic neuritis was reported by OuYang et al. [9] and was managed successfully with oral antihistamine and amoxicillin-clavulanate 875 mg–125 mg twice daily without surgical intervention. Likewise, swelling of the optic disc resolved in our patient using the combined oral administration of antihistamine and antibiotic. However, in contrast to their patient, our patient was asymptomatic and underwent concurrent sinus surgery by an otorhinolaryngologist.

Sinusitis should always be considered in patients with impaired vision, optic neuritis, or unexplained papilledema [28]. Two uncommon pediatric cases of sinusitis sphenoidalis and ethmoidalis have been previously reported. One patient was a 13-year-old boy who experienced irreversible visual loss despite surgical intervention. The second case was that of an 11-year-old girl with pronounced papilledema who recovered completely after administration of appropriate antibiotic therapy [28]. In contrast to those cases, our patient was asymptomatic, presented with unilateral optic disc edema in conjunction with an enlarged blind spot in the visual field, and was successfully co-managed with an otorhinolaryngologist using surgical and medical approaches.

A 52-year-old man with progressive enlargement of the frontal and anterior ethmoidal sinuses due to mucoceles and unilateral asymptomatic optic disc edema was previously reported. The patient was successfully co-managed by an otorhinolaryngologist with sinus surgery [10]. Likewise, we referred our patient to the otorhinolaryngology department because of the importance of timely management of optic disc swelling, and the patient was free of abnormal signs after combined surgical and medical management.

This was a rare case of unilateral optic disc swelling with successful and timely multidisciplinary management. A limitation of this case report is the lack of other ocular imaging modalities, such as fundus fluorescein angiography or spectral domain optical coherence tomography, which could provide more details of the optic disc vessels or peripapillary nerve fiber layer thickness in cases of optic disc edema. In the future, serial follow-up using these imaging modalities in patients who recovered from unilateral disc swelling may reveal subtle changes in the optic disc vasculature or nerve fiber layer structure despite the absence of symptoms.

CONCLUSIONS

This was a rare case of unilateral optic nerve swelling and an enlarged blind spot in the visual field with a treatable cause, which indicates that the initial presentation of patients with sinusitis is not always symptomatic with signs of inflammation. Rather, patients may be asymptomatic, as in the current case. Hence, in any case of unilateral disc edema, eye care clinicians must consider the possibility of sinusitis as a cause of either compressive optic neuropathy or inflammation overriding the optic nerve.

ETHICAL DECLARATIONS

Ethical approval: Institutional ethics committee approval was obtained for this study. The patient provided written informed consent for participation and the publication of this case report.

Conflict of interests: None

FUNDING

None.

ACKNOWLEDGMENTS

None.

REFERENCES

- Osaguona VB, Kayoma DH. Etiology of Optic Disc Swelling in a Tertiary Care Center in Nigeria. *Niger J Clin Pract.* 2020;23(12):1690-1694. doi: 10.4103/njcp.njcp_333_20 pmid: 33355822
- Jung JJ, Baek SH, Kim US. Analysis of the causes of optic disc swelling. *Korean J Ophthalmol.* 2011;25(1):33-6. doi: 10.3341/kjo.2011.25.1.33 pmid: 21350692
- Gandhi U, Chhablani J, Badakere A, Kekunnaya R, Rasheed MA, Goud A, et al. Optical coherence tomography angiography in acute unilateral nonarteritic anterior ischemic optic neuropathy: A comparison with the fellow eye and with eyes with papilledema. *Indian J Ophthalmol.* 2018;66(8):1144-1148. doi: 10.4103/ijo.IJO_179_18 pmid: 30038161
- Urfalioglu S, Ozdemir G, Guler M, Duman GG. The evaluation of patients with optic disc edema: A retrospective study. *North Clin Istanb.* 2021;8(3):280-285. doi: 10.14744/nci.2020.25483 pmid: 34222810
- Carson HJ, Lingamfelter D, Dudley MH. Optic nerve trauma with unilateral edema as a result of head injury. *J Forensic Leg Med.* 2010;17(5):283-4. doi: 10.1016/j.jflm.2010.04.001 pmid: 20569958
- DeLuca C, Shenouda-Awad N, Haskes C, Wrzesinski S. Imatinib mesylate (Gleevec) induced unilateral optic disc edema. *Optom Vis Sci.* 2012;89(10):e16-22. doi: 10.1097/OPX.0b013e318269111d pmid: 22960614
- Kanikunnel AM, Anthony SA, Eleff ES. Case Report: Tropheryma whipplei Infection Presenting with Optic Disc Edema. *Optom Vis Sci.* 2020;97(12):1041-1047. doi: 10.1097/OPX.0000000000001618 pmid: 33252544
- Detiger SE, Paridaens D, Verdijk RM, van Laar JAM, Dammers R, Monserez DA, et al. Vision loss caused by immunoglobulin G4-related disease of the skull base complicated by a mucocele of the sphenoid sinus. *Int Forum Allergy Rhinol.* 2022;12(9):1216-1220. doi: 10.1002/alr.22993 pmid: 35294105
- OuYang WL, Long C, Azam S, Jia C, Gokoffski K, Wong B, et al. Sphenothmoidal air cell sinusitis: A rare cause of recurrent optic neuritis. *Am J Ophthalmol Case Rep.* 2022;26:101485. doi: 10.1016/j.jajoc.2022.101485 pmid: 35300402
- Xia Y. A Fronto-ethmoidal Sinus Mucocele presenting with optic disc edema. *Radiol Case Rep.* 2021;16(11):3410-3413. doi: 10.1016/j.radcr.2021.07.091 pmid: 34504635
- Eryilmaz T, Atilla H, Batioglu F, Günel I. Amiodarone-related optic neuropathy. *Jpn J Ophthalmol.* 2000;44(5):565-8. doi: 10.1016/s0021-5155(00)00216-1 pmid: 11033139
- Matos AMF, Cunha LP, Suzuki ACF, Mello LGM, Preti RC, Zacharias LC, et al. Unilateral papilledema and peripapillary polypoidal choroidal vasculopathy as the presenting manifestations of intracranial hypertension. *Arq Bras Oftalmol.* 2021;84(6):598-601. doi: 10.5935/0004-2749.20210098 pmid: 34431881
- Van Brummen AJ, Li E, Scherpelz KP, Latimer CS, Chambers C, Zhang M. Metastatic Renal Cell Carcinoma Masquerading as a Sphenoid Wing Meningioma. *Ophthalmic Plast Reconstr Surg.* 2020;36(5):e128-e131. doi: 10.1097/IOP.0000000000001642 pmid: 32251182
- Karmiris E, Vasilakos G, Tsiropidis K, Chalkiadaki E. An Atypical Case of Enterovirus Meningitis Presenting with Unilateral Optic Disc Swelling and Minimal Optical Symptoms. *Ocul Immunol Inflamm.* 2022:1-6. doi: 10.1080/09273948.2022.2028288 pmid: 35113776
- Volpe NJ, Sharma MC, Galetta SL, Langer DJ, Liu GT, Hurst RW, et al. Orbital drainage from cerebral arteriovenous malformations. *Neurosurgery.* 2000;46(4):820-4. doi: 10.1097/00006123-200004000-00010 pmid: 10764254
- Nalawade R, Kannam M, Garuda BR, Sachdeva V. Unilateral persistent disc oedema due to cerebral sinus venous thrombosis (CSVT): diagnostic and management challenge. *BMJ Case Rep.* 2020;13(12):e234997. doi: 10.1136/bcr-2020-234997 pmid: 33372010
- Kanonidou E, Chatziralli I, Kanonidou C, Parava M, Ziakas N. Unilateral optic disc edema in a paediatric patient: diagnostic dilemmas and management. *Case Rep Med.* 2010;2010:529081. doi: 10.1155/2010/529081 pmid: 21209745
- Jastrzebski B, Torun N. A 45-year-old man with unilateral optic disc edema and vision loss. *Digit J Ophthalmol.* 2019;25(1):16-20. doi: 10.5693/djo.03.2019.02.002 pmid: 31080372
- Becker D, Larsen M, Lund-Andersen H, Hamann S. Diabetic papillopathy in patients with optic disc drusen: Description of two different phenotypes. *Eur J Ophthalmol.* 2022:11206721221100901. doi: 10.1177/11206721221100901 pmid: 35570569
- Cheung CM, Chee SP. Posterior scleritis in children: clinical features and treatment. *Ophthalmology.* 2012;119(1):59-65. doi: 10.1016/j.ophtha.2011.09.030 pmid: 22137553
- Selhorst JB, Chen Y. The optic nerve. *Semin Neurol.* 2009;29(1):29-35. doi: 10.1055/s-0028-1124020 pmid: 19214930
- Ahmad SR, Moss HE. Update on the Diagnosis and Treatment of Idiopathic Intracranial Hypertension. *Semin Neurol.* 2019;39(6):682-691. doi: 10.1055/s-0039-1698744 pmid: 31847039
- Hoang JK, Eastwood JD, Tebbit CL, Glastonbury CM. Multiplanar sinus CT: a systematic approach to imaging before functional endoscopic sinus surgery. *AJR Am J Roentgenol.* 2010;194(6):W527-36. doi: 10.2214/AJR.09.3584 pmid: 20489073
- Singhal P, Sonkhya N, Mishra P, Srivastava SP. Impact of anatomical and radiological findings for consideration of functional endoscopic sinus surgery. *Indian J Otolaryngol Head Neck Surg.* 2012;64(4):382-5. doi: 10.1007/s12070-011-0351-2 pmid: 24294585
- Hawy E, Sharma RA, Peragallo JH, Dattilo M, Newman NJ, Biousse V. Unilateral Isolated Paucisymptomatic Optic Disc Edema. *J Neuroophthalmol.* 2021;41(4):e523-e534. doi: 10.1097/WNO.0000000000001136 pmid: 33394642
- Ahmed H, Khazaeni L. Optic Disc Drusen. 2022 May 14. In: StatPearls [Internet]. Treasure Island (FL): StatPearls Publishing; 2022 Jan-. pmid: 35593854
- Pawankar R, Nonaka M. Inflammatory mechanisms and remodeling in chronic rhinosinusitis and nasal polyps. *Curr Allergy Asthma Rep.* 2007;7(3):202-8. doi: 10.1007/s11882-007-0073-4 pmid: 17448332
- Jüngert JM, Uberall M, Mayer UM, Guggenbichler JP, Heining U. Papillenödem und akute bilaterale Amaurose bei akuter Sinusitis [Papilledema and acute bilateral amaurosis accompanying acute sinusitis]. *Klin Padiatr.* 2001;213(6):343-6. German. doi: 10.1055/s-2001-18465 pmid: 11713715