



Outcomes of orbital decompression for thyroid eye disease over a 10-year period at a tertiary eye care referral center

Kouros Shahraki¹, Mehdi Tavakoli², Keivan Khosravifard³, Maryam Aletaha¹ and Hossein Salour¹

¹ Ophthalmic Research Center, Research Institute for Ophthalmology and Vision Science, Shahid Beheshti University of Medical Sciences, Tehran, Iran

² University of Alabama at Birmingham Heersink School of Medicine, Department of Ophthalmology and Visual Sciences, Birmingham, Alabama, USA

³ Department of Ophthalmology, AJA University of Medical Sciences, Tehran, Iran

ABSTRACT

Background: Orbital decompression is frequently indicated to treat exophthalmos and compressive optic neuropathy, among other indications for thyroid eye disease (TED). This study aimed to evaluate the outcomes of orbital decompression and compare the results by urgency and type of surgery in patients with TED.

Methods: In this cross-sectional study, we recruited patients with TED who had undergone emergency or elective orbital decompression surgery at a tertiary eye care referral center in Tehran, Iran, between 2010 and 2020. Ophthalmic examination findings, demographic and clinical profiles, and types and outcomes of surgical interventions were reviewed and analyzed.

Results: Fifty-one orbits of 35 patients with a mean (standard deviation [SD]) age of 36.2 (12.0) years and male-to-female ratio of 23 (66%)/12 (34%) were included. The mean (SD) duration from the diagnosis to the surgery was 41.0 (39.0) months. The surgical method was fat decompression in 1 (2%) orbit; fat and inferior wall decompressions in 2 (4%) orbits; fat, inferior, and medial wall (two-wall) decompressions in 43 (84%) orbits; and fat, inferior, medial, and lateral wall (three-wall) decompressions in five (10%) orbits. Three-wall decompression surgery resulted in significantly lower exophthalmometry readings than those associated with two-wall surgery at all postoperative follow-ups ($P < 0.05$). Ten (20%) orbits required emergency decompression because of sight-threatening conditions and revealed comparable exophthalmometry readings with electively decompressed orbits at the 1-year visit ($P > 0.05$). Thirty-seven (73%) orbits required other surgeries within the 1-year follow-up. The mean (SD) exophthalmometry readings before and 1-year after surgery were 26.3 (4.0) and 18.3 (2.7) mm, respectively, with a significant decrease and significant 5.5 (3.3)-mm change from baseline in decompressed orbits (both $P < 0.001$). Diplopia was reported in 29% ($n = 10$) of patients < 2 months postoperatively.

Conclusions: Emergency or elective orbital decompression significantly reduced exophthalmos in patients with TED within 1 year postoperatively. Three-wall orbital decompression produced the more immediate impact, while two-wall orbital decompression showed the higher effect at a later timepoint. The most common complication was diplopia, while other serious complications occurred infrequently. Further prospective comparative studies involving more participants and longer postoperative follow-up periods are required to verify these preliminary findings.

KEYWORDS

surgical decompression, Graves orbitopathy, thyroid eye diseases, optic neuropathy, visual acuities, diplopias, double vision, urgent, elective surgical procedure

Correspondence: Kouros Shahraki, Labbafinejad Medical Center, Boostan 9 Street, Pasdaran Avenue, Tehran, Iran. Email: kouros.shahyar@gmail.com. ORCID iD: <https://orcid.org/0000-0001-9754-2284>

How to cite this article: Shahraki K, Tavakoli M, Khosravifard K, Aletaha M, Salour H. Outcomes of orbital decompression for thyroid eye disease over a 10-year period at a tertiary eye care referral center. *Med Hypothesis Discov Innov Optom*. 2023 Fall; 4(3): 121-128. DOI: <https://doi.org/10.51329/mehdiptometry181>

Received: 01 August 2023; Accepted: 25 September 2023



Copyright © Author(s). This is an open-access article distributed under the terms of the Creative Commons Attribution-NonCommercial 4.0 International License (<https://creativecommons.org/licenses/by-nc/4.0/>) which permits copy and redistribute the material just in noncommercial usages, provided the original work is properly cited.



INTRODUCTION

Thyroid eye disease (TED) is an autoimmune disease characterized by orbital inflammation, fibrosis, and hypertrophy of the orbital fat and extraocular muscles, with subsequent proptosis, motility restriction, eyelid retraction, lagophthalmos, and exposure keratopathy [1, 2]. Although it is often self-limiting, patients with active or inactive TED may require medical or surgical treatment interventions [1, 3]. Nonsurgical management includes lifestyle modifications, treatment of dry eye syndrome, oral or intravenous steroid administration in the active inflammatory phase, biological agents (e.g., teprotumumab), and orbital radiation [1, 4].

However, medical intervention may not suffice or yield the desired outcomes, and orbital decompression may be imperative [5]. Orbital decompression is indicated in sight-threatening conditions, such as compressive optic neuropathy or severe exposure keratopathy caused by exophthalmos. Other indications include incapacitating diplopia, necessitating strabismus surgery; visually displeasing proptosis; persistent retrobulbar pain; globe subluxation; and unregulated intraocular pressure [5, 6].

Orbital decompression includes the removal or carving of the bony orbital walls and removal of orbital fat, which relieves pressure from the optic nerve and improve exophthalmos by expanding the orbital volume [6-8]. Several decompression techniques have been introduced in previous decades, including lateral wall removal, the transcoronal approach, balanced endoscopic medial wall orbital decompression, and fat decompression [9, 10]. The overall postoperative complication rate is 9.3% [11]. Immediate complications include periorbital ecchymosis, erythema and swelling, intraoperative and postoperative hemorrhages, and infectious cellulitis [2, 11]. Vision loss resulting from retrobulbar hemorrhage is a rare complication. Additionally, sinusitis, cerebrospinal fluid leakage, hematoma, facial paresthesia or hypoesthesia, and new-onset diplopia are potential side effects [11, 12].

This study aimed to evaluate the outcomes of different orbital decompression techniques for treating TED and to compare the results of emergency and elective orbital decompression surgeries.

METHODS

In this cross-sectional study, we recruited patients with TED who had undergone either emergency or elective orbital decompression surgery at a tertiary eye care referral center in the Labbafinejad Hospital in Tehran, Iran, between March 2010 and March 2020. The study protocol was approved by the Scientific and Ethical Board Committee of the Shahid Beheshti University of Medical Sciences. The study procedures adhered to the tenets of the Declaration of Helsinki. Written informed consent was obtained from patients following a complete explanation of the process. Informed consent for the surgery was obtained from all included patients.

All medical records were reviewed. A total of 318 patients had undergone orbital surgery for reasons such as a tumor, a fracture, a trauma, or an inflammatory or infectious disease. We recruited those with TED who had undergone emergency or elective orbital decompression followed by a 1-year follow-up and had documented demographic and clinical profiles, examination findings, and exophthalmometry readings and recorded complications preoperatively and postoperatively. We excluded the patients who had a history of orbital decompression, maxillofacial surgery, facial trauma, orbital irradiation, orbital or strabismus surgery, or inadequate postoperative follow-up. From medical records, we extracted the information on surgical indications and techniques, previous treatment, smoking habits, duration of symptoms, subsequent muscle surgery, and various preoperative and postoperative parameters. The study flowchart is detailed in Figure 1.

The participants underwent complete ophthalmological examinations at baseline and every visit during the 1-year postoperative follow-up, including measurement of the best-corrected distance visual acuity using a Snellen chart (auto chart projector CP 670; Nidek Co., Ltd., Gamagori, Japan), exophthalmometry reading with the Hertel exophthalmometer (Oculus, Woodinville, WA, USA), intraocular pressure measurement using the Goldmann applanation tonometer (AT900, Haag-Streit, Koeniz, Switzerland), and undilated and dilated slit-lamp biomicroscopic examinations (Photo-Slit Lamp BX 900; Haag-Streit, Koeniz, Switzerland), dilated fundus examinations using indirect ophthalmoscopy (Keeler Instrument Inc., Philadelphia, PA, USA) with the aid of an accessory noncontact lens + 20 D (Volk Optical Inc., Mentor, OH, USA), and a complete orthoptic evaluation as outlined elsewhere [13].

The clinical activity score (CAS) was recorded according to the European Group on Graves' Orbitopathy guidelines [14], and 21 patients with a CAS ≥ 3 were diagnosed with active TED. Orbital computed tomography was performed with a bone window and 1.5-mm slices for all patients [15], and the surgery was planned accordingly. Patients were examined 1 week and 1, 3, 6, and 12 months postoperatively. Data from the 1-year visit were considered the postoperative outcomes.

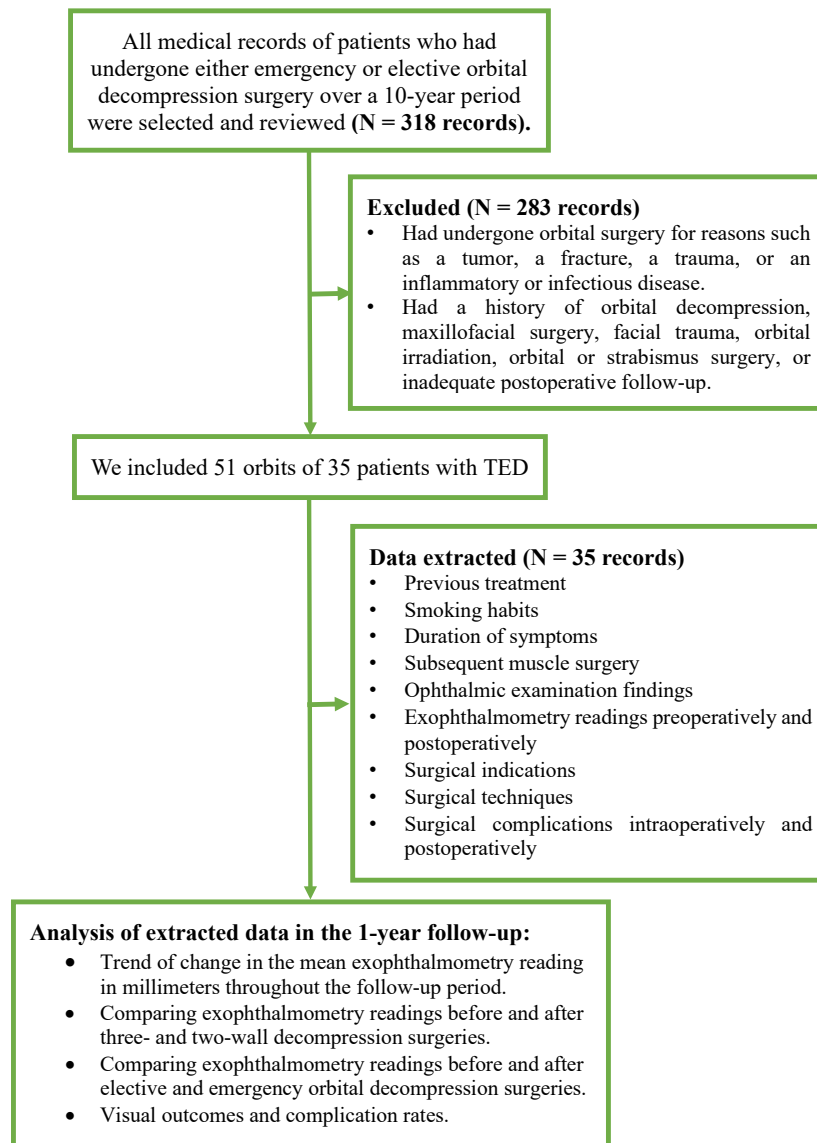


Figure 1. Flow diagram of the study process. Abbreviations: N, number; TED, thyroid eye disease. Note: The term “two-wall” refers to orbital decompression by removal of orbital fat and two bony walls, i.e., the inferior and medial orbital walls; The term “three-wall” refers to orbital decompression by removal of orbital fat and three bony walls, i.e., the inferior, medial, and lateral orbital walls; The term “elective” refers to elective orbital decompression performed for the eyes with proptosis secondary to TED; The term “emergency” refers to emergency orbital decompression performed for the eyes with reduced vision secondary to TED.

Statistical analyses were performed using SPSS for Windows version 18.0 (SPSS Inc., Chicago, Ill., USA). The Shapiro – Wilk test was performed to assess the normality of data distribution. The chi-squared test was performed to compare the categorical variables. The *t*-test and analysis of variance (ANOVA) were performed to compare independent groups. The paired *t*-test was performed to compare each postoperative follow-up value with its corresponding baseline value within each group. The repeated-measures ANOVA or mixed-effects model was utilized to assess trends across multiple follow-up periods. *P*-values < 0.05 indicated statistical significance.

RESULTS

Of 318 decompressed orbits detected in the 10-year period, we included 51 orbits of 35 patients (Figure 1) with TED with a mean (standard deviation [SD]) age of 36.2 (12.0) years and male-to-female ratio of 23 (66%) / 12 (34%). Table 1 summarizes the demographic and clinical characteristics of the patients.

At 1 year postoperatively, 25 (71%) patients had experienced multiple lines (≥ 2 lines) of improvement in vision bilaterally ($P=0.100$); eight (23%) patients had maintained their baseline vision; and two (6%) patients had experienced a slight deterioration in vision by $<$ one line. At the final follow-up, 28 (80%) patients demonstrated normal visual acuity (20/20) in both eyes.

The mean (SD) exophthalmometry readings in all participants before and 1 year postoperatively were 26.3 (4.0) and 18.3 (2.7) mm, respectively, with a significantly decreasing trend during the 1-year follow-up period ($P < 0.001$; Figure 2) and significant 5.5 (3.3)-mm change from baseline in decompressed orbits ($P < 0.001$).

Table 1. Demographic and clinical characteristics of the included patients with thyroid eye disease in a 10-year period who had undergone orbital decompression surgery

Variables (n = 51 eyes of 35 patients)	Values
Age (y), Mean \pm SD (Range)	36.2 \pm 12.0 (15 to 63)
Sex (Male / Female), n (%)	23 (66) / 12 (34)
Preoperative thyroid status (Hyperthyroidism / Hypothyroidism), n (%)	29 (83) / 6 (17)
Cause of orbital decompression (Elective / Emergency), n (%)	27 (77) / 8 (23)
Time interval between the diagnosis and surgery (months), Mean \pm SD (Range)	41.0 \pm 39.0 (4 to 120)
Baseline visual acuity (decimal) ($\geq 8/10$ / $3/10 - 7/10$ / $\leq 2/10$)	22 (43) / 21 (41) / 8 (16)
Laterality of the operated eye (Right / Left / Bilateral), n (%)	15 (43) / 4 (11) / 16 (46)
History of treatment for Grave's disease (Iodine + Corticosteroids / Corticosteroids / None)	17 (49) / 14 (40) / 4 (11)
Smoking status (Current-smoker / Never-smoker / Ex-smoker), n (%)	21 (60) / 14 (40) / 0 (0)
Clinical activity score (All / Elective / Emergency), Mean \pm SD	4.2 \pm 1.7 / 3.5 \pm 1.5 / 5.8 \pm 1.3
Surgical method (Fat / Fat + One wall / Fat + Two walls / Fat + Three walls), n (%)	1 (2) / 2 (4) / 43 (84) / 5 (10)
Other operations within the follow-up period (total: 37 eyes; Mullerectomy / Lower lid recess / Upper lid recess / Strabismus surgery / Hypoglobose repair), n (%)	14 (38) / 14 (38) / 6 (16) / 2 (5) / 1 (3)

Abbreviations: n, number; y, years; SD, standard deviation; %, percentage. Note: Right, refers to the right eye; Left, refers to the left eye; Bilateral, refers to the both eyes; None, refers to no history of treatment for Grave's disease; The term "elective" refers to elective orbital decompression performed for the eyes with proptosis secondary to thyroid eye disease; The term "emergency" refers to emergency orbital decompression performed for the eyes with reduced vision secondary to thyroid eye disease; The term "fat" refers to orbital decompression by removal of orbital fat; The term "fat + one wall" refers to orbital decompression by removal of orbital fat combined with inferior bony wall removal; The term "fat + two walls" refers to orbital decompression by removal of orbital fat and two bony walls, i.e., the inferior and medial orbital walls; The term "fat + three walls" refers to orbital decompression by removal of orbital fat and three bony walls, i.e., the inferior, medial, and lateral orbital walls.

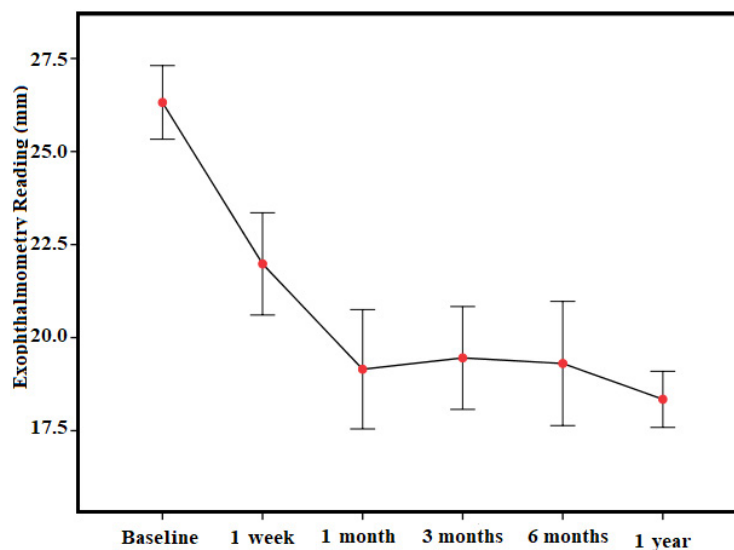


Figure 2. Trend of change in the mean exophthalmometry reading in millimeters throughout the follow-up period from preoperative baseline to 1 week, 1, 3, and 6 months, and 1 year postoperatively in all included decompressed orbits. Note: The error bars show the 95% confidence interval of the mean, and red dots show the mean.

At baseline and 1 week, 1, 3, and 6 months, and 1 year postoperatively, the mean (SD) exophthalmometry readings differed significantly between the eyes that had undergone two- and three-wall orbital decompression surgeries (all $P < 0.05$; Table 2). Although exophthalmometry readings were significantly high at the baseline, they remained significantly lower postoperatively in the eyes that had undergone three-wall orbital decompression than in the eyes that had undergone two-wall orbital decompression (all $P < 0.05$; Table 2). Compared to the baseline readings, the eyes that had undergone three-wall orbital decompression showed a significant reduction in the exophthalmometry reading 1 week and 1 and 3 months postoperatively, and eyes that had undergone two-wall orbital decompression showed a significant reduction in the exophthalmometry reading 3 months, 6 months, and 1 year postoperatively (all $P < 0.001$; Table 2). Thus, postoperative improvement occurred with three-wall orbital decompression earlier than it did with two-wall orbital decompression. The maximum effects of three- and two-wall decompression surgeries in terms of improvement in proptosis occurred 1 and 3 months postoperatively, respectively (Table 2).

Ten (20%) eyes of eight (23%) patients required emergency surgical decompression. Of them, four (40%), four (40%), and two (20%) had compressive optic neuropathy, exposure keratopathy, and combined optic neuropathy and exposure keratopathy, respectively. On admission, all patients received 1 g of intravenous methylprednisolone (Aburaihan Pharmaceutical Co., Tehran, Iran) daily for 5 days before the surgical decompression. Despite a significantly higher baseline mean (SD) exophthalmometry reading in emergency cases, the exophthalmometry reading had become significantly lower at the 6-month postoperative follow-up (both $P < 0.05$) and comparable at the final 1-year follow-up with the exophthalmometry reading of electively decompressed orbits ($P > 0.05$; Table 3). However, compared to the baseline readings, the mean (SD) exophthalmometry readings had decreased significantly with emergency and elective orbital decompression surgeries at all postoperative follow-ups (all $P < 0.001$; Table 3).

Diplopia emerged as the prevailing early postoperative complication at < 2 months postoperatively, affecting 10 (29%) patients, with vertical diplopia in the primary position being the most frequent pattern ($n = 5$), followed by torsional diplopia ($n = 2$), horizontal diplopia ($n = 2$), and both vertical and horizontal diplopia ($n = 1$). Other complications that had been infrequent across all surgical techniques included permanent hypoesthesia due to injury to the maxillary branch of the trigeminal nerve ($n = 1$), intraoperative hemorrhage ($n = 1$), and postoperative hemorrhage necessitating further surgical intervention ($n = 1$). Thirty-seven eyes required additional subsequent surgeries within the 1-year follow-up (Table 1). The mean (SD; range) interval between the first and second surgeries was 5.2 (3.2; 1 – 12) months.

Table 2. Exophthalmometry readings before and after three- and two-wall decompression surgeries in the 1-year follow-up

Time point	Three-wall (mm), Mean \pm SD, Median (Range)	Two-wall (mm), Mean \pm SD, Median (Range)	P-value
Baseline	26.9 \pm 3.9, 26 (20 to 38)	24.4 \pm 4.0, 25 (16 to 29)	$P_2 = 0.002$
1 week	21.6 \pm 3.3, 21 (18 to 30)	24.0 \pm 3.0, 24 (16 to 26)	$P_2 < 0.001$
	$P_1 < 0.001$	$P_1 = 0.456$	
1 month	17.8 \pm 2.1, 18 (15 to 23)	24.5 \pm 2.1, 25 (22 to 27)	$P_2 < 0.001$
	$P_1 < 0.001$	$P_1 = 0.766$	
3 months	17.6 \pm 2.8, 17 (14 to 23)	20.3 \pm 4.1, 20 (15 to 28)	$P_2 = 0.037$
	$P_1 < 0.001$	$P_1 < 0.001$	
6 months	17.5 \pm 1.4, 16 (15 to 23)	19.0 \pm 3.4, 19 (15 to 27)	$P_2 < 0.001$
	$P_1 = 0.667$	$P_1 < 0.001$	
1 year	17.6 \pm 2.6, 17 (15 to 25)	17.6 \pm 2.9, 17 (14 to 23)	$P_2 < 0.001$
	$P_1 = 0.743$	$P_1 < 0.001$	

Abbreviations: mm, millimeter; SD, standard deviation. Note: P -values < 0.05 are shown in bold; P_1 , P -value for the comparison between the preoperative and 1-week, 1-, 3-, and 6-month and 1-year postoperative exophthalmometry readings; P_2 , P -value for the comparison of the exophthalmometry reading between two- and three-wall decompression surgeries at specific time points; The term “two-wall” refers to orbital decompression by removal of orbital fat and two bony walls, i.e., the inferior and medial orbital walls; The term “three-wall” refers to orbital decompression by removal of orbital fat and three bony walls, i.e., the inferior, medial, and lateral orbital walls.

Table 3. Exophthalmometry readings before and after elective and emergency orbital decompression surgeries in the 1-year follow-up

Time point	Elective (mm), Mean \pm SD, Median (Range)	Emergency (mm), Mean \pm SD, Median (Range)	P-value
Baseline	25.6 \pm 3.4, 26 (16 to 32)	29.1 \pm 4.9, 28 (23 to 38)	$P_2 = 0.002$
1 week	22.3 \pm 3.6, 22 (18 to 30)	20.0 \pm 1.2, 20 (19 to 21)	$P_2 = 0.285$
	$P_1 < 0.001$	$P_1 < 0.001$	
1 month	19.6 \pm 3.7, 19 (15 to 27)	17.5 \pm 1.7, 18 (15 to 19)	$P_2 = 0.562$
	$P_1 < 0.001$	$P_1 < 0.001$	
3 months	19.2 \pm 3.6, 19 (14 to 27)	20.1 \pm 4.7, 19 (15 to 28)	$P_2 = 0.515$
	$P_1 < 0.001$	$P_1 < 0.001$	
6 months	18.4 \pm 2.5, 19 (15 to 23)	22.5 \pm 4.4, 23 (17 to 27)	$P_2 = 0.033$
	$P_1 < 0.001$	$P_1 < 0.001$	
1 year	18.6 \pm 2.8, 18 (14 to 25)	17.5 \pm 2.3, 17 (14 to 21)	$P_2 = 0.524$
	$P_1 < 0.001$	$P_1 < 0.001$	

Abbreviations: mm, millimeter; SD, standard deviation. Note: P -values < 0.05 are shown in bold; P_1 , P -value for the comparison of the exophthalmometry reading between the preoperative baseline and 1 week, 1, 3, and 6 months, and 1 year postoperatively in elective or emergency cases of orbital decompression surgery; P_2 , P -value for the comparison of the exophthalmometry reading between elective and emergency cases of orbital decompression surgery at specific time points; The term “elective” refers to elective orbital decompression performed for the eyes with proptosis secondary to thyroid eye disease; The term “emergency” refers to emergency orbital decompression performed for the eyes with reduced vision secondary to thyroid eye disease.

DISCUSSION

In the present study, the mean exophthalmometry reading decreased significantly from 26.3 mm at baseline to 18.3 mm postoperatively in all decompressed orbits with TED. Three-wall decompression produced better outcomes in the early postoperative period compared to those associated with two-wall decompression. Emergency orbital decompression was performed in 23% of the patients and yielded an exophthalmometry reading comparable to that associated with elective orbit decompression at the 1-year follow-up.

Orbital decompression is the primary rehabilitative surgery for patients with TED [16]. Decompression is achieved by removing the orbital fat, the bony wall, or both. Emergency or elective orbital decompression may be indicated for TED [12]. Indications for emergency orbital decompression include compressive optic neuropathy, globe subluxation, and severe exposure keratopathy, with or without corneal ulceration [3, 6]. The incidence of compressive optic neuropathy in patients with TED ranges from 2% to 9% [5-7]. In the present study, ten orbits of eight patients were treated with emergency orbital decompression because of compressive optic neuropathy, severe exposure keratopathy, or both.

The optimal approach for managing dysthyroid optic neuropathy is the administration of high-dose systemic steroids accompanied by timely surgical decompression when medical intervention proves ineffective [17-19]. In our practice, we implement a specific protocol involving the intravenous administration of 1 g / day of methylprednisolone for 5 days. This treatment strategy aims to ensure expedited surgical decompression in patients not responding satisfactorily to medical treatment. Although the mean exophthalmometry readings were significantly higher in emergency cases preoperatively, no postoperative follow-ups except the 6-month follow-up showed significant differences; at that time point, emergency cases had significantly a lower reading. A possible mechanism is the use of steroid pulse therapy preoperatively in the emergency group, which further reduces proptosis [1].

Elective orbital decompression can be considered for patients requiring rehabilitation for double vision, disfiguring proptosis, or cosmetic issues [20, 21], with monitoring for at least 6 months preoperatively to ensure that orbitopathy is inactive and stable [5, 6]. In the present study, most (77%) patients underwent elective orbital decompression and showed significant improvements in proptosis at all follow-ups compared to that at baseline. However, at the final 1-year follow-up, the exophthalmometry reading was comparable to those of eyes that had undergone emergency orbital decompression, although with a slightly higher mean value (18.6 versus 17.5 mm).

Orbital decompression primarily aims to reduce proptosis [22]. Decompression of the medial and inferior bony walls of the orbit reduces proptosis by 4.4 – 4.7 mm [12]. In the present study, proptosis was reduced by approximately 5 mm with decompression for two-wall bony orbital removal. Medial wall decompression

improves proptosis better than lateral wall decompression does. Furthermore, the transantral approach improves proptosis better than the endoscopic approach does [23, 24]. In the present study, proptosis reduced significantly with both elective and emergency orbital decompression surgeries and two- and three-wall bony orbital removal decompression techniques throughout the 1-year postoperative follow-up period. O'Malley and Meyer reported a maximum reduction in exophthalmos of 8 mm using Hertel exophthalmometry up to 4 months after transconjunctival fat removal with conservative medial wall/floor orbital decompression in eyes with TED [25]. Similarly, we detected an 8-mm improvement in the mean exophthalmometry reading at the 1-year follow-up in all eyes.

As the indications for surgical decompression for TED have expanded, interest has increased in developing minimally invasive surgical approaches offering improved postoperative cosmetics and diplopia [23, 24]. Although several surgical techniques have been introduced, none have been deemed superior to the others [11, 12]. Therefore, the surgical method is selected according to the patient's condition and expectations and the surgeon's preference and experience [7, 26]. In the present study, over 84% of the included eyes underwent orbital decompression surgery by removal of orbital fat and two bony walls, i.e., the inferior and medial orbital walls.

After orbital decompression, the visual acuity improves, remains stable, and worsens in 44% – 55%, 27% – 36%, and 18% – 20% of patients, respectively [7, 27]. Decompression for compressive optic neuropathy shows the greatest improvement, with 82% – 88% of the patients demonstrating improved postoperative vision [9, 11, 12, 27]. In the present study, although visual acuity improved 1 year postoperatively compared to that baseline, the difference was not significant. At the final follow-up, 28 (80%) patients demonstrated normal visual acuity (20/20) in both eyes.

According to a systematic review, the overall complication rate after orbital decompression is 9.3% [11]. Orbital decompression improves diplopia in 28.1% of patients; however, surgery can induce new diplopia in 29.7% of patients [11]. Opening the periorbital tissue and removing the posterior medial wall and inferomedial orbital strut are associated with an increased risk of postoperative diplopia [12]. In the present study, diplopia was the most common complication, reported in 29% of the patients, consistent with previous studies reporting that diplopia is the most common complication of orbital decompression [11, 12]. Balanced orbital decompression causes less severe diplopia compared to that associated with other techniques. The onset or worsening of diplopia occurs in 10% – 20% of cases with this technique [10]. In the present study, diplopia was often transient and required strabismus surgery in only 5% of the cases.

This study conducted at a tertiary eye care referral center over a 10-year period revealed significantly improved exophthalmometry readings following elective or emergency orbital decompression in the eyes with TED. The limitations of this study include its retrospective and nonrandomized design, lack of standardization of the adjuvant medical therapy, and relatively small sample size. Larger randomized studies with longer follow-up durations are required to compare the safety, efficacy, and complications of orbital decompression techniques across clinical settings.

CONCLUSIONS

This study highlighted the effectiveness of orbital decompression in improving exophthalmometric readings in patients with TED. Three-wall orbital decompression produced the more immediate impact, while two-wall orbital decompression showed the higher effect at a later timepoint. Despite the requirement of emergency surgery in some cases, the exophthalmometry readings did not differ significantly between emergency and elective surgeries at the 1-year follow-up. These results provide valuable insight into the outcomes and complications of orbital surgery, including clinical decision-making and patient management strategies. However, larger randomized studies with longer follow-up durations are required to compare the safety, efficacy, and complications of orbital decompression techniques across clinical settings to verify our preliminary outcomes.

ETHICAL DECLARATIONS

Ethical approval: The study protocol was approved by the Scientific and Ethical Board Committee of the Shahid Beheshti University of Medical Sciences. The study procedures adhered to the tenets of the Declaration of Helsinki. Written informed consent was obtained from patients following a complete explanation of the process. Informed consent for the surgery was obtained from all included patients.

Conflict of interests: None.

FUNDING

None.

ACKNOWLEDGMENTS

This paper is dedicated to our mentor and coworker, the late Professor Abbas Bagheri.

REFERENCES

- Shahraki K, Pak VI, Najafi A, Shahraki K, Boroumand PG, Sheervalilou R. Non-coding RNA-mediated epigenetic alterations in Grave's ophthalmopathy: A scoping systematic review. *Noncoding RNA Res.* 2023;8(3):426-450. doi: 10.1016/j.ncrna.2023.04.001 pmid: 37324526
- Ben Simon GJ, Katz G, Zloto O, Leiba H, Hadas B, Huna-Baron R. Age differences in clinical manifestation and prognosis of thyroid eye disease. *Graefes Arch Clin Exp Ophthalmol.* 2015;253(12):2301-8. doi: 10.1007/s00417-015-3156-2 pmid: 26344731
- Boboridis KG, Bunce C. Surgical orbital decompression for thyroid eye disease. *Cochrane Database Syst Rev.* 2011;(12):CD007630. doi: 10.1002/14651858.CD007630.pub2 pmid: 22161415
- Kossler AL, Douglas R, Dosiou C. Teprotumumab and the Evolving Therapeutic Landscape in Thyroid Eye Disease. *J Clin Endocrinol Metab.* 2022;107(Suppl_1):S36-S46. doi: 10.1210/clinem/dgac168 pmid: 36346685
- Baeg J, Choi HS, Kim C, Kim H, Jang SY. Update on the surgical management of Graves' orbitopathy. *Front Endocrinol (Lausanne).* 2023;13:1080204. doi: 10.3389/fendo.2022.1080204 pmid: 36824601
- Parrilla C, Mele DA, Gelli S, Zelano L, Bussu F, Rigante M, et al. Multidisciplinary approach to orbital decompression. A review. *Acta Otorhinolaryngol Ital.* 2021;41(Suppl. 1):S90-S101. doi: 10.14639/0392-100X-suppl.1-41-2021-09 pmid: 34060524
- Braun TL, Bhadkamkar MA, Jubbal KT, Weber AC, Marx DP. Orbital Decompression for Thyroid Eye Disease. *Semin Plast Surg.* 2017;31(1):40-45. doi: 10.1055/s-0037-1598192 pmid: 28255288
- Bagheri A, Shahraki K, Tavakoli M. Optic Disc Deformation and Orbital Bone Erosion Secondary to a Huge Neglected Orbital Cavernous Hemangioma. *J Craniofac Surg.* 2018;29(8):e790-e792. doi: 10.1097/SCS.00000000000004777 pmid: 30277940
- Burch HB, Perros P, Bednarczuk T, Cooper DS, Dolman PJ, Leung AM, et al. Management of thyroid eye disease: a Consensus Statement by the American Thyroid Association and the European Thyroid Association. *Eur Thyroid J.* 2022;11(6):e220189. doi: 10.1530/ETJ-22-0189 pmid: 36479875
- Costan VV, Ciocan-Pendefunda CC, Ciofu ML, Boisteanu O, Timofte DV, Gheorghe L, et al. Balancing orbital volume reduction and redistribution for a tailored surgical treatment in Graves' ophthalmopathy. *Graefes Arch Clin Exp Ophthalmol.* 2020;258(10):2313-2320. doi: 10.1007/s00417-020-04807-4 pmid: 32588167
- Leong SC, Karkos PD, Macewen CJ, White PS. A systematic review of outcomes following surgical decompression for dysthyroid orbitopathy. *Laryngoscope.* 2009;119(6):1106-15. doi: 10.1002/lary.20213 pmid: 19358198
- Cubuk MO, Konuk O, Unal M. Orbital decompression surgery for the treatment of Graves' ophthalmopathy: comparison of different techniques and long-term results. *Int J Ophthalmol.* 2018;11(8):1363-1370. doi: 10.18240/ijo.2018.08.18 pmid: 30140642
- Elangovan N, Bangalore Muniyappa Shanmugham D. Binocular vision parameters and body mass index. *Med Hypothesis Discov Innov Optom.* 2023; 4(1): 17-24. doi: 10.51329/mehdiptometry169
- Bartalena L, Baldeschi L, Boboridis K, Eckstein A, Kahaly GJ, Marcocci C, et al; European Group on Graves' Orbitopathy (EUGOGO). The 2016 European Thyroid Association/European Group on Graves' Orbitopathy Guidelines for the Management of Graves' Orbitopathy. *Eur Thyroid J.* 2016;5(1):9-26. doi: 10.1159/000443828 pmid: 27099835
- Rajabi MT, Tabary M, Baharnoori S, Salabati M, Mahmoudzadeh R, Hosseinzadeh F, et al. Orbital anatomical parameters affecting outcome of deep lateral orbital wall decompression. *Eur J Ophthalmol.* 2021;31(4):2069-2075. doi: 10.1177/1120672120941433 pmid: 32627588
- Victores AJ, Takashima M. Thyroid Eye Disease: Optic Neuropathy and Orbital Decompression. *Int Ophthalmol Clin.* 2016;56(1):69-79. doi: 10.1097/HIO.000000000000101 pmid: 26626933
- Saeed P, Tavakoli Rad S, Bisschop PHLT. Dysthyroid Optic Neuropathy. *Ophthalmic Plast Reconstr Surg.* 2018;34(4S Suppl 1):S60-S67. doi: 10.1097/IOP.0000000000001146 pmid: 29927882
- Pelewicz M, Rymuza J, Pelewicz K, Miśkiewicz P. Dysthyroid Optic Neuropathy: Treatment with Additional Intravenous Methylprednisolone Pulses after the Basic Schedule Is Associated with Stabilization or Further Improvement of Clinical Outcome. *J Clin Med.* 2022;11(8):2068. doi: 10.3390/jcm11082068 pmid: 35456161
- Tagami M, Honda S, Azumi A. Insights into Current Management Strategies for Dysthyroid Optic Neuropathy: A Review. *Clin Ophthalmol.* 2022;16:841-850. doi: 10.2147/OPH.S284609 pmid: 35330749
- Fichter N, Guthoff RF, Schittkowski MP. Orbital decompression in thyroid eye disease. *ISRN Ophthalmol.* 2012;2012:739236. doi: 10.5402/2012/739236 pmid: 24558591
- Verity DH, Rose GE. Acute thyroid eye disease (TED): principles of medical and surgical management. *Eye (Lond).* 2013;27(3):308-19. doi: 10.1038/eye.2012.284 pmid: 23412559
- Sellari-Franceschini S, Rocchi R, Marinò M, Bajraktari A, Mazzi B, Fiacchini G, et al. Rehabilitative orbital decompression for Graves' orbitopathy: results of a randomized clinical trial. *J Endocrinol Invest.* 2018;41(9):1037-1042. doi: 10.1007/s40618-018-0847-7 pmid: 29450866
- Ye Y, Hu F, Ji Y, Wang R, Zhu K, Kong Q. The outcomes of endoscopic orbital decompression combined with fat decompression for thyroid-associated ophthalmopathy. *BMC Ophthalmol.* 2023;23(1):217. doi: 10.1186/s12886-023-02957-7 pmid: 37193956
- Hainăroşie R, Ioniţă I, Pietroşanu C, Pişuru S, Hainăroşie M, Zainea V. Transnasal endoscopic orbital decompression. *Rom J Ophthalmol.* 2017;61(3):192-195. doi: 10.22336/rjo.2017.35 pmid: 29450397
- O'Malley MR, Meyer DR. Transconjunctival fat removal combined with conservative medial wall/floor orbital decompression for Graves orbitopathy. *Ophthalmic Plast Reconstr Surg.* 2009;25(3):206-10. doi: 10.1097/IOP.0b013e3181a424cc pmid: 19454932
- DeParise SW, Tian J, Rajaii F. Practice Patterns in Orbital Decompression Surgery Among American Society of Ophthalmic Plastic and Reconstructive Surgery Members. *Ophthalmol Ther.* 2019;8(4):541-548. doi: 10.1007/s40123-019-00206-z pmid: 31422554
- Jernfors M, Välimäki MJ, Setälä K, Malmberg H, Laitinen K, Pitkäranta A. Efficacy and safety of orbital decompression in treatment of thyroid-associated ophthalmopathy: long-term follow-up of 78 patients. *Clin Endocrinol (Oxf).* 2007;67(1):101-7. doi: 10.1111/j.1365-2265.2007.02845.x pmid: 17466006