



# Visual rehabilitation with scleral lenses after corneal transplantation

Fatemeh Riazi<sup>1</sup>, Mostafa Naderi<sup>1</sup>, Seyed-Hashem Daryabari<sup>2</sup> and Abbas Riazi<sup>3</sup>

<sup>1</sup> Bina Eye Hospital, Tehran, Iran

<sup>2</sup> Dida Eye Research Center, Bushehr, Iran

<sup>3</sup> Department of Optometry, School of Rehabilitation, Iran University of Medical Sciences, Tehran, Iran

## ABSTRACT

**Background:** Patients undergoing corneal transplantation often present with high astigmatism and corneal irregularity, making conventional contact lens fitting difficult and limiting tolerance to standard optical correction. We aimed to evaluate the effect of scleral lens fitting on visual rehabilitation in patients following lamellar or penetrating keratoplasty by assessing visual acuity, contrast sensitivity, and patient satisfaction.

**Methods:** Patients who had undergone keratoplasty and were considered suitable candidates for scleral lens fitting were enrolled in this prospective interventional study. All participants underwent comprehensive ophthalmic and optometric examinations prior to lens fitting. Visual acuity and contrast sensitivity were measured using a standard Snellen visual acuity chart and the Melbourne Edge Test under standardized back-illuminated conditions, with results recorded in decimal notation and decibels (dB), respectively. Refractive error was assessed by autorefractometry, followed by over-refraction and subjective and objective refinement to determine the final lens power. Diagnostic fitting was performed using trial scleral lenses, and anterior segment optical coherence tomography was utilized to assess lens fit. Visual and refractive parameters were recorded before and after optimal scleral lens fitting. Patient-reported satisfaction was assessed 1–2 weeks after lens dispensing using a 0–10 subjective rating scale, where scores 8–10 indicated complete satisfaction, 5–7 satisfaction, 2–4 dissatisfaction, and 0–1 complete dissatisfaction.

**Results:** Eighteen eyes of 12 post-keratoplasty patients, 7 (58%) men and 5 (42%) women, were evaluated. Mean (standard deviation [SD], range) age was 45.6 (3.9, 22–67) years. Mean (SD) visual acuity improved significantly from 0.15 (0.12) decimal before lens fitting to 0.77 (0.33) decimal after scleral lens wear ( $P < 0.001$ ). Mean contrast sensitivity increased significantly from 14.55 (3.82) dB to 20.33 (2.35) dB following scleral lens fitting ( $P < 0.001$ ). All patients reported satisfaction with scleral lens wear, including complete satisfaction in nine (75%) patients and satisfaction in three (25%) patients.

**Conclusions:** Post-keratoplasty ametropia and irregular astigmatism frequently limit visual rehabilitation with conventional optical correction methods. Scleral lenses offer an effective approach for correcting postoperative refractive irregularities and significantly enhance visual acuity and contrast sensitivity, while yielding high patient satisfaction at two weeks after lens fitting.

## KEYWORDS

corneal transplantations, penetrating keratoplasty, lamellar keratoplasty, contact lens, visual contrast sensitivity, visual acuities, satisfaction, patient

**Correspondences:** Abbas Riazi, School of Rehabilitation Sciences, Iran University of Medical Sciences, Mirdamad Blvd., Tehran 15875-4391, Iran. Email: [abbas.riazi@gmail.com](mailto:abbas.riazi@gmail.com). ORCID iD: <https://orcid.org/0000-0002-1616-9017>.

**How to cite this article:** Riazi F, Naderi M, Daryabari SH, Riazi A. Visual rehabilitation with scleral lenses after corneal transplantation. Med Hypothesis Discov Innov Optom. 2026 Spring; 7(1): 1-7. DOI: <https://doi.org/10.51329/mehdiptometry239>.

Received: 13 January 2026; Accepted: 08 April 2026



Copyright © Author(s). This is an open-access article distributed under the terms of the Creative Commons Attribution-NonCommercial 4.0 International License (<https://creativecommons.org/licenses/by-nc/4.0/>) which permits copy and redistribute the material just in noncommercial usages, provided the original work is properly cited.



## INTRODUCTION

Keratoplasty remains a definitive surgical treatment for a broad range of corneal pathologies, with multiple surgical techniques available to restore corneal transparency and integrity [1]. Despite satisfactory graft clarity, postoperative corneal irregularity and residual refractive error frequently limit visual outcomes after keratoplasty and may not be adequately corrected with conventional optical modalities such as spectacles, soft contact lenses, or corneal rigid gas-permeable lenses [2].

Contact lens fitting is therefore integral to visual rehabilitation in post-keratoplasty eyes [3]. Available modalities include large-diameter multicurve rigid-gas permeable lenses, rigid gas permeable corneal contact lenses, scleral lenses, hydrogel lenses, hybrid lenses, and piggyback lenses [2, 4, 5]. However, postoperative high astigmatism, surface irregularity, and forward protrusion of the cornea often complicate fitting with conventional lens designs and contribute to lens intolerance [2, 6].

Scleral lenses have emerged as an effective option for managing irregular corneas, including post-surgical corneal ectasia. By vaulting the cornea and maintaining a fluid reservoir over the ocular surface, scleral lenses create a smooth refractive interface that improves optical quality while protecting the corneal epithelium [7–9]. Their high-oxygen-permeable materials further support corneal physiology during wear. Accordingly, scleral lenses may provide superior visual rehabilitation in post-keratoplasty eyes while reducing the need for additional surgical intervention [7–9].

The present study evaluated the effectiveness of scleral lenses for visual rehabilitation after keratoplasty by assessing visual acuity, contrast sensitivity, and patient-reported satisfaction following scleral lens fitting.

## METHODS

This prospective, single-arm, before-after interventional clinical study (Figure 1) was conducted at a tertiary ophthalmic center between 2025 and 2026 to evaluate the effect of scleral lens fitting on visual rehabilitation following penetrating or lamellar keratoplasty. Patients referred by a cornea subspecialist for scleral lens fitting were consecutively enrolled. The study was registered in the Iranian Registry of Clinical Trials (IRCT20251210068270N1; approval date: December 20, 2025) and approved by the institutional ethics committee (IR.BMSU.BLC.1404.099). All procedures adhered to the tenets of the Declaration of Helsinki, and written informed consent was obtained from all participants.

Inclusion criteria were a history of penetrating or lamellar keratoplasty, suboptimal uncorrected or best-corrected visual acuity with spectacles or corneal rigid gas-permeable lenses, ability to undergo comprehensive ophthalmic examination, and provision of informed consent. Exclusion criteria included active ocular surface or intraocular disease (e.g., infection, severe keratoconjunctivitis sicca, active uveitis), uncontrolled systemic disease affecting the eye (e.g., Sjogren's syndrome or severe autoimmune disease), severe corneal scarring or irregularity precluding scleral lens fitting, contact lens intolerance, and inability or unwillingness to comply with follow-up.

All participants underwent comprehensive ophthalmic and optometric evaluation prior to lens fitting. Visual acuity was measured using a Snellen chart and recorded in decimal notation [10]. Contrast sensitivity was assessed using an original paper version of the Melbourne Edge Test [11] (MET; National Vision Research Institute, Melbourne, Australia) at a testing distance of 40 cm under ambient illumination, with results recorded in decibels (dB) based on the last correctly identified edge. Refractive error was measured by an automated refractometer/keratometer (KR-8800, Topcon Corp., Tokyo, Japan), followed by over-refraction and refinement using streak retinoscopy (Beta 200, Heine Optotechnik, Herrsching, Germany) and subjective refraction to determine final lens power. Anterior segment examination was performed using slit-lamp biomicroscopy (Topcon Corporation and Neitz Instruments Co., LTD, Tokyo, Japan).

Scleral lens fitting was performed using a diagnostic trial lens set. Anterior segment optical coherence tomography (AS-OCT; Optovue RTVue XR Avanti, Optovue Inc., Fremont, CA, USA) was used to evaluate lens fit, including central corneal clearance (<250  $\mu\text{m}$ ), mid-peripheral clearance (100–200  $\mu\text{m}$ ), limbal clearance (80–120  $\mu\text{m}$ ), and landing zone alignment on the sclera. Slit-lamp biomicroscopy was used to assess lens centration, toric axis alignment (when applicable), vascular blanching or congestion, and ocular surface response. Lens stability and movement were evaluated using push-up testing. Visual and refractive parameters were recorded before fitting and repeated after optimal lens fitting. Final lenses were dispensed and patients were reassessed after 1–2 weeks.

In the absence of a standardized questionnaire, patient-reported satisfaction was evaluated using a single-item outcome measure. Participants rated their overall satisfaction with scleral lens wear on a 0–10 scale at 1–2 weeks after dispensing, with predefined categories of 8–10 (complete satisfaction), 5–7 (satisfaction), 2–4 (dissatisfaction), and 0–1 (complete dissatisfaction).

Statistical analysis was performed using IBM SPSS Statistics for Windows (version 22.0; IBM Corp., Armonk, NY, USA). The normality of continuous variables was assessed using the Shapiro–Wilk test. Continuous data are presented as mean (standard deviation [SD]), and categorical variables as number (percentage). Pre- and post-fitting comparisons were performed using paired *t*-tests. A *P*-value < 0.05 was considered statistically significant.

## RESULTS

A total of 18 eyes from 12 post-keratoplasty patients, 7 men (58%) and 5 women (42%), were included. The mean (SD, range) age was 45.6 (3.9, 22–67) years.

Following scleral lens fitting, the distribution of decimal visual acuity showed a pronounced shift toward higher values, with elimination of low-acuity categories and 11 eyes (61%) achieving 1.00 decimal acuity (Table 1). Mean (SD) visual acuity increased from 0.15 (0.12) decimal before lens fitting to 0.77 (0.33) decimal after scleral lens wear (mean difference +0.62 decimal;  $P < 0.001$ ), indicating a substantial improvement in visual performance.

A similar trend was observed for contrast sensitivity, with post-fitting values clustering at higher levels, particularly 22 dB in 11 eyes (61%) (Table 2). Mean (SD) contrast sensitivity increased from 14.55 (3.82) dB before lens wear to 20.33 (2.35) dB after scleral lens fitting (mean difference +5.78 dB;  $P < 0.001$ ). Overall, a marked redistribution toward higher visual acuity and contrast sensitivity categories was observed following scleral lens fitting (Tables 1 and 2). All patients reported satisfaction with scleral lens wear, including complete satisfaction in nine patients (75%) and satisfaction in three patients (25%).

Quantitative comparison of refractive error before and after scleral lens fitting was not performed due to non-random missing data. In several cases, reliable measurement of refractive error, particularly cylindrical components, was not feasible before fitting because of corneal opacity, severe irregular astigmatism, or unreliable subjective responses. Furthermore, the optical mechanism of scleral lenses, which creates a tear reservoir, effectively neutralizes corneal irregularity, resulting in minimal residual refractive error on over-refraction, typically approaching emmetropia.

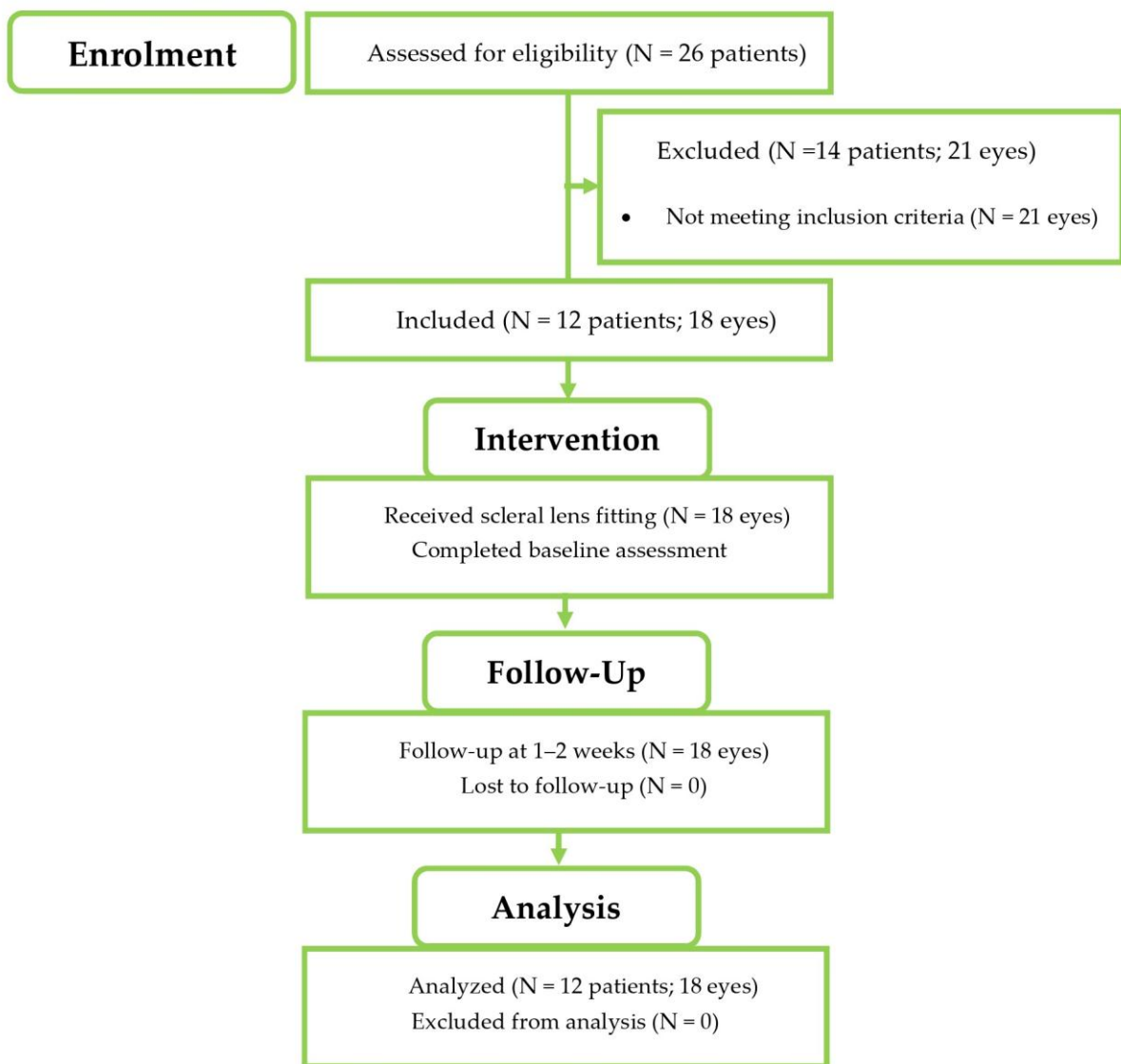


Figure 1. Study flow diagram illustrating participant enrollment, inclusion, intervention, follow-up, and analysis in this prospective single-arm before–after study of scleral lens fitting in post-keratoplasty patients.

**Table 1. Distribution of visual acuity before and after scleral lens fitting**

Visual Acuity (Decimal)	Before scleral lens fitting, n (%)	After scleral lens fitting, n (%)
0.01	1 (6)	0 (0)
0.02	2 (11)	0 (0)
0.03	1 (6)	0 (0)
0.04	1 (6)	0 (0)
0.10	6 (33)	0 (0)
0.20	4 (22)	3 (17)
0.30	1 (6)	1 (6)
0.40	2 (11)	0 (0)
0.50	0 (0)	1 (6)
0.60	0 (0)	1 (6)
0.80	0 (0)	1 (6)
1.00	0 (0)	11 (61)

Abbreviations: n, number of eyes; %, percentage.

**Table 2. Distribution of contrast sensitivity before and after scleral lens fitting**

Contrast Sensitivity (dB)	Before scleral lens fitting, n (%)	After scleral lens fitting, n (%)
5.00	2 (11)	0 (0)
12.00	1 (6)	0 (0)
13.00	2 (11)	0 (0)
16.00	9 (50)	2 (11)
17.00	2 (11)	2 (11)
18.00	2 (11)	0 (0)
19.00	0 (0)	2 (11)
20.00	0 (0)	1 (6)
22.00	0 (0)	11 (61)

Abbreviations: dB, decibels; n, number of eyes; %, percentage.

## DISCUSSION

The present study evidenced that scleral lens fitting in post-keratoplasty patients resulted in significant improvements in visual acuity and contrast sensitivity, accompanied by high levels of patient satisfaction and no observed adverse events. These findings highlight the effectiveness of scleral lenses as a non-surgical approach for visual rehabilitation in eyes with postoperative corneal irregularity.

Our participants who had undergone corneal transplantation were candidates for scleral lens fitting due to impaired visual performance. Corneal irregularities are a major cause of visual impairment and can significantly affect patient satisfaction [12–14]. Conventional optical correction with spectacles often fails to provide adequate visual rehabilitation in these cases. Contact lens fitting has long played an important role in visual rehabilitation after keratoplasty [15, 16]. However, patients may experience intolerance to conventional lens modalities [2, 17]; in such cases, scleral lenses may provide a particularly effective alternative. While mild myopia and astigmatism following corneal transplantation can be corrected with spectacles, visual outcomes are often suboptimal, and rigid gas-permeable or hybrid contact lenses are frequently required. Most clinicians favor large-diameter, multicurve rigid gas-permeable and scleral lenses over hydrogel, hybrid, or piggyback designs [2].

Post-keratoplasty ametropia often limits the attainment of optimal visual acuity, and conventional optical correction methods frequently fail to provide satisfactory visual outcomes. In this context, scleral contact lenses represent an optimal approach for correcting postoperative refractive irregularities, facilitating visual rehabilitation and potentially reducing the need for additional keratorefractive interventions [3, 14, 18]. In a study of 34 patients (48 eyes) with a history of penetrating keratoplasty, scleral lens correction resulted in an average improvement of two Snellen lines in best-corrected visual acuity compared with prior spectacle or contact lens correction. In that study, 44 eyes (91.7%) achieved functional vision ( $\geq 20/40$ ) with scleral lenses, and the authors concluded that scleral lenses are both effective and safe in post-keratoplasty patients [19]. Consistent with these findings, the present study showed comparable outcomes, with most eyes ( $n = 11/18$ , 61%) achieving visual acuity up to 1.0 decimal following scleral lens fitting.

Alipour et al. [20] evaluated the feasibility, efficacy, and safety of mini-scleral contact lenses for visual rehabilitation after corneal transplantation [20]: 56 eyes of 45 patients with unsatisfactory postoperative vision were fitted with mini-scleral lenses (15.8 mm diameter), resulting in a marked improvement in visual acuity from 20/100 to 20/30 [20]. The authors concluded that mini-scleral lenses represent a useful option for visual management in post-keratoplasty patients [20]. Favorable refractive outcomes were consistently observed in a review evaluating 32 original studies and seven case reports, with most authors favoring scleral lenses over hydrogel, hybrid, or piggyback modalities for visual rehabilitation [2]. Significant improvements in visual acuity have also been reported across multiple studies following scleral lens fitting [8, 19, 21–24]. Consistent with this body of evidence, the present study demonstrated a statistically significant improvement in visual acuity following scleral lens fitting, with mean values increasing from 0.15 to 0.77 decimal, thus representing a substantial gain.

Contrast sensitivity is a key component of visual quality and functional vision [25]. Previous studies have consistently demonstrated that scleral lens fitting is associated with improved contrast sensitivity [26–29]. In one study involving 58 eyes with keratoconus, pellucid marginal degeneration, or post-keratoplasty astigmatism, scleral lenses were prescribed to evaluate visual performance and quality of life [26]. Pre-fitting assessments included refraction as well as measurement of uncorrected and spectacle-corrected distance visual acuity and contrast sensitivity. The results evidenced a significant improvement in contrast sensitivity, with values under scleral lens wear significantly higher than under both uncorrected and spectacle-corrected conditions [26]. Consistent with this evidence, the present study also demonstrated a statistically significant increase in contrast sensitivity following scleral lens fitting, with mean values improving from 14.55 to 20.33 dB, indicating a substantial enhancement in visual quality.

Patient-reported outcomes further support the functional benefits of scleral lens wear. In one study, the National Eye Institute Visual Function Questionnaire overall score was significantly higher in patients treated with scleral contact lenses compared with their uncorrected condition [26]. High levels of patient satisfaction have been reported with modern scleral lens designs in the management of various corneal abnormalities [24], and scleral lens wearers with keratoconus report greater satisfaction with vision and comfort compared with gas-permeable lens users [30]. Consistent with current evidence [23, 24, 26, 30], patient satisfaction was uniformly high in the present study, with all participants reporting satisfaction with scleral lens wear 1–2 weeks after dispensing.

No adverse events were observed in the present study; all patients received detailed instructions and appropriate education, with emphasis on strict adherence to prescribed lens care regimens. Scleral contact lenses represent a valuable tool for visual rehabilitation following corneal transplantation and may delay or prevent further surgical intervention; however, their successful use requires careful patient selection, precise fitting techniques, and close follow-up to monitor potential complications [8, 9, 31]. Although scleral lenses can play an important role in improving or maintaining ocular surface integrity in post-keratoplasty patients, their use should be approached with caution [7, 32]: concerns have been raised regarding reduced oxygen transmission and potential long-term complications [33]. Scleral lenses are particularly beneficial for eyes with irregular corneas, such as those with keratoconus or post-surgical corneal changes [34]. By vaulting the corneal surface and maintaining a fluid reservoir, they contribute to ocular surface protection, while their high-oxygen-permeable (high-Dk) materials support adequate oxygen transmission. Nevertheless, appropriate patient education and strict adherence to prescribed lens care regimens remain essential for safe and successful scleral lens use [7, 32, 33].

Despite the advantages of scleral lenses, careful assessment of corneal thickness and endothelial cell density (ECD) is recommended before lens fitting and throughout follow-up in post-keratoplasty patients, as ECD is shown to decline at a higher rate following penetrating keratoplasty, independently of preoperative diagnosis. In eyes with ECD values of 400–700 cells/mm<sup>2</sup>, scleral lens wear may be contraindicated unless the potential benefits outweigh the associated risks [35–37]. Patients fitted with scleral lenses after keratoplasty require close monitoring at regular intervals (every 3–4 months) for signs of corneal hypoxia, neovascularization, or graft rejection. In addition to slit-lamp examination, baseline and follow-up measurements of corneal pachymetry and ECD are essential [9, 32, 38]. Although the present study reports short-term visual outcomes and patient satisfaction following scleral lens fitting, participants were enrolled in an ongoing long-term follow-up program. Longitudinal monitoring of clinical parameters and safety outcomes continues beyond the scope of this report.

The strengths of this study include its prospective design, comprehensive assessment of both visual acuity and contrast sensitivity, and incorporation of patient-reported outcomes. Limitations should be acknowledged, including the relatively small sample size, short follow-up duration, and lack of a comparative control group. In addition, refractive error data could not be reliably analyzed due to non-random missing measurements. Future studies with larger cohorts, longer follow-up, and direct comparison with other contact lens modalities are warranted to further define the long-term efficacy, safety, and optimal clinical indications of scleral lenses in post-keratoplasty visual rehabilitation.

## CONCLUSIONS

Post-keratoplasty ametropia and corneal irregularity frequently limit visual rehabilitation with conventional optical correction methods, including spectacles and soft or rigid contact lenses. The findings of the present study evidence that scleral lenses provide a highly effective solution for managing postoperative refractive irregularities, resulting in significant improvements in both visual acuity and contrast sensitivity, along with high levels of patient satisfaction. The ability of scleral lenses to vault the corneal surface and create a smooth optical interface likely underlies these functional gains, enabling meaningful enhancement of visual performance in post-keratoplasty eyes. These results support the role of scleral lenses as a valuable non-surgical modality for visual rehabilitation in this patient population. Appropriate patient selection, meticulous fitting, and regular follow-up are essential to ensure safety and optimize outcomes. Further studies with larger sample sizes and longer follow-up are warranted to confirm long-term efficacy and safety.

## ETHICAL DECLARATIONS

**Ethical approval:** The study was registered in the Iranian Registry of Clinical Trials (IRCT20251210068270N1; approval date: December 20, 2025) and approved by the institutional ethics committee (IR.BMSU.BLC.1404.099). All procedures adhered to the tenets of the Declaration of Helsinki, and written informed consent was obtained from all participants.

**Conflict of interests:** None.

**FUNDING****None.****ACKNOWLEDGMENTS**

The authors gratefully acknowledge the academic guidance and consultation provided by Professor Ebrahim Jafarzadehpur and Dr. Mehdi Raei.

**REFERENCES**

1. Aggarwal S, Kumari M, Bhatnagar N. Advancements in keratoplasty: Exploring newer techniques and imaging modalities for enhanced surgical outcomes. *Saudi J Ophthalmol.* 2024 Mar 1;39(4):337-348. doi: 10.4103/sjopt.sjopt\_234\_23. PMID: 41367843; PMCID: PMC12685274.
2. Asif MI, Kalra N, Tripathi M, Yadav MA, Anjum S, Sinha R. Contact lenses for visual rehabilitation in post-keratoplasty eyes: A review. *Indian J Ophthalmol.* 2025 Jun 1;73(Suppl 3):S369-S383. doi: 10.4103/IJO.IJO\_2394\_24. Epub 2025 Apr 17. PMID: 40243067; PMCID: PMC12178419.
3. Khosravi Mirzaei S, Feizi S, Hatami F, Hatami F, Moshtaghion SM. Contact lenses for visual rehabilitation in post-keratoplasty eyes: A systematic review. *Cont Lens Anterior Eye.* 2025 Jun;48(3):102374. doi: 10.1016/j.clae.2025.102374. Epub 2025 Jan 28. PMID: 39875311.
4. Wietham BE, Driebe WT Jr. Fitting contact lenses for visual rehabilitation after penetrating keratoplasty. *Eye Contact Lens.* 2004 Jan;30(1):31-3. doi: 10.1097/01.ICL.0000101488.84455.E6. PMID: 14722466.
5. Zhang J, Lin X, Li Z, Zhong X, Shi W, Du X, Gao H. Visual rehabilitation using rigid gas permeable contact lenses after femtosecond laser-assisted minimally invasive lamellar keratoplasty in patients with keratoconus. *Sci Rep.* 2024 Oct 23;14(1):25106. doi: 10.1038/s41598-024-76819-7. PMID: 39443623; PMCID: PMC11500085.
6. Moramarco A, Gardini L, Iannetta D, Versura P, Fontana L. Post Penetrating Keratoplasty Ectasia: Incidence, Risk Factors, Clinical Features, and Treatment Options. *J Clin Med.* 2022 May 10;11(10):2678. doi: 10.3390/jcm11102678. PMID: 35628805; PMCID: PMC9147912.
7. Rodriguez-Garcia A, Jimenez-Perez JC, Ruiz-Lozano RE, Bustamante-Arias A, Barcelo-Canton RH. Scleral lenses and PROSE: indications, complications, and future challenges. *Med Hypothesis Discov Innov Ophthalmol.* 2025 Sep 27;14(3):73-106. doi: 10.51329/mehdiophthal1525. PMID: 41111638; PMCID: PMC12528766.
8. Severinsky B, Behrman S, Frucht-Pery J, Solomon A. Scleral contact lenses for visual rehabilitation after penetrating keratoplasty: long term outcomes. *Cont Lens Anterior Eye.* 2014 Jun;37(3):196-202. doi: 10.1016/j.clae.2013.11.001. Epub 2013 Dec 2. PMID: 24300196.
9. Ruiz-Lozano RE, Gomez-Elizondo DE, Colorado-Zavala MF, Loya-Garcia D, Rodriguez-Garcia A. Update on indications, complications, and outcomes of scleral contact lenses. *Med Hypothesis Discov Innov Ophthalmol.* 2022 Feb 24;10(4):165-178. doi: 10.51329/mehdiophthal1435. PMID: 37641653; PMCID: PMC10460232.
10. Holladay JT. Visual acuity measurements. *J Cataract Refract Surg.* 2004 Feb;30(2):287-90. doi: 10.1016/j.jcrs.2004.01.014. PMID: 15030802.
11. Haymes SA, Chen J. Reliability and validity of the Melbourne Edge Test and High/Low Contrast Visual Acuity chart. *Optom Vis Sci.* 2004 May;81(5):308-16. doi: 10.1097/01.opx.0000134904.21274.db. PMID: 15181355.
12. Bhayani R, Walkden A. Managing Post Keratoplasty Astigmatism. *Clin Ophthalmol.* 2024 Jun 13;18:1727-1734. doi: 10.2147/OPTH.S393975. PMID: 38887510; PMCID: PMC11182034.
13. Bandeira E Silva F, Hazarbassanov RM, Martines E, Güell JL, Hofling-Lima AL. Visual Outcomes and Aberrometric Changes With Topography-Guided Photorefractive Keratectomy Treatment of Irregular Astigmatism After Penetrating Keratoplasty. *Cornea.* 2018 Mar;37(3):283-289. doi: 10.1097/ICO.0000000000001474. PMID: 29215394.
14. Bineshfar N, Tahvildari A, Feizi S. Management of post-keratoplasty ametropia. *Ther Adv Ophthalmol.* 2023 Oct 16;15:25158414231204717. doi: 10.1177/25158414231204717. PMID: 37854948; PMCID: PMC10580728.
15. Szczotka LB, Lindsay RG. Contact lens fitting following corneal graft surgery. *Clin Exp Optom.* 2003 Jul;86(4):244-9. doi: 10.1111/j.1444-0938.2003.tb03113.x. PMID: 12859244.
16. Pullum KW, Whiting MA, Buckley RJ. Scleral contact lenses: the expanding role. *Cornea.* 2005 Apr;24(3):269-77. doi: 10.1097/01.ico.0000148311.94180.6b. PMID: 15778597.
17. Nau AC. A comparison of synergeyes versus traditional rigid gas permeable lens designs for patients with irregular corneas. *Eye Contact Lens.* 2008 Jul;34(4):198-200. doi: 10.1097/ICL.0b013e31815c859b. PMID: 18787425.
18. Özçelik O, Özbek Z, Yıldırım CA, Durak İ. Spectrum of Scleral Lens Fit and Patient Compliance: A Single Center Retrospective Study. *Turk J Ophthalmol.* 2025 Aug 21;55(4):186-192. doi: 10.4274/tjo.galenos.2025.23238. PMID: 40838477; PMCID: PMC12372548.
19. Barnett M, Lien V, Li JY, Durbin-Johnson B, Mannis MJ. Use of Scleral Lenses and Miniscleral Lenses After Penetrating Keratoplasty. *Eye Contact Lens.* 2016 May;42(3):185-9. doi: 10.1097/ICL.000000000000163. PMID: 26214530.

20. Alipour F, Behrouz MJ, Samet B. Mini-scleral lenses in the visual rehabilitation of patients after penetrating keratoplasty and deep lamellar anterior keratoplasty. *Cont Lens Anterior Eye*. 2015 Feb;38(1):54-8. doi: 10.1016/j.clae.2014.10.001. Epub 2014 Oct 25. PMID: 25457628.
21. Kaushik J, Goyal S, Singh A, Rana V, Parihar JKS, Sati A, Jhanwar M. Efficacy of mini-scleral lenses in visual rehabilitation for corneal disorders: a prospective study. *BMC Ophthalmol*. 2025 May 31;25(1):329. doi: 10.1186/s12886-025-04155-z. PMID: 40450226; PMCID: PMC12126882.
22. Penbe A, Kanar HS, Simsek S. Efficiency and Safety of Scleral Lenses in Rehabilitation of Refractive Errors and High Order Aberrations After Penetrating Keratoplasty. *Eye Contact Lens*. 2021 May 1;47(5):301-307. doi: 10.1097/ICL.0000000000000755. PMID: 33136690.
23. Pecego M, Barnett M, Mannis MJ, Durbin-Johnson B. Jupiter Scleral Lenses: the UC Davis Eye Center experience. *Eye Contact Lens*. 2012 May;38(3):179-82. doi: 10.1097/ICL.0b013e31824daa5e. PMID: 22543730.
24. Visser ES, Visser R, van Lier HJ, Otten HM. Modern scleral lenses part II: patient satisfaction. *Eye Contact Lens*. 2007 Jan;33(1):21-5. doi: 10.1097/01.icl.0000228964.74647.25. PMID: 17224675.
25. Ginsburg AP. Contrast sensitivity and functional vision. *Int Ophthalmol Clin*. 2003 Spring;43(2):5-15. doi: 10.1097/00004397-200343020-00004. PMID: 12711899.
26. Ozek D, Kemer OE, Altiaylik P. Visual performance of scleral lenses and their impact on quality of life in patients with irregular corneas. *Arq Bras Oftalmol*. 2018 Nov./Dec.;81(6):475-480. doi: 10.5935/0004-2749.20180089. Epub 2018 Sep 13. PMID: 30231157.
27. Sabesan R, Johns L, Tomashevskaya O, Jacobs DS, Rosenthal P, Yoon G. Wavefront-guided scleral lens prosthetic device for keratoconus. *Optom Vis Sci*. 2013 Apr;90(4):314-23. doi: 10.1097/OPX.0b013e318288d19c. PMID: 23478630; PMCID: PMC4871146.
28. Hastings GD, Applegate RA, Nguyen LC, Kauffman MJ, Hemmati RT, Marsack JD. Comparison of Wavefront-guided and Best Conventional Scleral Lenses after Habituation in Eyes with Corneal Ectasia. *Optom Vis Sci*. 2019 Apr;96(4):238-247. doi: 10.1097/OPX.0000000000001365. PMID: 30943184; PMCID: PMC6450417.
29. Dutta R, Iyer G, Srinivasan B, Iqbal A. Aberration change after scleral lens wear in eyes with pellucid marginal degenerations. *Indian J Ophthalmol*. 2024 Jul 1;72(7):1037-1042. doi: 10.4103/IJO.IJO\_1820\_23. Epub 2024 Feb 5. PMID: 38324626; PMCID: PMC11329822.
30. Shorter E, Schornack M, Harthan J, Nau A, Fogt J, Cao D, Nau C. Keratoconus Patient Satisfaction and Care Burden with Corneal Gas-permeable and Scleral Lenses. *Optom Vis Sci*. 2020 Sep;97(9):790-796. doi: 10.1097/OPX.0000000000001565. PMID: 32941334.
31. van der Worp E, Bornman D, Ferreira DL, Faria-Ribeiro M, Garcia-Porta N, González-Meijome JM. Modern scleral contact lenses: A review. *Cont Lens Anterior Eye*. 2014 Aug;37(4):240-50. doi: 10.1016/j.clae.2014.02.002. Epub 2014 Mar 12. PMID: 24631015.
32. Harthan JS, Shorter E. Therapeutic uses of scleral contact lenses for ocular surface disease: patient selection and special considerations. *Clin Optom (Auckl)*. 2018 Jul 11;10:65-74. doi: 10.2147/OPTO.S144357. PMID: 30319297; PMCID: PMC6181806.
33. Compañ V, Oliveira C, Aguilera-Arzo M, Mollá S, Peixoto-de-Matos SC, González-Meijome JM. Oxygen diffusion and edema with modern scleral rigid gas permeable contact lenses. *Invest Ophthalmol Vis Sci*. 2014 Sep 4;55(10):6421-9. doi: 10.1167/iovs.14-14038. PMID: 25190661.
34. Barone V, Petrini D, Nunziata S, Surico PL, Scarani C, Offi F, Villani V, Coassin M, Di Zazzo A. Impact of Scleral Lenses on Visual Acuity and Ocular Aberrations in Corneal Ectasia: A Comprehensive Review. *J Pers Med*. 2024 Oct 11;14(10):1051. doi: 10.3390/jpm14101051. PMID: 39452558; PMCID: PMC11509004.
35. Kettesy B, Nemeth G, Kemeny-Beke A, Berta A, Modis L. Assessment of endothelial cell density and corneal thickness in corneal grafts an average of 5 years after penetrating keratoplasty. *Wien Klin Wochenschr*. 2014 May;126(9-10):286-90. doi: 10.1007/s00508-014-0524-6. Epub 2014 Apr 4. PMID: 24700243.
36. Viguera-Guillén JP, van Rooij J, Engel A, Lemij HG, van Vliet LJ, Vermeer KA. Deep Learning for Assessing the Corneal Endothelium from Specular Microscopy Images up to 1 Year after Ultrathin-DSEAK Surgery. *Transl Vis Sci Technol*. 2020 Aug 21;9(2):49. doi: 10.1167/tvst.9.2.49. PMID: 32884856; PMCID: PMC7445361.
37. Bertolin M, Ruzza A, Barbaro V, Zanetti E, Ponzin D, Ferrari S. Factors Affecting the Density of Corneal Endothelial Cells Cultured from Donor Corneas. *Int J Mol Sci*. 2024 Nov 5;25(22):11884. doi: 10.3390/ijms252211884. PMID: 39595954; PMCID: PMC11593917.
38. Gurnani B, Czyn CN, Mahabadi N, Havens SJ. Corneal Graft Rejection. 2023 Jun 11. In: StatPearls [Internet]. Treasure Island (FL): StatPearls Publishing; 2026 Jan-. PMID: 30085585.