



Diagnostic and therapeutic approaches to optic disc pit maculopathy in children

Dimitrios Kalogeropoulos^{1,2}, Ioannis Asproudis¹, Soon Wai Ch'ng², Arijit Mitra², Ash Sharma², Konstantinos Katsikatsos¹, Christopher Asproudis¹ and Chris Kalogeropoulos¹

¹ Department of Ophthalmology, Faculty of Medicine, School of Health Sciences, University of Ioannina, Greece

² Birmingham Midlands Eye Centre, Sandwell and West Birmingham Hospitals NHS Trust, Dudley Road, Birmingham, UK

ABSTRACT

Background: Optic disc pit (ODP) is a rare congenital defect of the optic disc that can lead to maculopathy and gradual visual impairment. This review summarizes our current knowledge on the diagnostic and therapeutic approaches to ODP maculopathy (ODP-M) in children.

Methods: A thorough literature search was performed using the PubMed/MEDLINE database from 1960 to 2020. An additional search was conducted using Google Scholar for completeness.

Results: ODP-M is characterized by the accumulation of subretinal and/or intraretinal fluid. The exact pathogenetic mechanisms are not fully understood, and the origin of the fluid remains unknown. Although ODP-M is more likely to occur during the third or fourth decade of life, cases of children with serous retinal detachment have been recorded. Early diagnosis of ODP-M and prompt, appropriate management are crucial, particularly in patients of amblyogenic age. In adults, ODP-M may resolve spontaneously, but most cases require surgical intervention to prevent permanent loss of vision. However, the fact that ODP-M may spontaneously resolve in children cannot be ignored. Various surgical methods have been described, including pars plana vitrectomy (PPV) combined with various techniques, including laser photocoagulation, intravitreal gas injection, and macular buckling.

Conclusions: PPV remains the mainstay surgical approach for ODP-M. However, ODP-M may differ between children and adults. Children constitute a unique population of patients that require a different and probably more tailor-made approach. Detailed clinical examination, combined with a thorough analysis of retinal imaging, may improve our understanding of the background and pathophysiology of the disease and eventually provide us with new insights into the management of ODP-M in the pediatric population.

KEY WORDS

congenital anomalies, optic disc pit, optic disc pit maculopathy, retinal imaging, surgical treatment, pars plana vitrectomy

INTRODUCTION


An optic disc pit (ODP) is a cavitory abnormality of the optic nerve head similar to optic disc coloboma, morning glory, and extrapapillary cavitation [1]. It is typically a congenital disorder, but it is also associated with other ophthalmic disorders, such as myopia or glaucoma [2-4]. It is a rare entity, with an estimated prevalence of 2 in approximately 10,000 of the general population, with no gender predilection [5, 6]. Although mostly unilateral,

Correspondence: Dimitrios Kalogeropoulos, Faculty of Medicine, School of Health Sciences, Department of Ophthalmology, University of Ioannina. Stavros Niarchos Ave., 45500, Ioannina, Greece. E-mail: dkalog1990@gmail.com. ORCID iD: <https://orcid.org/0000-0001-6404-5409>

How to cite this article: Kalogeropoulos D, Asproudis I, Ch'ng SW, Mitra A, Sharma A, Katsikatsos K, Asproudis C, Kalogeropoulos C. Diagnostic and therapeutic approaches to optic disc pit maculopathy in children. Med Hypothesis Discov Innov Optom. 2021 Spring; 2(1): 24-35. DOI: <https://doi.org/10.51329/mehdiptometry122>

Received: 17 April 2021 Accepted: 01 June 2021



Copyright © Author(s). This is an open-access article distributed under the terms of the Creative Commons Attribution-NonCommercial 4.0 International License (<http://creativecommons.org/licenses/by-nc/4.0/>) which permits copy and redistribute the material just in noncommercial usages, provided the original work is properly cited. 

bilateral ODP occurs in up to 15% of cases [1, 7]. Most cases are sporadic, but in families with more than one affected member, autosomal inheritance has also been reported [8-10].

Formation of ODP has not been linked to any specific genetic profile to date. In most patients, the condition is asymptomatic and may be detected incidentally during routine ophthalmological assessments. However, it may sometimes present with irreversible visual field defects, such as enlarged blind spots or paracentral arcuate scotomas [11]. Moreover, ODP has been linked to macular changes, such as serous detachment, cystic degeneration, and degenerative pigmentary changes that can lead to a decline in central visual acuity (VA) [11-14]. In 25–75% of patients with ODP, macular detachment and/or retinoschisis occur at some stage of their lifetime, which leads to a condition termed ODP-maculopathy (ODP-M) [1]. Although ODP-M is more likely to occur during the third or fourth decade of life [15], cases of children with serous retinal detachment have been reported [7, 16-20]. It has been estimated that spontaneous resolution with good visual outcomes occurs in approximately 25% of cases [21]. However, coexisting macular detachment can be accompanied by lamellar or full-thickness macular holes, cystoid changes, and retinal pigment epithelium atrophy, causing an irreversible visual loss with a Snellen VA of 20/200 or worse, particularly in longstanding cases [22, 23].

There are several case reports and case series of ODP-M in children in the available literature, but only a few population-based studies have been reported [24]. However, children constitute a unique population that requires a different management style than adults. This review aimed to summarize current knowledge on the diagnostic and therapeutic approaches to ODP-M in children.

METHODS

A thorough literature search was performed in the PubMed/MEDLINE database. An additional search was conducted using Google Scholar. The following keywords were used in the searches: congenital anomalies, optic disc pit, optic disc pit maculopathy, retinal imaging, surgical treatment, and pars plana vitrectomy. We reviewed papers published between 1960 and 2020, focusing on studies published after 2000, and using mostly those published after 2010. Only references in English were included. Additionally, the patients' archives from our unit were the source of figures used in this manuscript to support the importance of clinical, imaging, and laboratory findings in the diagnostic workup.

RESULTS

ODP-M is related to the accumulation of subretinal and/or intraretinal fluid. The exact pathogenetic mechanisms are not fully understood, and the origin of the fluid remains unknown [1]. Although ODP-M is more likely to occur during the third or fourth decade of life, cases of children with serous retinal detachment have been recorded [7, 15-20]. The clinical signs and symptoms of ODP-M are summarized in Table 1. In adults, ODP-M may resolve spontaneously, but most cases require surgical intervention to prevent permanent loss of vision [25]. Various surgical methods have been described, including pars plana vitrectomy (PPV) (combined with various techniques), laser photocoagulation, intravitreal gas injection, and macular buckling [1, 26-30]. The characteristics and main findings of the studies involving pediatric patients with ODP-M are summarized in Table 2.

DISCUSSION

Most children with ODP are asymptomatic, whereas those that develop ODP-M report a recent gradual visual deterioration, which is consistent with the presence of serous macular elevations [31]. The Snellen VA can range from 20/25 to counting fingers, depending on the severity and duration of maculopathy. Disturbances in color vision and visual fields may also be present [31, 32]. On fundal examination (Figure 1), ODP appears as a hypopigmented, round, or oval excavation near the optic disc margin, most commonly in the inferior temporal quadrant of the disc. The pit is centrally located in approximately 10–20% of cases [33]. ODP may involve from one-eighth to one-quarter of the optic disc, and fine interlacing glial tissue fills the cavity to some extent [14, 15, 33]. Central retinal vessels can be normally observed, but in some cases, a vessel can extend into the depth of the pit, disappearing and appearing again on the other side of the ODP. Cilioretinal and optociliary vessels can also pass through the pit [14]. The amount of intraretinal fluid and therefore the degree of neurosensory retinal detachment and macular elevation are not related to the pit size and may vary significantly among individuals [11, 33]. These features are usually expected between the supratemporal and inferotemporal arcades, but can potentially develop beyond this anatomical area. Macular and pigmentary changes may arise as complications in persistent ODP-M cases [34].

Table 1. Clinical signs and symptoms of ODP and ODP-M [11, 14, 15, 31-34]

Symptoms
Most individuals with ODP are asymptomatic.
Those that develop ODP-M present with a report of a recent gradual visual deterioration.
VA can range from Snellen 20/25 to CF depending on the severity and duration of maculopathy.
Disorders in color vision and visual fields may also appear.
Fundoscopic signs
ODP appears as a hypopigmented, round or oval excavation near the optic disc margin.
Most commonly, ODP is located in the inferior temporal quadrant of the disc.
A central location of the pit may be observed in approximately 10-20% of cases.
ODP may involve one-eighth to one-quarter of the optic disc, and delicate interlacing glial tissue fills the cavity up to some extend.
Central retinal vessels are normally observed.
In some cases, a vessel can go extend into the depth of the pit, disappear, and reappear again on the other side of the ODP.
Cilioretinal and optociliary vessels can also course to and from the pit.
The amount of intraretinal fluid, and therefore the degree of neurosensory retinal detachment and serous macular elevation, are not related to the pit size and may vary significantly.
Macular and pigmentary alterations may arise as complications in persistent ODP-M cases.

Abbreviations: ODP, optic disc pit; ODP-M, optic disc pit maculopathy; VA, visual acuity; CF, counting fingers.

Table 2. Characteristics and main findings of studies involving pediatric patients with optic disc pit maculopathy (ODP-M)

First author/Year	Type of study	Cases	Laterality	Clinical findings	Imaging findings	Intervention	Final outcome
Kalogeropoulos et al., 2020 [16]	Case series	1	Unilateral	ODP in the temporal aspect of the ONH with contiguous IRF.	IRF	Observation	Spontaneous resolution
Benatti et al., 2021 [63]	Case report	1	Unilateral	ODP	ODP-M	Observation	Spontaneous resolution
Kovacova et al., 2018 [67]	Retrospective study	2	Unilateral	ODP at the temporal aspect of the ONH.	Retinoschisis SRF in one eye.	PPV with C3F8.	BCVA improvement and resolution of SRF.
Akça Bayar et al., 2017 [19]	Case report	1	Unilateral	ODP at the temporal aspect of the ONH.	Retinoschisis and fluid under the ILM.	Observation	BCVA improvement and spontaneous resolution of fluid.
Metee et al., 2017 [68]	Case series	1	Unilateral	ODP	Serous macular detachment and SRF.	Vitrectomy with ILM peeling and SF6.	BCVA improvement and complete macular reattachment.
Ozdek et al., 2017 [51]	Case series	1	Unilateral	ODP	Serous macular detachment and SRF.	PPV with ILM peeling and SF6. Secondary, autologous fibrin used to seal optic pit and aspiration of SRF.	BCVA improvement and macular reattachment.
Maertz et al., 2017 [58]	Retrospective observational study	2	Bilateral	Left eyes: temporal ODP, BCVA compromised. Right eyes: central/temporal pit-like depression of the papilla.	Left eyes: macular detachment and retinoschisis and vitreoretinal traction in optic disc.	Observation, history of previous PPV with ILM peeling and endolaser coagulation in 1 eye with ODP.	BCVA improvement in the eyes with ODP, stable in the eyes with a pit-like depression.
Rossi et al., 2017 [8]	Case report	1	Bilateral	ODP at the temporal aspect of the ONH.	Serous macular detachment .	Observation	N/A
Yokoi et al., 2016 [59]	Retrospective review	4	3 unilateral 1 bilateral	Three of four patients have ODP at the temporal aspect of the ONH. One of four patients presents a colobomatous disc with ODPs temporally and inferiorly.	Three of four patients present schisis and RD.	PPV in three of four patients. Observation in one patient with colobomatous optic disc.	Postoperative improvement of BCVA. Post-op attachment of the retina in two of three patients and SRF recession in the other patient. No VA data for the patient with colobomatous disc.

Rayat et al., 2015 [60]	Retrospective review	7	Unilateral	ODP at the temporal aspect of the ONH.	SRF in the macula	PPV (7/7); ILM peeling (1/7); temporal optic disk endolaser (2/7); C3F8 (2/7); and SF6 (5/7).	BCVA improvement (6/7), BCVA slightly worsened in one patient with PPV, and C3F8 attached fovea (7/7).
Lei et al., 2015 [61]	Case series	2	Unilateral	ODP at the temporal aspect of the ONH.	Inner retinal schisis and outer layer detachment at the macula.	PPV with C3F8. Posterior pole laser photocoagulation.	BCVA improvement, fluid resolution, and retinal reattachment.
Akiyama et al., 2014 [69]	Case series	2	Unilateral	ODP at the temporal aspect of the ONH.	Serous macular detachment.	SF6 gas injections	BCVA improvement and macular reattachment.
Sanghi et al., 2014 [70]	Case series	4	Unilateral	ODP	Retinal schisis and outer layer detachment (3/4). Only outer layer detachment (1/4).	PPV, C3F8, and laser photocoagulation at the temporal edge of ODP.	BCVA improvement and resolution of retinal schisis, and outer layer detachment (3/4). BCVA stable and retinal schisis. Outer layer detachment persistent (1/4).
Marticorena et al., 2013 [71]	Case report	1	Unilateral	ODP at the temporal aspect of the ONH.	Serous macular detachment. Retinal schisis from the disc to the macular area.	PPV, SF6, and diode laser photocoagulation. Secondary ILM peeling and diode endolaser.	BCVA improvement after second operation with resolution of SRF and IRF.
Ozkaya et al., 2013 [64]	Case report	1	Bilateral	ODP in the temporal aspect of the ONH.	Loss of retinal tissue and no presence of SRF. Decreased RNFL thickness temporal to optic nerve.	Observation	No changes in BCVA and RNFL.
Shukla et al., 2012 [56]	Case series	2	Unilateral	ODP in the temporal aspect of the ONH.	Macular schisis with a large central outer retinal defect.	PPV, ILM peeling, and peripapillary endolaser photocoagulation.	Macular holes closed. BCVA improvement. Outer retinal detachment resolution.
Rizzo et al., 2012 [57]	Case series	1	Unilateral	ODP in the temporal aspect of the ONH. Serous RD.	Macular hole, and SRF.	PPV, ILM peeling, and endolaser. photocoagulation temporally to the ONH.	Macular hole closed. BCVA improvement.
Hirakata et al., 2012 [72]	Case series	2	Unilateral	ODP inferotemporal of the ONH.	Outer layer schisis-like and inner layer separation, RD.	PPV with no laser or gas injection.	Complete retinal reattachment. BCVA improvement.
Rii et al., 2013 [25]	Case series	4	Unilateral	ODP-M after trauma.	N/A	PPV with gas tamponade.	N/A
Hiraoka et al., 2010 [62]	Retrospective study	1	Unilateral	ODP inferotemporal to the ONH with serous macular detachment.	Outer and inner layer retinal schisis.	PPV without laser photocoagulation.	BCVA improvement. Resolution of the detachment and schisis.
Georgalas et al., 2010 [17]	Case report	1	Unilateral	ODP at the temporal aspect of the ONH.	IRF and SRF in the macula.	PPV, ILM peeling, air tamponade without laser photocoagulation.	BCVA improvement and resolution of the IRF and SRF, and macula re-attachment.
Imamura et al., 2010 [73]	Case series	4	Unilateral	ODP with SRF.	SRF communicating with pit. Outer nuclear layer, inner nuclear layer fluid.	Observation	N/A
Chiu et al., 2006 [74]	Case report	1	Unilateral	ODP at the temporal aspect of the ONH.	Posterior pole serous RD, outer layer detachment. Schisi like cavity.	PPV, SF6, and laser photocoagulation at the temporal margin of the ODP.	BCVA improvement Absorption of SRF (no resolution).

Spaide et al., 2006 [75]	Case report	1	Unilateral	ODP at the temporal aspect of the ONH.	Serous macular detachment.	PPV and a needle retinal penetration creating an alternative outflow path for SRF.	BCVA improvement. Absorption of SRF (no resolution).
Ishikawa et al., 2005 [76]	Case report	1	Unilateral	ODP at the temporal aspect of the ONH.	Schisis-like separation of the sensory retina. Serous macular detachment.	Laser photocoagulation and vitrectomy.	BCVA improvement and SRF resolution.
Hirakata et al., 2005 [77]	Case report	1	Unilateral	ODP at the temporal aspect of the ONH.	Macular detachment and separation of the inner retinal layers that appeared to connect with the optic disc.	PPV with SF6.	BCVA improvement and complete retinal reattachment.
Bakri et al., 2004 [78]	Case report	1	Unilateral	ODP at the temporal aspect of the ONH.	Serous macular detachment.	PPV, full-thickness retinotomy, photocoagulation spots at the temporal aspect of optic nerve, and on the retinotomy. PPV, endolaser photocoagulation 360° around the optic nerve, and C3F8 gas.	BCVA improvement. Retinal reattachment.
Meyer et al., 2004 [79]	Case report	1	Unilateral	ODP at the infero-temporal aspect of ONH.	Serous macular detachment with outer layer detachment and a schisis-like cavity.	N/A	N/A
Brodsky et al., 2003 [65]	Case report	1	Unilateral	ODP at the temporal aspect of the ONH.	Serous macular detachment.	Observation	BCVA improvement and serous macular detachment resolved spontaneously.
Yuen et al., 2002 [20]	Case report	1	Unilateral	ODP at the temporal aspect of the ONH.	Serous macular detachment.	Observation	BCVA improvement and serous macular detachment resolved spontaneously.
Theodossiadis et al., 1999 [23]	Case series	2	Unilateral	ODP	Case 1. Schisis-like separation of the internal layers of the retina and cyst formation in foveola. Case 2. Schisis-like separation, confluent cysts and outer layer detachment.	Scleral macular buckling.	BCVA improvement. Flattened macula with no presence of fluid in the retina or external to the neurosensory retina.

Abbreviation: ODP, Optic disc pit; ONH, optic nerve head; IRE, Intraretinal fluid; SRF, Subretinal fluid; PPV, Pars plana vitrectomy; C3F8, perfluoropropane gas; ILM, Internal limiting membrane; RD, retinal detachment; BCVA, Best-corrected visual acuity; SF6, sulfur hexafluoride gas; N/A, Not available; VA, Visual acuity; RNFL, Retinal nerve fiber layer.

In children, ODP has been associated with rare diseases that occur as a result of developmental disorders and are also linked with other abnormalities of the optic disc. These clinical entities include basal encephalocele, bilateral renal hypoplasia, Aicardi syndrome, Alagille syndrome (JAG1 mutation), and midline neurological developmental malformation [35-39]. Despite being a well-recognized clinical entity, the precise origin and pathogenesis of the intra- and sub-retinal fluid in ODP-M has not yet been clarified, and there are no obvious triggering factors [1]. It has been hypothesized that ODP-M may be related to posterior vitreous detachment (PVD) [40, 41], but this is questionable, as ODP-M has also been reported in children with no evidence of vitreous liquefaction [25, 40]. Regardless of the fluid origin, a generally accepted series of events occur during

the development of ODP-M [1, 33, 40, 42]. First, fluid derived from the ODP leads to a schisis-like inner retinal separation that causes a mild cecentral scotoma. Then, an outer retinal detachment occurs as a result of subretinal dissection of the fluid [43, 44]. The discovery of several hypothetical pathogenetic mechanisms has led to the development of various concepts for managing this rare condition [1, 34].

Patient assessment and the importance of multimodal imaging

The patient's complaints and clinical features must be considered in order to develop a thorough diagnostic approach. Careful slit-lamp examination and indirect funduscopy are crucial for detecting abnormalities of the optic disc (Table 1). Ophthalmic examination is also largely assisted by available imaging techniques. Previous studies have thoroughly described the role of retinal imaging in the management of ODP and ODP-M [1, 21, 45]. Imaging tools include fundus photography, fundus autofluorescence, optical coherence tomography (OCT), fluorescein, and indocyanine green angiography. Appropriate and timely use of each modality can be extremely helpful not only in making a diagnosis, but also in making therapeutic decisions and in monitoring patients [1, 16, 21, 34, 46]. Jeng-Miller et al. [47] highlighted the contribution of OCT in a detailed in vivo evaluation of the anatomic abnormalities of the optic disc and their associated pathologies, suggesting that it can provide new insights into the management of these conditions in children.

Exploring the potential of OCT features in the prediction of anatomical and functional outcomes is particularly interesting, as various patterns of subretinal and intraretinal fluid have been described in ODP-M. Roy et al. [45] investigated 32 eyes of patients in the age range of 7–54 years with ODP-M and found that 46% of eyes presented with subretinal and multilayered intraretinal fluid, 26% with subretinal and outer retinal layer fluid, 21% with intraretinal fluid only, and only 4% with subretinal fluid alone. The findings of this study suggest that fluid first seeps into the outer retinal layer before involving the other layers. The percentages reported by Roy et al. are in broad agreement with those reported by Steel et al. [48], who found that the pattern of fluid distribution on OCT was predictive of outcome. More specifically, patients with subretinal and multilayer fluid had worse visual and anatomical outcomes than those with subretinal fluid and outer retinal layer fluid only. Additionally, patients with fluid extending beyond the vascular arcades had worse outcomes than those in whom the extent of the fluid was less. One possible explanation for these two negative prognostic factors is that they are both associated with a longer-duration disease [48].

Overall, a thorough study and analysis of different imaging modalities (Figures 2, 3, 4) can contribute to improved understanding of the anatomical associations and therefore the pathogenesis of the disease, thereby facilitating the development of novel treatments and potentially better visual outcomes.

Management of ODP-M

General concept of the therapeutic approach

Conservative treatment of ODP-M was initially proposed, as 25% of cases would resolve spontaneously. However, considering the natural course of ODP-M in combination with the persistence of fluid implies the need for a more aggressive and efficient approach, and several surgical methods have been adopted to prevent visual deterioration and to improve the final outcome [1]. PPV (23- or 25-gauge) remains the mainstay of ODP-M treatment and is usually combined with laser treatment, gas tamponade, and/or internal limiting membrane (ILM) peeling [1]. Intravitreal gas tamponade with or without laser application has also been proposed as an alternative therapeutic option, because pneumatic displacement can cause reattachment of the macula and improve VA [26]. Theodossiadis et al. introduced the macular buckling technique for the treatment of ODP-M [27-30]. The anatomical and functional outcomes of macular buckling rely on the pathophysiology of the disorder, and the hypothesis that the origin of the subretinal fluid may be derived from both vitreous and cerebrospinal fluid. Although the results of this technique are impressive, it is considered a difficult technique, with a steep learning curve. Several other surgical procedures have been employed for the treatment of ODP-M, including inner retinal fenestration, autologous fibrin use, and glial tissue removal [49-53]. Recently, Theodossiadis et al. [46] summarized the latest treatments for ODP-M, mainly focusing on covering and filling the ODP with an ILM inverted flap. This procedure is successful if the subretinal fluid originates from the vitreous cavity. On the other hand, filling the ODP with a rolled ILM-flap, autologous scleral tissue, or human amniotic membrane can provide favorable anatomical results. It appears that both these techniques may lead to promising outcomes when combined with PPV. However, there are only a limited number of available reports regarding ODP covering and filling techniques [46]. Therefore, vitreoretinal surgeons should consider several parameters and possible complications when using this technique in the treatment of ODP-M.

Special considerations in the pediatric population

The clinical course of ODP-M in children seems to differ from that of the typical form of the disease in adults. Ophthalmologists must monitor and record any changes in the VA of children, because they are at risk of amblyopia and subsequently lifelong visual disability. This condition may also indirectly affect children's education and school performance [54]. Early diagnosis of ODP-M and prompt, appropriate management are crucial, particularly in patients of amblyogenic age.

A retrospective study by Rii et al. [25] evaluated fundoscopic and OCT findings in children and adults with ODP-M. The results of their study showed that ODP-M in childhood occurred most commonly after blunt ocular trauma in eyes with strong vitreous adhesion to the margin of the optic disc. Adults presented with more varied symptoms, including visual impairment, metamorphopsia, micropsia, and myodesopsia, whereas visual impairment was the only symptom in children. This may be because children are not able to describe visual impairment as accurately as adults [25].

Several studies have reported that PPV combined with ILM peeling (to relieve vitreoretinal traction), with or without laser photocoagulation, yields promising outcomes in children [17, 53-62]. Laser photocoagulation of the temporal margin of the optic disc aims to prevent further vitreous fluid from entering the subretinal/intraretinal space [57].

Ozdek and Ozdemir described the use of autologous fibrin for the treatment of persistent ODP-M. The anatomical success of their approach was attributed to the presumed autologous fibrin-enhanced local tissue response that prevented fluid passage from the subarachnoid space to the subretinal space [51]. An older study by Theodosiadis et al. [23] described cyst formation as a phenomenon that accompanied ODP-associated macular detachment in five cases in their series, of which two were children. Their study showed that the macular scleral buckle procedure was an effective approach, as cyst formation gradually decreased and finally disappeared after the surgery [23].

However, the fact that ODP-M may spontaneously resolve in children cannot be ignored [19, 20, 63-65]. Benatti et al. [63] reported a characteristic case of a 12-year-old child with ODP-M that spontaneously resolved after a 6-year follow-up, suggesting that functional and morphological evaluation over time could be critical for determining the optimal management of ODP-M, particularly in children for whom the conservative approach appears to be a reasonable alternative to surgery. A single-center study by Bloch et al. [66] investigated the natural history of ODP-M in a cohort of 87 patients and found that many patients maintained good long-term visual acuity with gradual improvement of the condition, without surgical intervention. Their findings suggested that there may be evidence supporting a delay in surgical intervention until visual deterioration is recorded, due to the potential stability or spontaneous resolution of subretinal fluid, the high rate of reoperation, and the long-term positive outcomes of deferred intervention (Table 2) [66].

The strengths of our review include that we have summarized the clinical and surgical experience of the collaborating centers in combination with our previous research activity in ODP-M. The main limitations are related to the relatively small number of studies in the pediatric population. Further studies with emphasis on the structure-function relationships of ODP and other congenital optic disc anomalies will expand our knowledge and improve our clinical practice related to diagnosis, management, and prognosis of this rare condition. Most importantly, it is highly recommended that the risks and benefits of all available therapeutic options be thoroughly discussed with the family to ensure that the best approach will be offered. There is an obvious need for prospective studies on this rare condition to explore the validity of further prognostic factors and the response to various therapeutic approaches.

CONCLUSIONS

Although ODP-M typically affects adults during the third or fourth decade of life, it can also occur during childhood. ODP-M constitutes an underdiagnosed clinical entity that can mimic other causes of subretinal fluid. This condition may also indirectly affect children's education and school performance. Careful clinical examination and detailed imaging analysis are the cornerstones of establishing a diagnosis and avoiding misinterpretation. Prompt, appropriate management is crucial, particularly in patients of amblyogenic age. Several studies have reported that PPV combined with ILM peeling (to relieve vitreoretinal traction), with or without laser photocoagulation, yields promising outcomes in children. Spontaneous resolution of the subretinal fluid with a subsequent improvement in VA has been reported, but the majority of cases have a poor visual prognosis if left untreated. Awareness and early identification of ODP-M are important for improving disease management and, consequently, the final visual outcome. Defining specific prognostic factors may contribute to the management of ODP-M. Decision-making is more complicated and demanding in the pediatric population. Ideally, more prospective or randomized controlled trials are necessary to evaluate the diagnostic and therapeutic approaches to pediatric ODP-M.

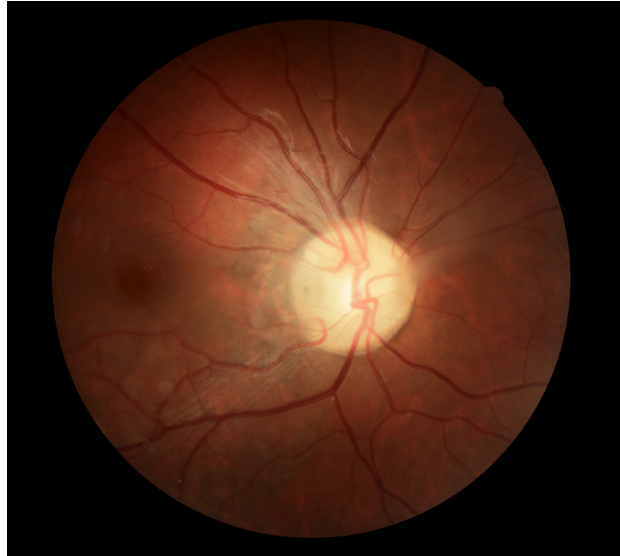

Figure 1. Fundus photograph of a 16-year-old female with a unilateral (right eye) optic disc pit, presenting as a grayish oval excavation near the margin of the optic disc (CR-2 AF Digital Non-Mydriatic Retinal Camera, Canon USA, Inc., Melville, NY, USA).

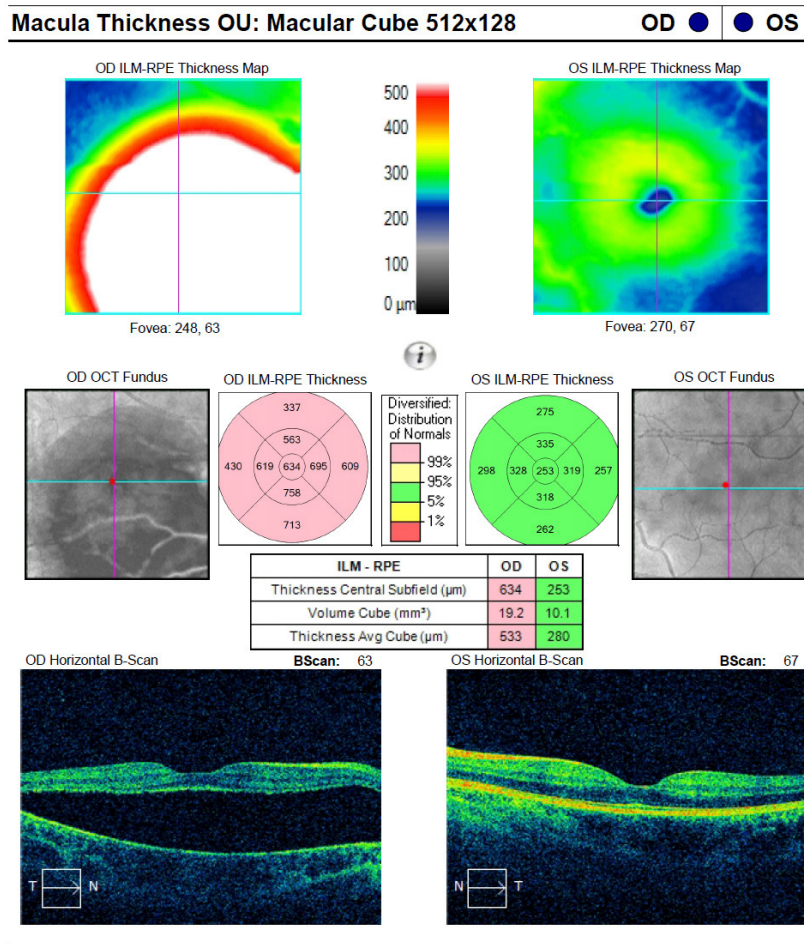


Figure 2. Bilateral optical coherence tomography (OCT) of the same patient as in Figure 1. OCT and macula thickness analysis show optic disc pit maculopathy (ODP-M) with subretinal fluid in the right eye in comparison with the left eye (the Cirrus[®] HD-OCT Model 400 [Carl Zeiss Meditech, Dublin, CA]).

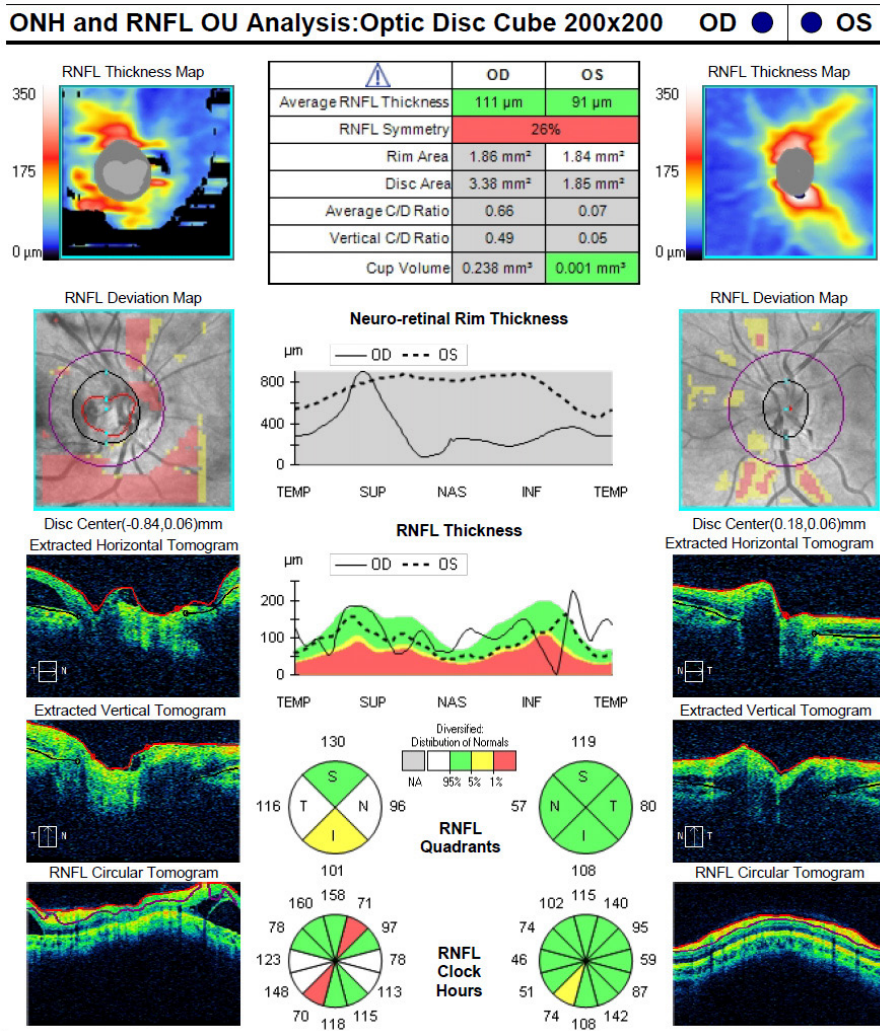


Figure 3. Optic nerve head and retinal nerve fiber layer (RNFL) analysis of the same patient as in Figure 1, showing the RNFL asymmetry between the eyes and the defects of the affected (right) eye that are compatible with an optic disc pit (the Cirrus™ HD-OCT Model 400 [Carl Zeiss Meditech, Dublin, CA]).

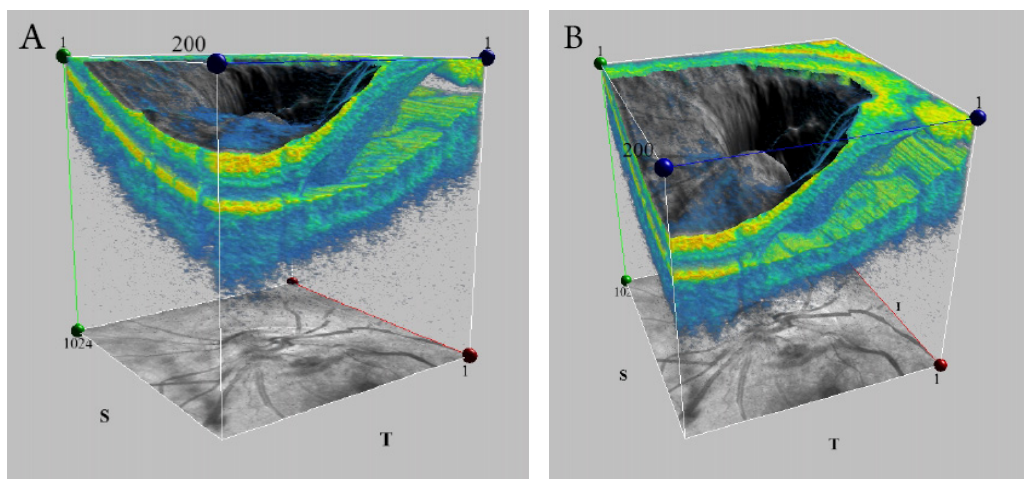


Figure 4 (A, B). Three-dimensional (3D) visualization of the optic disc of the right eye of the same patient as in Figure 1, showing the optic disc pit (ODP). 3D images may be very useful to define the features of ODP in detail and can probably shed more light on the pathogenesis of ODP maculopathy (the Cirrus™ HD-OCT Model 400 [Carl Zeiss Meditech, Dublin, CA]).

ETHICAL DECLARATIONS

Ethical approval: This is a review study and no ethical approval was needed.

Conflicts of interests: None.

FUNDING

None.

ACKNOWLEDGEMENTS

None.

REFERENCES

- Kalogeropoulos D, Ch'ng SW, Lee R, Elaraoud I, Purohit M, Felicida V, et al. Optic Disc Pit Maculopathy: A Review. *Asia Pac J Ophthalmol (Phila)*. 2019;8(3):247-55. doi: 10.22608/APO.2018473 pmid: 31179667
- Javitt JC, Spaeth GL, Katz LJ, Poryzees E, Addiego R. Acquired pits of the optic nerve. Increased prevalence in patients with low-tension glaucoma. *Ophthalmology*. 1990;97(8):1038-43; discussion 43-4. doi: 10.1016/s0161-6420(90)32466-1 pmid: 2402415
- Ohno-Matsui K, Akiba M, Moriyama M, Shimada N, Ishibashi T, Tokoro T, et al. Acquired optic nerve and peripapillary pits in pathologic myopia. *Ophthalmology*. 2012;119(8):1685-92. doi: 10.1016/j.ophtha.2012.01.047 pmid: 22494632
- Radius RL, Maumenee AE, Green WR. Pit-like changes of the optic nerve head in open-angle glaucoma. *Br J Ophthalmol*. 1978;62(6):389-93. doi: 10.1136/bjo.62.6.389 pmid: 666988
- Healey PR, Mitchell P. The prevalence of optic disc pits and their relationship to glaucoma. *J Glaucoma*. 2008;17(1):11-4. doi: 10.1097/IJG.0b013e318133fc34 pmid: 18303377
- Wang Y, Xu L, Jonas JB. Prevalence of congenital optic disc pits in adult Chinese: The Beijing Eye Study. *Eur J Ophthalmol*. 2006;16(6):863-4. doi: 10.1177/112067210601600613 pmid: 17191194
- Radosova V, Krejcirova I, Autrata R, Zajdlikova B. Bilateral Optic Disc Pit with Maculopathy - the Case Report. *Cesk Slov Oftalmol*. 2019;75(2):86-90. doi: 10.31348/2019/2/5 pmid: 31537077
- Rossi S, De Rosa G, D'Alterio FM, Orrico A, Banfi S, Testa F, et al. Intrafamilial heterogeneity of congenital optic disc pit maculopathy. *Ophthalmic Genet*. 2017;38(3):267-72. doi: 10.1080/13816810.2016.1188120 pmid: 27268460
- Stefko ST, Campochiaro P, Wang P, Li Y, Zhu D, Traboulsi EI. Dominant inheritance of optic pits. *Am J Ophthalmol*. 1997;124(1):112-3. doi: 10.1016/s0002-9394(14)71656-3 pmid: 9222245
- Slusher MM, Weaver RG, Jr., Greven CM, Mundorf TK, Cashwell LF. The spectrum of cavitory optic disc anomalies in a family. *Ophthalmology*. 1989;96(3):342-7. doi: 10.1016/s0161-6420(89)32886-7 pmid: 2710526
- Kranenburg EW. Crater-like holes in the optic disc and central serous retinopathy. *Arch Ophthalmol*. 1960;64:912-24. doi: 10.1001/archophth.1960.01840010914013 pmid: 13753957
- Sugar HS. An explanation for the acquired macular pathology associated with congenital pits of the optic disc. *Am J Ophthalmol*. 1964 May;57(833-5). pmid: 14167198
- Sugar HS. Congenital pits in the optic disc and their equivalents (congenital colobomas and colobomalike excavations) associated with submacular fluid. *Am J Ophthalmol*. 1967 Feb;63(2):298-307. doi: 10.1016/0002-9394(67)91553-X pmid: 4959901
- Gordon R, Chatfield RK. Pits in the optic disc associated with macular degeneration. *Br J Ophthalmol*. 1969;53(7):481-9. doi: 10.1136/bjo.53.7.481 pmid: 5804034
- Brodsky MC. Congenital optic disk anomalies. *Surv Ophthalmology*. 1994;39(89e112). doi: 10.1016/0039-6257(94)90155-4 pmid: 7801227
- Kalogeropoulos D, Ch'ng SW, Lee R, Elaraoud I, Felicida V, Purohit M, et al. Optic Disc Pit Maculopathy - Case Series, Clinical Approach, and Management. *Middle East Afr J Ophthalmol*. 2020;27(1):34-9. doi: 10.4103/meajo.MEAJO_181_19 pmid: 32549722
- Georgalas I, Kouri A, Ladas I, Gotzaris E. Optic disc pit maculopathy treated with vitrectomy, internal limiting membrane peeling, and air in a 5-year-old boy. *Can J Ophthalmol*. 2010;45(2):189-91. doi: 10.3129/i09-215 pmid: 20379320
- Iftikhar M, Shah SMA, Goldberg MF. A Case of Optic Disc Pit Maculopathy Observed without Intervention for 6 Years. *Ophthalmol Retina*. 2019;3(2):195-7. doi: 10.1016/j.oret.2018.09.019 pmid: 31014772
- Akca Bayar S, Sarigul Sezenoz A, Yaman Pinarci E, Yilmaz G. Spontaneous Regression of Optic Disc Pit Maculopathy in a Six-Year-Old Child. *Turk J Ophthalmol*. 2017;47(1):56-8. doi: 10.4274/tjo.57614 pmid: 28182177
- Yuen CH, Kaye SB. Spontaneous resolution of serous maculopathy associated with optic disc pit in a child: a case report. *J AAPOS*. 2002;6(5):330-1. doi: 10.1067/mpa.2002.127921 pmid: 12381994
- Uzel MM, Karacorlu M. Optic disc pits and optic disk pit maculopathy: A review. *Surv Ophthalmol*. 2019;64(5):595-607. doi: 10.1016/j.survophthal.2019.02.006 pmid: 30797884
- Theodossiadis G. Evolution of congenital pit of the optic disk with macular detachment in photocoagulated and nonphotocoagulated eyes. *Am J Ophthalmol*. 1977;84(5):620-31. doi: 10.1016/0002-9394(77)90375-0 pmid: 930990
- Theodossiadis GP, Theodossiadis PG, Ladas ID, Zafirakis PK, Kollia AC, Koutsandrea C, et al. Cyst formation in optic disc pit maculopathy. *Doc Ophthalmol*. 1999;97(3-4):329-35. doi: 10.1023/a:1002194324791 pmid: 10896347
- Steel DHW, Suleman J, Murphy DC, Song A, Dodds S, Rees J. Optic Disc Pit Maculopathy: A Two-Year Nationwide Prospective Population-based Study. *Ophthalmology*. 2018;125(11):1757-64. doi: 10.1016/j.ophtha.2018.05.009 pmid: 29887331
- Rii T, Hirakata A, Inoue M. Comparative findings in childhood-onset versus adult-onset optic disc pit maculopathy. *Acta Ophthalmol*. 2013;91(5):429-33. doi: 10.1111/j.1755-3768.2012.02429.x pmid: 22551388
- Lincoff H, Yannuzzi L, Singerman L, Kreissig I, Fisher Y. Improvement in visual function after displacement of the retinal elevations emanating from optic pits. *Arch Ophthalmol*. 1993;111(8):1071-9. doi: 10.1001/archophth.1993.01090080067020 pmid: 8352690
- Theodossiadis GP, Chatziralli IP, Theodossiadis PG. Macular buckling in optic disc pit maculopathy in association with the origin of macular elevation: 13-year mean postoperative results. *Eur J Ophthalmol*. 2015;25(3):241-8. doi: 10.5301/ejo.5000553 pmid: 25588593
- Theodossiadis GP. Treatment of maculopathy associated with optic disk pit by sponge explant. *Am J Ophthalmol*. 1996;121(6):630-7. doi: 10.1016/s0002-9394(14)70628-2 pmid: 8644805

29. Theodosiadis GP, Theodosiadis PG. The macular buckling technique in the treatment of optic disc pit maculopathy. *Semin Ophthalmol.* 2000;15(2):108-15. doi: [10.3109/08820530009040001](https://doi.org/10.3109/08820530009040001) pmid: 11309743
30. Theodosiadis GP, Theodosiadis PG. Optical coherence tomography in optic disc pit maculopathy treated by the macular buckling procedure. *Am J Ophthalmol.* 2001;132(2):184-90. doi: [10.1016/s0002-9394\(01\)00997-7](https://doi.org/10.1016/s0002-9394(01)00997-7) pmid: 11476677
31. Brockhurst RJ. Optic pits and posterior retinal detachment. *Trans Am Ophthalmol Soc.* 1975;73:264-91. pmid: 1246808
32. Theodosiadis GP, Panopoulos M, Kollia AK, Georgopoulos G. Long-term study of patients with congenital pit of the optic nerve and persistent macular detachment. *Acta Ophthalmol (Copenh).* 1992;70(4):495-505. doi: [10.1111/j.1755-3768.1992.tb02120.x](https://doi.org/10.1111/j.1755-3768.1992.tb02120.x) pmid: 1414295
33. Brown GC, Shields JA, Goldberg RE. Congenital pits of the optic nerve head. II. Clinical studies in humans. *Ophthalmology.* 1980;87(1):51-65. doi: [10.1016/s0161-6420\(80\)35278-0](https://doi.org/10.1016/s0161-6420(80)35278-0) pmid: 7375086
34. Chatziralli I, Theodosiadis P, Theodosiadis GP. Optic disc pit maculopathy: current management strategies. *Clin Ophthalmol.* 2018;12:1417-22. doi: [10.2147/OPTH.S153711](https://doi.org/10.2147/OPTH.S153711) pmid: 30127591
35. Asensio Sanchez VM, Corral Azor A, Bartolome Aragon A, De Paz Garcia M. [Renal-coloboma syndrome]. *Arch Soc Esp Oftalmol.* 2002;77(11):635-8. pmid: 12410411
36. Caprioli J, Lesser RL. Basal encephalocele and morning glory syndrome. *Br J Ophthalmol.* 1983;67(6):349-51. doi: [10.1136/bjo.67.6.349](https://doi.org/10.1136/bjo.67.6.349) pmid: 6849854
37. Fea A, Grosso A, Rabbione M, Grignolo F. Alagille syndrome and optic pit. *Graefes Arch Clin Exp Ophthalmol.* 2007;245(2):315-7. doi: [10.1007/s00417-006-0340-4](https://doi.org/10.1007/s00417-006-0340-4) pmid: 16673137
38. Kim BJ, Fulton AB. The genetics and ocular findings of Alagille syndrome. *Semin Ophthalmol.* 2007;22(4):205-10. doi: [10.1080/08820530701745108](https://doi.org/10.1080/08820530701745108) pmid: 18097983
39. Pollock JA, Newton TH, Hoyt WF. Transsphenoidal and transthemoidal encephaloceles. A review of clinical and roentgen features in 8 cases. *Radiology.* 1968;90(3):442-53. doi: [10.1148/90.3.442](https://doi.org/10.1148/90.3.442) pmid: 4966739
40. Jain N, Johnson MW. Pathogenesis and treatment of maculopathy associated with cavitory optic disc anomalies. *Am J Ophthalmol.* 2014;158(3):423-35. doi: [10.1016/j.ajo.2014.06.001](https://doi.org/10.1016/j.ajo.2014.06.001) pmid: 24932988
41. Georgalas I, Ladas I, Georgopoulos G, Petrou P. Optic disc pit: a review. *Graefes Arch Clin Exp Ophthalmol.* 2011;249(8):1113-22. doi: [10.1007/s00417-011-1698-5](https://doi.org/10.1007/s00417-011-1698-5) pmid: 21638030
42. Lincoff H, Lopez R, Kreissig J, Yannuzzi L, Cox M, Burton T. Retinoschisis associated with optic nerve pits. *Retina.* 2012;32 Suppl 1:61-7. doi: [10.1097/iae.0b013e31823f9abb](https://doi.org/10.1097/iae.0b013e31823f9abb) pmid: 22451950
43. Krivoy D, Gentile R, Liebmann JM, Stegman Z, Rosen R, Walsh JB, et al. Imaging congenital optic disc pits and associated maculopathy using optical coherence tomography. *Arch Ophthalmol.* 1996;114(2):165-70. doi: [10.1001/archoph.1996.01100130159008](https://doi.org/10.1001/archoph.1996.01100130159008) pmid: 8573019
44. Rutledge BK, Puliafito CA, Duker JS, Hee MR, Cox MS. Optical coherence tomography of macular lesions associated with optic nerve head pits. *Ophthalmology.* 1996;103(7):1047-53. doi: [10.1016/s0161-6420\(96\)30568-x](https://doi.org/10.1016/s0161-6420(96)30568-x) pmid: 8684793
45. Roy R, Waanbah AD, Mathur G, Raman R, Sharma T. Optical coherence tomography characteristics in eyes with optic pit maculopathy. *Retina.* 2013;33(4):771-5. doi: [10.1097/IAE.0b013e31826f5234](https://doi.org/10.1097/IAE.0b013e31826f5234) pmid: 23423154
46. Theodosiadis G, Theodosiadis P, Chatziralli I. Thoughts and Challenges for the Current Treatment of Optic Disc Pit Maculopathy. *Semin Ophthalmol.* 2020;35(4):232-6. doi: [10.1080/08820538.2020.1809684](https://doi.org/10.1080/08820538.2020.1809684) pmid: 32809892
47. Jeng-Miller KW, Cestari DM, Gaier ED. Congenital anomalies of the optic disc: insights from optical coherence tomography imaging. *Curr Opin Ophthalmol.* 2017;28(6):579-86. doi: [10.1097/ICU.0000000000000425](https://doi.org/10.1097/ICU.0000000000000425) pmid: 28817389
48. Steel DH, Williamson TH, Laidlaw DA, Sharma P, Matthews C, Rees J, et al. Extent and Location of Intraretinal and Subretinal Fluid as Prognostic Factors for the Outcome of Patients with Optic Disc Pit Maculopathy. *Retina.* 2016;36(1):110-8. doi: [10.1097/IAE.0000000000000658](https://doi.org/10.1097/IAE.0000000000000658) pmid: 26166800
49. Ooto S, Mittra RA, Ridley ME, Spaide RF. Vitrectomy with inner retinal fenestration for optic disc pit maculopathy. *Ophthalmology.* 2014;121(9):1727-33. doi: [10.1016/j.ophtha.2014.04.006](https://doi.org/10.1016/j.ophtha.2014.04.006) pmid: 24837239
50. Rosenthal G, Bartz-Schmidt KU, Walter P, Heimann K. Autologous platelet treatment for optic disc pit associated with persistent macular detachment. *Graefes Arch Clin Exp Ophthalmol.* 1998;236(2):151-3. doi: [10.1007/s004170050056](https://doi.org/10.1007/s004170050056) pmid: 9498127
51. Ozdek S, Ozdemir HB. A New Technique with Autologous Fibrin for the Treatment of Persistent Optic Pit Maculopathy. *Retin Cases Brief Rep.* 2017;11(1):75-8. doi: [10.1097/ICB.0000000000000293](https://doi.org/10.1097/ICB.0000000000000293) pmid: 26982208
52. Todorich B, Sharma S, Vajzovic L. Successful Repair of Recurrent Optic Disc Pit Maculopathy with Autologous Platelet Rich Plasma: Report of a Surgical Technique. *Retin Cases Brief Rep.* 2017;11(1):15-7. doi: [10.1097/ICB.0000000000000276](https://doi.org/10.1097/ICB.0000000000000276) pmid: 26829447
53. Inoue M, Shinoda K, Ishida S. Vitrectomy combined with glial tissue removal at the optic pit in a patient with optic disc pit maculopathy: a case report. *J Med Case Rep.* 2008;2:103. doi: [10.1186/1752-1947-2-103](https://doi.org/10.1186/1752-1947-2-103) pmid: 18394198
54. Kalogeropoulos D, Kalogeropoulos C, Moschos MM, Sung V. The Management of Uveitic Glaucoma in Children. *Turk J Ophthalmol.* 2019;49(5):283-93. doi: [10.4274/tjo.galenos.2019.36589](https://doi.org/10.4274/tjo.galenos.2019.36589) pmid: 31650812
55. Theodosiadis PG, Grigoropoulos VG, Emfietzoglou J, Theodosiadis GP. Vitreous findings in optic disc pit maculopathy based on optical coherence tomography. *Graefes Arch Clin Exp Ophthalmol.* 2007;245(9):1311-8. doi: [10.1007/s00417-007-0534-4](https://doi.org/10.1007/s00417-007-0534-4) pmid: 17285337
56. Shukla D, Kalliath J, Tandon M, Vijayakumar B. Vitrectomy for optic disc pit with macular schisis and outer retinal dehiscence. *Retina.* 2012;32(7):1337-42. doi: [10.1097/IAE.0b013e318235d8fc](https://doi.org/10.1097/IAE.0b013e318235d8fc) pmid: 22481474
57. Rizzo S, Belting C, Genovesi-Ebert F, Di Bartolo E, Cresti F, Cinelli L, et al. Optic disc pit maculopathy: the value of small-gauge vitrectomy, peeling, laser treatment, and gas tamponade. *Eur J Ophthalmol.* 2012;22(4):620-5. doi: [10.5301/ejo.5000083](https://doi.org/10.5301/ejo.5000083) pmid: 22081669
58. Maertz J, Mohler KJ, Kolb JP, Kein T, Neubauer A, Kampik A, et al. Intrapapillary proliferation in optic disc pits: Clinical findings and time-related changes. *Retina.* 2017;37(5):906-14. doi: [10.1097/IAE.0000000000001260](https://doi.org/10.1097/IAE.0000000000001260) pmid: 27617535
59. Yokoi T, Nakayama Y, Nishina S, Azuma N. Abnormal traction of the vitreous detected by swept-source optical coherence tomography is related to the maculopathy associated with optic disc pits. *Graefes Arch Clin Exp Ophthalmol.* 2016;254(4):675-82. doi: [10.1007/s00417-015-3114-z](https://doi.org/10.1007/s00417-015-3114-z) pmid: 26245337
60. Rayat JS, Rudnisky CJ, Waite C, Huang P, Sheidow TG, Kherani A, et al. Long-Term Outcomes for Optic Disc Pit Maculopathy after Vitrectomy. *Retina.* 2015;35(10):2011-7. doi: [10.1097/IAE.0000000000000576](https://doi.org/10.1097/IAE.0000000000000576) pmid: 25923958
61. Lei L, Li T, Ding X, Ma W, Zhu X, Atik A, et al. Gas tamponade combined with laser photocoagulation therapy for congenital optic disc pit maculopathy. *Eye (Lond).* 2015;29(1):106-14. doi: [10.1038/eye.2014.245](https://doi.org/10.1038/eye.2014.245) pmid: 25323852
62. Hiraoka T, Inoue M, Ninomiya Y, Hirakata A. Infrared and fundus autofluorescence imaging in eyes with optic disc pit maculopathy. *Clin Exp Ophthalmol.* 2010;38(7):669-77. doi: [10.1111/j.1442-9071.2010.02311.x](https://doi.org/10.1111/j.1442-9071.2010.02311.x) pmid: 20456431
63. Benatti E, Garoli E, Viola F. Spontaneous Resolution of Optic Disc Pit Maculopathy in a Child after a Six-Year Follow-Up. *Retin Cases Brief Rep.* 2021;15(4):453-6. doi: [10.1097/ICB.0000000000000815](https://doi.org/10.1097/ICB.0000000000000815) pmid: 30086106

64. Ozkaya A, Alkin Z, Taylan AT, Demirok A. Ocular imaging findings of bilateral optic disc pit in a child. *Nepal J Ophthalmol*. 2013;5(2):258-61. doi: [10.3126/nepjoph.v5i2.8739](https://doi.org/10.3126/nepjoph.v5i2.8739) pmid: [24172565](https://pubmed.ncbi.nlm.nih.gov/24172565/)
65. Brodsky MC. Congenital optic pit with serous maculopathy in childhood. *J AAPOS*. 2003;7(2):150; author reply doi: [10.1016/s1091-8531\(03\)00008-9](https://doi.org/10.1016/s1091-8531(03)00008-9) pmid: [12756987](https://pubmed.ncbi.nlm.nih.gov/12756987/)
66. Bloch E, Georgiadis O, Lukic M, da Cruz L. Optic Disc Pit Maculopathy: New Perspectives on the Natural History. *Am J Ophthalmol*. 2019;207:159-69. doi: [10.1016/j.ajo.2019.05.010](https://doi.org/10.1016/j.ajo.2019.05.010) pmid: [31095956](https://pubmed.ncbi.nlm.nih.gov/31095956/)
67. Kováčová M, Meliška M, Kalvodová B. OCT Findings and Long-term Follow-up Results of Vitrectomy in Patients with Optic Disc Pit and Associated Maculopathy. *Cesk Slov Oftalmol*. 2018 Spring;73(5-6):171-7. English. pmid: [30541296](https://pubmed.ncbi.nlm.nih.gov/30541296/)
68. Mete A, Turkcuoglu P, Kimyon S, Gungor K. The results of 25-gauge vitreoretinal surgery for optic disc pit-associated maculopathy: a report of three cases and mini-review of the literature. *Int Ophthalmol*. 2017;37(4):1057-63. doi: [10.1007/s10792-016-0336-y](https://doi.org/10.1007/s10792-016-0336-y) pmid: [27614461](https://pubmed.ncbi.nlm.nih.gov/27614461/)
69. Akiyama H, Shimoda Y, Fukuchi M, Kashima T, Mayuzumi H, Shinohara Y, et al. Intravitreal gas injection without vitrectomy for macular detachment associated with an optic disk pit. *Retina*. 2014;34(2):222-7. doi: [10.1097/IAE.0b013e3182993d93](https://doi.org/10.1097/IAE.0b013e3182993d93) pmid: [23873162](https://pubmed.ncbi.nlm.nih.gov/23873162/)
70. Sanghi G, Padhi TR, Warkad VU, Vazirani J, Gupta V, Dogra MR, et al. Optical coherence tomography findings and retinal changes after vitrectomy for optic disc pit maculopathy. *Indian J Ophthalmol*. 2014;62(3):287-90. doi: [10.4103/0301-4738.111191](https://doi.org/10.4103/0301-4738.111191) pmid: [23619493](https://pubmed.ncbi.nlm.nih.gov/23619493/)
71. Marticorena J, Gomez-Ulla F, Romano MR, Fernandez M. Dye-guided retinal laser and internal drainage for optic pit maculopathy. *Graefes Arch Clin Exp Ophthalmol*. 2013;251(1):381-2. doi: [10.1007/s00417-011-1828-0](https://doi.org/10.1007/s00417-011-1828-0) pmid: [21964822](https://pubmed.ncbi.nlm.nih.gov/21964822/)
72. Hirakata A, Inoue M, Hiraoka T, McCuen BW, 2nd. Vitrectomy without laser treatment or gas tamponade for macular detachment associated with an optic disc pit. *Ophthalmology*. 2012;119(4):810-8. doi: [10.1016/j.ophtha.2011.09.026](https://doi.org/10.1016/j.ophtha.2011.09.026) pmid: [22218142](https://pubmed.ncbi.nlm.nih.gov/22218142/)
73. Imamura Y, Zweifel SA, Fujiwara T, Freund KB, Spaide RF. High-resolution optical coherence tomography findings in optic pit maculopathy. *Retina*. 2010;30(7):1104-12. doi: [10.1097/IAE.0b013e3181d87ecb](https://doi.org/10.1097/IAE.0b013e3181d87ecb) pmid: [20523264](https://pubmed.ncbi.nlm.nih.gov/20523264/)
74. Chiu YT, Chen HY, Tsai YY, Lin JM, Chiang CC. Stratus optical coherence tomography for evaluating optic disc pits associated with maculopathy before and after vitrectomy: two case reports. *Kaohsiung J Med Sci*. 2006;22(5):229-34. doi: [10.1016/S1607-551X\(09\)70241-4](https://doi.org/10.1016/S1607-551X(09)70241-4) pmid: [16793558](https://pubmed.ncbi.nlm.nih.gov/16793558/)
75. Spaide RF, Fisher Y, Ober M, Stoller G. Surgical hypothesis: inner retinal fenestration as a treatment for optic disc pit maculopathy. *Retina*. 2006;26(1):89-91. doi: [10.1097/00006982-200601000-00014](https://doi.org/10.1097/00006982-200601000-00014) pmid: [16395144](https://pubmed.ncbi.nlm.nih.gov/16395144/)
76. Ishikawa K, Terasaki H, Mori M, Sugita K, Miyake Y. Optical coherence tomography before and after vitrectomy with internal limiting membrane removal in a child with optic disc pit maculopathy. *Jpn J Ophthalmol*. 2005;49(5):411-3. doi: [10.1007/s10384-004-0225-1](https://doi.org/10.1007/s10384-004-0225-1) pmid: [16187043](https://pubmed.ncbi.nlm.nih.gov/16187043/)
77. Hirakata A, Hida T, Wakabayashi T, Fukuda M. Unusual posterior hyaloid strand in a young child with optic disc pit maculopathy: intraoperative and histopathological findings. *Jpn J Ophthalmol*. 2005;49(3):264-6. doi: [10.1007/s10384-004-0185-5](https://doi.org/10.1007/s10384-004-0185-5) pmid: [15944837](https://pubmed.ncbi.nlm.nih.gov/15944837/)
78. Bakri SJ, Beer PM. Vitreoretinal surgery for optic pit associated serous macular detachment: a discussion of two cases. *Int Ophthalmol*. 2004;25(3):143-6. doi: [10.1007/s10792-004-5197-0](https://doi.org/10.1007/s10792-004-5197-0) pmid: [15847312](https://pubmed.ncbi.nlm.nih.gov/15847312/)
79. Meyer CH, Rodrigues EB. Optic disc pit maculopathy after blunt ocular trauma. *Eur J Ophthalmol*. 2004;14(1):71-3. doi: [10.1177/112067210401400114](https://doi.org/10.1177/112067210401400114) pmid: [15005591](https://pubmed.ncbi.nlm.nih.gov/15005591/)